

*Archaeological investigations at the
last Spanish Colonial mission
established on the Texas frontier:*

Nuestra Señora del Refugio (41RF1),
Refugio County, Texas

Volume II
Osteological Analyses

by

Lee Meadows Jantz, Richard L. Jantz, Nicholas P. Herrmann,
Corey S. Sparks, Katherine E. Weisensee, and Derinna V. Kopp

Contributions by

Roy Clark

Rebecca R. Kardash

Douglas W. Owsley

Appendix by

Lynette Norr

Texas Department of Transportation
Environmental Affairs Division
Archeological Studies Program, Report No. 39

Center for Archaeological Research
The University of Texas at San Antonio
Archaeological Survey Report, No. 315

2002

*Archaeological investigations at the
last Spanish Colonial mission
established on the Texas frontier:*

Nuestra Señora del Refugio (41RF1),
Refugio County, Texas

Volume II
Osteological Analyses

by
Lee Meadows Jantz, Richard L. Jantz, Nicholas P. Herrmann,
Corey S. Sparks, Katherine E. Weisensee, and Derinna V. Kopp

Contributions by
Roy Clark Rebecca R. Kardash Douglas W. Owsley

Appendix by
Lynette Norr


Texas Antiquities Committee Permit No. 2025

Raymond P. Mauldin and Cynthia L. Tennis
Principal Investigators

and

C. Britt Bousman and Robert J. Hard
Former Principal Investigators

Prepared for:
Texas Department of Transportation
Environmental Affairs Division
Archeological Studies Program, Report No. 39



2002

Prepared by:
Center for Archaeological Research
The University of Texas at San Antonio
Archaeological Survey Report, No. 315



Archaeological Investigations at the
last Spanish Colonial mission
established on the Texas frontier:

Nuestra Señora del Refugio (41RF1), Refugio County, Texas

Copyright ©2002

Texas Department of Transportation (TxDOT) and Center for Archaeological Research,
The University of Texas at San Antonio (CAR–UTSA)

All rights reserved

TxDOT and CAR–UTSA jointly own all rights, title, and interest in and to all data and other information developed for this project under Contract(s) 57-0XXA3003, 57-8XXA3008, and 57-0XXPF001. Brief passages from this publication may be reproduced without permission provided that credit is given to TxDOT and CAR–UTSA. Permission to reprint an entire chapter, section, figures or tables must be obtained in advance from the Supervisor of the Archeological Studies Program, Environmental Affairs Division, Texas Department of Transportation, 125 East 11th Street, Austin, 78701. Copies of this publication have been deposited with the Texas State Library in compliance with the State Depository requirements.

Printed by Kwik Kopy Printing on Main, San Antonio, Texas
2002

jointly published by

Texas Department of Transportation
Environmental Affairs Division
Archeological Studies Program
Nancy A. Kenmotsu, Ph.D., Supervisor

Archeological Studies Program, Report No. 39
A. McGraw, Series Editor

and

Center for Archaeological Research
The University of Texas at San Antonio
Archeological Survey Report, No. 315

Printed on acid-free, 60 lb. paper

ISBN: 1-930788-18-5

Mission Nuestra Señora del Refugio

Volume Contents

Volume I:

Archaeological Investigations

Chapter 1: Introduction

Chapter 2: Environment

Chapter 3: Mission History

Chapter 4: The People of Mission Refugio

Chapter 5: Post-1830 History

Chapter 6: Previous Archaeology

Chapter 7: Methodology

Chapter 8: Findings: Trash and Midden; Architectural; Burial; and Skeletal Biology

Chapter 9: Artifacts: Non-Native Ceramics; Other Historic; Native Ceramics; Lithics; and Faunal I & II

Chapter 10: Summary and Conclusion

Volume I - CD:

Archaeological Investigations Appendices

Appendix A: Translations: 1796 Inventory; 1792–1810 Supply Inventories; and 1820 Inventory

Appendix B: Records: Baptismal; Burial; and Census

Appendix C: Artifact Data

Appendix D: Oxidizable Carbon Ratio Data

Appendix E: Botanical Remains Data

Appendix F: Pollen and Phytoliths Analysis

Appendix G: Petrographic Ceramic Analysis

Appendix H: Instrumental Neutron Activation Analysis–Non-Native Ceramics

Appendix I: Burial Artifact Data

Appendix J: Paste and Temper Analysis–Native Ceramics

Appendix K: Rim Sherds and Decorated Sherds–Native Ceramics

Appendix L: Instrumental Neutron Activation Analysis–Native Ceramics

Appendix M: Faunal Provenience and Measurements

Appendix N: Archaeological Form Samples

Volume II:

Osteological Analyses

Section A: Introduction

Section B: Preparation of Sample and Methods for Analysis

Section C: Individual Burials

Section D: Bone Inventory

Section E: Demography

Section F: Bone Pathology

Section G: Dental Pathology

Section H: Dental Metrics and Morphology

Section I: Metric Analysis of Postcranial Remains

Section J: Metric Analysis of Cranial Morphology

Section K: Dietary Variation, Ethnicity and Mobility

Section L: Summary and Conclusion

Volume II:

Appendices

Appendix IIA: Burial Descriptions

Appendix IIB: Inventory and Coding Forms

Appendix IIC: Individuals with Enthesophytosis

Appendix IID: Individuals with Antemortem Fractures

Appendix IIE: Isotopic Analysis

Table of Contents:

Mission Nuestra Señora del Refugio

Volume II

Osteological Analyses

Figures	iv
Tables	vii
Plates	x
Section A: Introduction	
Preservation and Analysis	1
Comparison Samples	2
Research Strategy	2
Summary	2
Section B: Preparation of Sample and Methods for Analysis	
Inventory of the Skeletal Sample	3
Determination of Sex, Age, and Ancestry	5
Dental Inventory	6
Pathology	7
Section C: Individual Burials	
Individual Burials	9
Section D: Bone Inventory	
Bone Inventory	17
Section E: Demography	
Methods	33
Sample Descriptions	34
Mortality Models and Results	36
Discussion	39
Conclusions	41
Section F: Bone Pathology	
Joint Diseases	43
Infectious/Inflammatory Diseases	51
Metabolic Diseases	55
Neoplastic Diseases	56
Other Diseases	57
Trauma	59
Summary	97
Section G: Dental Pathology	
Caries, Abscesses, and Antemortem Loss in Adults	99
Dental Pathology in Children	103
Dental Wear	105
Enamel Chipping	107
Linear Enamel Hypoplasia	109
Summary	112
Section H: Dental Metrics and Morphology	
Methods	119
Results	120
Section I: Metric Analysis of Postcranial Remains	
Platymeria and Ancestry	129
Limb Proportions and Stature Estimation	131
Long Bone Lengths and Proportions	132
Stature Estimation of the Refugio Sample	135
Functional Morphology and Robusticity	137

Multivariate Analysis of Femur Shaft Dimensions	138
Body Weight and Physique	139
Growth of Children	140
Discussion	141
Section j: Metric Analysis of Cranial Morphology	
Midfacial Robusticity	145
Similarity to World Samples	145
Discussion	146
Section k: Dietary Variation, Ethnicity, and Mobility	
Dietary Subgroups	149
Refugio Dietary Variation in Regional Perspective	152
Discussion	154
Section l: Summary and Conclusion	
Violence	155
Physical Hardships	155
Disease/Cause of Death	156
Karankawa Physical Characteristics	156
Evidence of Intermarrying	156
Seasonal Use of the Mission	157
References Cited	159
Appendix IIa: Burial Descriptions <i>by</i> Lee Meadows Jantz, Nicholas P. Herrmann, and Corey S. Sparks	
with Douglas Owsley, Derinna Kopp, and Katherine Weisensee	
Burial Feature 02	174
Burial Feature 03	176
Burial Feature 04	176
Burial Feature 05	183
Burial Feature 06	191
Burial Feature 07	191
Burial Feature 08	192
Burial Feature 09	193
Burial Feature 10	194
Burial Feature 11	194
Burial Feature 12	197
Burial Feature 13	199
Burial Feature 14	201
Burial Feature 15	203
Burial Feature 16	206
Burial Feature 17	215
Burial Feature 18	221
Burial Feature 19	221
Burial Feature 20	222
Burial Feature 21	223
Burial Feature 22	226
Burial Feature 23	238
Burial Feature 24	239
Burial Feature 25	242
Burial Feature 26	243
Burial Feature 27	257
Burial Feature 28	257
Burial Feature 30	258
Burial Feature 31	260
Burial Feature 32	261
Burial Feature 33	261
Burial Feature 34	261

Burial Feature 35	264
Burial Feature 36	265
Burial Feature 37	266
Burial Feature 38	266
Burial Feature 39	267
References Cited	269
Appendix II B: Inventory and Coding Forms	
Skeletal Inventory	272
Taphonomy Observations and Coding	274
Age and Sex Determination	276
Dental Inventory	278
Dental Wear	279
Coding Instructions for Inventory	280
Dental Inventory and Pathology	281
Sex and Age Code	282
Skeletal Pathology Coding Sheet	283
Appendix II C: Individuals with Enthesophytosis	
Individuals with Enthesophytosis	291
Appendix II D: Individuals with Antemortem Fractures	
Individuals with Antemortem Fractures	294
Appendix II E: Isotopic Analysis of Human Skeletal Remains from Mission Refugio by Lynette Norr	
Conclusions	305
References Cited	310

Figures:**Mission Nuestra Señora del Refugio****Osteological Analyses**

Figure C-1. Location of primary and disturbed burials by feature.	9
Figure C-2. Individual burials by ancestry in each feature.	10
Figure E-1. Frequency distribution of the Adult Ages identified in the Refugio church records.	34
Figure E-2. Location of individual burials by age group within features.	35
Figure E-3. Skeletal and Church Record Survivorship bounding one standard deviation around the parameter estimate.	37
Figure E-4. Survivorship based on the reduced sample and from a two-parameter Gompertz Model of mortality.	37
Figure E-5. Male and Female Survivorship derived from the skeletal sample from the Refugio Mission cemetery.	38
Figure E-6. Survivorship of the Refugio and San Juan Capistrano samples from a four-parameter Siler Model of mortality.	39
Figure E-7. Distribution of deaths at Refugio mission by year. No data available for 1822-1824.	39
Figure E-8. Distribution of deaths at Refugio mission by month.	39
Figure E-9. Distribution of infant deaths by year.	40
Figure E-10. Distribution of infant deaths by month.	40
Figure E-11. Distribution of Native American and non-Native American infant deaths by month.	40
Figure E-12. Distribution of traumatic deaths by month.	40
Figure F-1. Frequency of vertebral osteoarthritis and spinal osteophytosis by location.	48
Figure F-2. Frequency of Schmorl's depressions in thoracic vertebrae.	49
Figure F-3. Frequency of Schmorl's depressions in lumbar vertebrae.	49
Figure F-4. Distribution of enthesophytosis in males.	50
Figure F-5. Distribution of enthesophytosis in females.	50
Figure F-6. Frequencies of fractures by element.	61
Figure F-7. Diagram of scalping on 41RF1-BP17-087.	63
Figure F-8. Diagram of scalping on 41RF1-BP22-107.	64
Figure G-1. Maxillary average wear scores for Refugio males and females.	105
Figure G-2. Mandibular average wear scores for Refugio males and females.	105
Figure G-3. Comparison of Ernest Witte, Morhiss, and Refugio maxillary dental wear.	107
Figure G-4. Comparison of Ernest Witte, Morhiss, and Refugio mandibular dental wear.	107
Figure G-5. Enamel chipping in adults 15-34 years.	108
Figure G-6. Enamel chipping in adults 35+ years.	108
Figure G-7. Plot of hypoplasia frequency by maxillary tooth type.	110
Figure G-8. Plot of hypoplasia frequency by mandibular tooth type.	110
Figure G-9. Age distribution of hypoplasia formation for all teeth.	111
Figure H-1. Plot of group distances using principal coordinates.	122
Figure H-2. Canonical plot of group means.	123
Figure H-3. Distribution of posterior probabilities of Native American ancestry.	124
Figure H-4. Distribution of burials by non-metric posterior probabilities.	124
Figure I-1. Bivariate plot showing relationship of sitting height to subischial height.	132
Figure I-2. Canonical plot of long bone lengths showing relational group position of Refugio.	135
Figure I-3. Canonical analysis of a-p and m-l dimensions of subtrochanteric and midshaft dimensions of femora.	138
Figure I-4. Histogram showing gestational age of perinatal infants from the Refugio sample.	141
Figure I-5. Femora lengths for children from the Refugio sample plotted against dental age.	141
Figure J-1. Comparison of cheek height of Refugio to world populations as a measure of robusticity.	146
Figure K-1. Bootstrapped likelihood ratio test for a 2-cluster versus a 1-cluster finite mixture model.	150
Figure K-2. Bootstrapped likelihood ratio test for a 3-cluster versus a 1-cluster finite mixture model.	150
Figure K-3. Plot of 3-cluster solution with clusters surrounded by their one standard deviation ellipses.	150
Figure K-4. Individual burials assigned to stable isotope clusters by feature.	151
Figure K-5. Plot of Carbon apatite and collagen values for the Refugio sample.	151
Figure K-6. Plot of Texas regional sample collagen isotope values.	152
Figure K-7. Isotopic means by geographical region.	153

Figure K-8. Isotopic means by temporal period.	153
Figure IIE-1. A schematic representation of the natural variation in the isotopic composition of different categories of potential food resources found in the tropical and subtropical Americas.	296
Figure IIE-2. Plot of the difference between bone collagen and bone apatite carbonate isotope data compared to that of known diets, showing assigned ethnicity.	306
Figure IIE-3. Plot of bone apatite carbonate isotope data showing assigned ethnicity.	306
Figure IIE-4. Plot of bone collagen isotope data showing assigned ethnicity.	307

Tables:**Mission Nuestra Señora del Refugio****Osteological Analyses**

Table C-1. List of individual burials	11
Table C-2. List of ossuary elements	15
Table D-1. Cranial bone inventory by age and sex	17
Table D-2. Postcranial bone inventory by age and sex	18
Table D-3. Bone inventory by age and sex of the diaphyses and joint surfaces of the humerus	19
Table D-4. Bone inventory by age and sex of the diaphyses and joint surfaces of the radius	20
Table D-5. Bone inventory by age and sex of the diaphyses and joint surfaces of the ulna	21
Table D-6. Bone inventory by age and sex of the diaphyses and joint surfaces of the femur	22
Table D-7. Bone inventory by age and sex of the diaphyses and joint surfaces of the tibia	23
Table D-8. Bone inventory by age and sex of the diaphyses and joint surfaces of the fibula	24
Table D-9. Cranial bone inventory by age for infants and children	25
Table D-10. Humerus diaphyses inventory for infants and children	26
Table D-11. Radius diaphyses inventory for infants and children	27
Table D-12. Ulna diaphyses inventory for infants and children	28
Table D-13. Femur diaphyses inventory for infants and children	29
Table D-14. Tibia diaphyses inventory for infants and children	30
Table D-15. Fibula diaphyses inventory for infants and children	31
Table E-1. Sex counts and ratios in the burial records and skeletal sample	35
Table E-2. Juvenile to adult ratio tests	36
Table E-3. Parameter estimates of the Siler Model for the burial record and skeletal samples from Refugio mission	36
Table E-4. Parameter estimates of the Gompertz Model for the reduced burial record and skeletal samples from Refugio	37
Table E-5. Parameter estimates of the Gompertz Model for sex-specific mortality for the skeletal sample from Refugio	38
Table E-6. Parameter estimates of the Siler Model for the Refugio and San Juan Capistrano skeletal samples	38
Table E-7. Native American groups identified in the burial records	39
Table E-8. Likelihood Ratio Test for seasonality in mortality of the Refugio burial records using St. Leger (1976) method	41
Table F-1. Mild osteoarthritic lipping by age and sex	44
Table F-2. Mild osteoarthritic lipping of the humerus by age and sex	45
Table F-3. Mild osteoarthritic lipping of the radius by age and sex	45
Table F-4. Mild osteoarthritic lipping of the ulna by age and sex	45
Table F-5. Mild osteoarthritic lipping of the femur by age and sex	45
Table F-6. Mild osteoarthritic lipping of the tibia by age and sex	46
Table F-7. Refugio individuals that display moderate to severe osteophytic lipping	46
Table F-8. San Juan Capistrano individuals that display moderate to severe osteophytic lipping	47
Table F-9. Number of individuals with vertebrae by age and sex	47
Table F-10. Dimensions of Schmorl's nodes recorded in 41RF1-BP26-126	49
Table F-11. Frequency of periostitis on long bones for adults by sex and age	54
Table F-12. Individuals exhibiting cribra orbitalia	55
Table F-13. Individuals from Refugio with ectocranial porosis	58
Table F-14. Individuals from San Juan Capistrano with ectocranial porosis	58
Table F-15. Measurements of the hand and foot bones (in mm) of 41RF1-BP17-086	59
Table F-16. Individuals that exhibit spondylolysis	59
Table F-17. Individuals exhibiting antemortem trauma to the head or face	60
Table F-18. Individuals exhibiting evidence of traumatic death	62
Table F-19. Location and measurements of cutmarks on 41RF1-BP17-087	63
Table F-20. Description of the cutmarks on 41RF1-BP05-039	64
Table G-1. Refugio mission inventory and pathology in permanent dentition	100
Table G-2. Capistrano Room 26 inventory and pathology in permanent dentition	101
Table G-3. Capistrano Room 17 inventory and pathology in permanent dentition	102

Table G-4. Dental inventory and pathology in children (birth to 14 years)	103
Table G-5. Results of significant tests for differences in caries frequencies between groups	104
Table G-6. DM Index for Refugio adults	104
Table G-7. Results of Kruskal-Wallis Tests for male-female wear scores: maxillary dentition	106
Table G-8. Results of Kruskal-Wallis Tests for male-female wear scores: mandibular dentition	106
Table G-9. Profile of individuals with dentition	107
Table G-10. Inventory of teeth exhibiting enamel chipping by tooth type	108
Table G-11. Frequency of hypoplasia by tooth type	109
Table G-12. Frequency of hypoplasia by sex and tooth type	110
Table G-13. Mean age of defect formation by sex and tooth type	111
Table H-1. Summary statistics and tests of sexual dimorphism	120
Table H-2. Discriminant function results for indeterminate sex individuals	121
Table H-3. Comparative samples used in biodistance analysis	121
Table H-4. Mahalanobis D2 values for the comparative data set	122
Table H-5. Traits used in Bayesian analysis and ancestral population frequencies	123
Table H-6. Posterior probabilities and ancestry estimates calculated from dental discrete traits	125
Table I-1. Index of platymeria for Refugio and various other populations	129
Table I-2. Correlation of platymeria with femur length and ancestry	130
Table I-3. Correlation of platymeria with femur midshaft size and ancestry	130
Table I-4. Index of platymeria summary statistics for Refugio and precontact sites	131
Table I-5. Stature, Sitting Height (SH), Subischial Height (SI), and Sitting Height-Stature Ratio (SSR) for Texas populations measured in 1892	131
Table I-6. Summary statistics of long bone lengths of Refugio sample	132
Table I-7. Femur length, tibia length, and Crural Index for mission samples	133
Table I-8. Humerus length, radius length, and Brachial Index for mission samples	134
Table I-9. Stature and lower limb bone/stature ratios	136
Table I-10. Stature estimates of Refugio using formulae derived from various samples	136
Table I-11. Femur and tibia cross sectional shape indices	137
Table I-12. Femur length, a-p and m-l diameters, and index of robusticity	138
Table I-13. Summary statistics for humerus robusticity	138
Table I-14. Femur head diameters and estimated weights for Refugio and various comparative samples	139
Table I-15. Estimated heights, weights, and BMI for Refugio sample compared to measured values in various recent North American and Mesoamerican samples	140
Table J-1. Cheek height summary statistics for Refugio, Mitchell Ridge, Capistrano, and Pecos	147
Table J-2. Mahalanobis distance of Refugio crania from world population samples	147
Table K-1. Collagen ¹⁵ N and ¹³ C values for clusters identified by Gaussian mixture	150
Table K-2. Distribution of ethnic groups by dietary cluster	152
Table K-3. Sample statistics for sites used in Texas regional analysis	153
Table K-4. ANOVA results for regional and temporal comparisons	153
Table IIA-1. Vertebral Compression from Burial 41RF1-BP05-017	185
Table IIA-2. Cutmarks on cranial vault of 41RF1-BP05-039	189
Table IIA-3. Sample of postcranial fragment dimensions from 41RF1-BP16-CRE1	207
Table IIA-4. Sample of cranial and postcranial fragment dimensions from 41RF1-BP16-CRE2	208
Table IIA-5. Sample of cranial fragment dimensions from 41RF1-BP16-CRE3	209
Table IIA-6. Sample of postcranial fragment dimensions from 41RF1-BP16-CRE3	209
Table IIA-7. Sample of postcranial fragment dimensions from 41RF1-BP16-CRE4	210
Table IIA-8. Sample of postcranial fragment dimensions from 41RF1-BP16-CRE5	211
Table IIA-9. Location and measurements of damaged teeth from 41RF1-BP16-083	213
Table IIA-10. Maximum length (in mm) of Metacarpals and Metatarsals from Burial 41RF1-BP17-086	218
Table IIA-11. Location and measurements of cutmarks on burial 41RF1-BP17-087	220
Table IIA-12. Description of Schmorl's depressions from burial 41RF1-BP22-097	232
Table IIA-13. Dimensions of Schmorl's nodes recorded in 41RF1-BP26-126	254
Table IIC-1. Individuals from Refugio with Enthesophytosis	290
Table IID-1. Individuals from Refugio and San Juan Capistrano with antemortem fractures	292

Table IIE-1. Percent yield collagen from dry bone, and percent nitrogen and carbon, C/N ratios ($C/N \times 1.166667$) and isotope delta values in bone collagen from the Refugio samples	298
Table IIE-2. Percent yield apatite from dry bone and percent nitrogen (organic residue) and carbon in apatite, isotope ratios in bone carbonate and the carbon isotope carbonate-collagen difference from Refugio, Texas.	300
Table IIE-3. Number analyzed, means, and standard deviations (per mil) of internal and international standards run with the archaeological and modern samples reported here	302
Table IIE-4. Conversion of the bone collagen $\delta^{15}N$ and carbonate $\delta^{13}C$ values to the isotopic values of the diet, with age and sex of the individuals as provided with the bone samples.	304

Plates:

Mission Nuestra Señora del Refugio

Osteological Analyses

Plate B-1. Mandible fragments from 41RF1-BP26-101 illustrating the differences in staining.	5
Plate F-1. 41RF1-BP26-125: osteoarthritis of distal femur and proximal tibia.	65
Plate F-2. 41RF1-BP22-116: lumbar vertebrae exhibiting spinal osteophytosis.	66
Plate F-3. Examples of Schmorl's nodes on vertebrae.	67
Plate F-4. 41RF1-BP12-050: Distal tibia and fibula exhibiting enthesophyte.	68
Plate F-5. 41RF1-BP31-105: myositis ossificans on distal femur.	68
Plate F-6. 41RF1-BP26-I05R: medial and lateral views of innominate displaying osteomyelitis as a result of a dislocation.	69
Plate F-7. 41RF1-BP05-032: Mulberry molars.	70
Plate F-7. Continued... 41RF1-BP05-032: Hutchinson's incisor and linear hypoplastic defects.	71
Plate F-8. 41RF1-BP13-047: Moon's molars.	72
Plate F-9. 41RF1-BP17-094: infant bones exhibiting characteristics of congenital syphilis.	73
Plate F-10. 41RF1-BP17-090: femora and right tibia exhibiting periosteal expansion.	74
Plate F-11. 41RF1-BP34-106B: medial and lateral views of left ulna with severe periostitis and osteomyelitis.	75
Plate F-12. 41RF1-BP17-078: external and internal views of rib displaying osteomyelitis.	76
Plate F-13. 41RF1-BP24-068: views of third metacarpal exhibiting osteomyelitis due to fracture.	77
Plate F-14. Examples of periostitis on a tibia, humerus, and fibulae.	78
Plate F-15. Examples of sinusitis.	79
Plate F-15. Continued...	80
Plate F-16. Varying degrees of cribra orbitalia on three individuals.	81
Plate F-17. 41RF1-BP22-112: cranium with porotic hyperostosis.	82
Plate F-18. 41RF1-BP26-111: right femur with healed proximal fracture and healing distal fracture.	83
Plate F-19. 41RF1-BP20-002: views of scalloped and lytic cavitations within long bones.	84
Plate F-19. Continued... 41RF1-BP20-002: X-rays of long bones of an individual exhibiting multiple myeloma.	85
Plate F-20. 41RF1-BP02-015: bilateral osteochondritis dessicans.	86
Plate F-21. Brachymetacarpia.	87
Plate F-21. Continued... Brachymetacarpia and brachymetatarsia.	88
Plate F-22. Examples of antemortem trauma.	89
Plate F-23. 41RF1-BP22-107: examples of perimortem trauma.	90
Plate F-24. 41RF1-BP22-097: example of perimortem postcranial trauma.	91
Plate F-25. 41RF1-BP17-087: view of frontal with perimortem scalping marks.	92
Plate F-26. 41RF1-BP22-082: cutmarks on frontal and parietal.	93
Plate F-27. 41RF1-BP22-107: perimortem cutmarks on right parietal.	94
Plate F-28. 41RF1-BP05-039: view of frontal with perimortem cutmarks.	95
Plate F-29. 41RF1-BP04-021: view of perimortem cutmarks and close-up of "chop marks."	96
Plate G-1. Examples of carious lesions.	113
Plate G-1. Continued...	114
Plate G-2. Examples of antemortem tooth loss.	115
Plate G-3. Examples of abscesses.	116
Plate G-4. Example of enamel chipping.	117
Plate G-5. Linear enamel hypoplastic defects on maxillary incisors.	117

On the cover:

The remains of the Spanish Colonial mission at Refugio have long ago disappeared from the historic landscape. The photograph of Mission San José in San Antonio captures the cultural setting of the mission period.

Photograph courtesy of the Texas Department of Transportation.

Osteological Analyses

Section A

Introduction

Lee Meadows Jantz, Richard L. Jantz, Nicholas P. Herrmann, Corey S. Sparks, Katherine E. Weisensee, and Derinna V. Kopp with assistance from Douglas W. Owsley, Rebecca R. Kardash, and Roy Clark

This report presents the skeletal analysis of the human remains from the cemetery associated with the nineteenth-century Spanish mission site of Refugio (41RF1). The project was initiated by the Texas Department of Transportation in conjunction with the Center for Archaeological Research at The University of Texas at San Antonio, as a result of highway improvement in Refugio County, Texas. Excavation of the Campo Santo, or Catholic cemetery, associated with Mission Nuestra Señora del Refugio, was conducted in the summer and fall of 1999 by the Center for Archaeological Research (CAR). The University of Tennessee was contracted with to conduct the skeletal analysis of any human remains that might be excavated from the impact zone of the highway project.

The scientific and historical significance of the Refugio Mission cemetery is clear. Due to the hunting and gathering lifeways of the Karankawa, no known or documented cemeteries have been analyzed. Therefore, little is known concerning the biology of this now extinct population, and this project provides the opportunity to answer questions and perhaps even dispel myths regarding this group.

On Monday, January 17, 2000, representatives of CAR, delivered 93 boxes containing human skeletal remains to the Osteology Laboratory, Department of Anthropology, University of Tennessee, Knoxville. Lee Meadows Jantz, Nicholas P. Herrmann, and Corey S. Sparks received the remains. These remains were kept in a secured lab and examined for burial inventory and preliminary analysis from January 17-20, 2000.

Over the following months, Meadows Jantz, Herrmann, and Sparks analyzed the remains beginning with the Burial Feature 2 remains and proceeded sequentially. Derinna Kopp and Katherine Weisensee later joined the team. Analysis was conducted according to an established protocol put forth by Owsley and Jantz (1989). For each burial, composite identification numbers (COMPID) were given, and the skeletal elements were sorted and laid on trays organized anatomically. The COMPIDs consist of the archaeological site number, 41RF1, followed by the burial feature number, for example BP02. The assigned burial number was then added to the end for a COMPID. An example is 41RF1-BP05-032 which indicates it is from Burial Feature 5 and is Burial 32 from the series.

Preservation and Analysis

The skeletal material in this series is generally well preserved. However, due to a number of taphonomic influences, the majority of the bone material is fragmentary. The long-term presence of the roadway on top of the cemetery resulted in extensive fragmentation of the skeletal remains. Each fragment of bone was examined, and elements were reconstructed when possible. Unfortunately, very few crania could be reconstructed which severely limits the use of craniometrics. Due to the nature of this cemetery site, a considerable amount of commingling of individuals has occurred. In some instances, burials were identified in the field by the presence of cranial material, yet the postcranial remains were badly commingled with other burials. These postcranial remains were sorted based on age, sex, bone texture and color. If multiple individuals were identified in a single burial, the individuals were sorted based on age, sex, bone texture and color. These individuals were then given COMPIDs such as 41RF1-BP05-032A in order to maintain an association with the original burial. When skeletal elements could not be matched to an individual, they were treated as ossuary elements (see Section B of this volume for details).

A large majority of the remains were buried in the cemetery intact, however, at least five individuals represent cremations. These are the only burials that are truly identified as secondary burials. The cremation occurred elsewhere, and the cremated remains were later collected and interred at the cemetery in the same location (all within Burial Feature 16). Powell (1994) discusses cremations at the Mitchell Ridge site. Historical accounts indicate that the Karankawa, on a more or less regular basis, practiced cremation of human remains.

Careful examination of the five cremated individuals revealed no trauma or other cause of death. These individuals were sorted on the basis of color of burned bone as well as the usual age, sex, and bone texture. The color of the burned bone indicates different intensities of burning. The calcined individuals exhibit a white ceramic-like surface of the bones, while the less burned individuals exhibit some blackening and even dark browning of the bones. These are described in greater detail in Appendix IIA of this volume, the burial descriptions.

Analysis consisted of assessment of age, sex, ancestry, dentition, functional morphology, and bone pathology. The methodology employed will be described in detail in Section B. Whenever possible, the bones and teeth were measured and nonmetric traits were scored. Specimens were identified for photography and radiography. A sample of bone was taken for stable isotope analysis for 56 burials, and additional samples were taken for strontium analysis on 11 of the same burials.

Comparison Samples

The Refugio series will be compared to skeletal material from several other Texas archaeological sites including Palm Harbor (41AS80), Mitchell Ridge (41GV66), and San Juan Capistrano (41BX5). The rationale for comparison with these differing sites is based on population origins, proximity, mission life, and comparable data. More specifically, Palm Harbor and Mitchell Ridge represent prehistoric cemetery sites of early coastal populations, and San Juan Capistrano represents another Spanish mission site. The skeletal data from San Juan were collected in the same manner using the Owsley and Jantz model.

Comparisons will include analyses of craniometrics, postcraniometrics, dental metrics where possible, and general pathology. Further comparisons between Refugio and San Juan Capistrano will include the bone inventory counts, dental counts, and bone and dental pathology. This comparison is possible because both series were examined in the same protocol and data collected in the same format resulting in comparable data sets.

Research Strategy

Our approach to these remains is general; we attempted to recover and analyze all information that would enable us to reconstruct health, disease, behavior, and morphology of the Refugio population. The Center for Archaeological Research requested that the analysis address the following six questions:

1. How did the violence and physical hardships of life in this frontier area affect the populations of the mission?
2. What were the actual causes of death of the inhabitants of the mission?
3. What were the effects of Old and New World diseases on the populations of the mission?

4. What are the physical characteristics of the Karankawa?
5. Is there evidence of intermarrying between the groups?
6. Did the Native Americans use the mission as a seasonal resource or were they fully dependent on foods produced at the mission?

We have structured the report along topical lines. In each section we present our methods, analytical approaches and results, and discuss the implications of those results. We return to these six questions in Section L, General Summary and Conclusions.

Summary

Sections C and D provide detailed information of burials and skeletal inventory. A total of 165 distinct individuals were identified with an additional 12 individuals representing a minimum number of individuals represented by the ossuary elements. Section E focuses on the demography of this cemetery population. Based on analysis of the death records, seasonal use of the mission is discussed. Sections F and G provide results of the bone and dental pathology for Refugio as well as Rooms 17 and 26 from San Juan Capistrano. Analysis of the dental metrics and morphology is presented in Section H, and Sections I and J discuss the skeletal metrics. Dietary analysis is discussed in Section K. The discussion and conclusions are presented in Section L.

Osteological Analyses

Section B

Preparation of Sample and Methods for Analysis

This section describes the methods used in the basic data collection and skeletal analyses of the human burials from Refugio. The methods and analyses of skeletal and dental metrics and dental morphology are presented in their respective sections.

Inventory of the Skeletal Sample

The human remains from the Refugio mission site consist of a minimum of 165 distinct individuals. The remains are often commingled and highly fragmented, although the majority of the skeletal elements show good preservation. While there was a large amount of cranial and postcranial material recovered from the site, less than half could be completely reconstructed.

For this examination, we employ methods following Owsley et. al (1999). Baseline counts of the skeletal elements are necessary to determine the incidence of any pathological condition given the number of observable surfaces. For example, when determining the incidence of degenerative joint disease for the distal femur, the number of complete and partial distal femoral epiphyses by age, sex, and side is tabulated. This surface is scored as complete or partial according to the percent of the joint surface that could be assessed for disease.

The cranial bones are identified as complete if at least 75 percent of each bone is present. Exceptions to this are the mandible and temporal bones. The mandible is scored as complete if at least 75 percent is present and the mental eminence is also represented. The temporal bone requires that the petrous portion or the mastoid process be present in association with the squamous portion in order to be identified as complete. If the bone is poorly preserved or represented by small fragments of less than ten percent of the element, the bone is considered missing, and the inventory is left blank for this element.

Postcranial elements are inventoried in greater detail, and joint surfaces are considered separate from the rest of the bone. The following elements are scored as complete when at least 75 percent of the bone is present: the clavicle, sternum, sacrum, coccyx, patella, talus, and calcaneus.

Seventy-five percent of the scapulae, ribs, and os coxae must be represented for these elements to be scored as complete. For these elements, additional inventory conditions must be met. The scapula maximum length or width must be measurable for this element to be scored as complete. The ribs are scored as partial when the head and neck are missing, and only rib shafts that are clearly separate elements are counted. Three areas of the os coxae are considered separately, including the acetabulum, sacroiliac articular facet, and pubic symphysis. Because these areas are relevant to the determination of skeletal age and disease, at least two of these segments must be present for the element to be scored as complete.

Vertebrae are coded according to the presence of the centrum, neural arches, and articular surfaces. If the centrum is not present or is less than 25 percent complete, the vertebra is scored as partial. A vertebra is scored as complete when the majority of the centrum and either the superior or inferior articular surfaces are present. The vertebra counts of small children are based on the number of centra present.

Long bones are coded using a detailed format that provides scores for the joint surfaces and diaphyses of the bone. Each bone diaphysis is subdivided into three sections; the proximal, middle, and distal thirds of the shaft. Each third is scored as complete if at least 66 percent of the section is present; if less than 33 percent of that section is present, it is scored as absent. Proximal and distal epiphyses are scored on the inventory form under the joint surface category. In addition to the postcranial articular surfaces, the temporomandibular joint is also scored here.

Ossuary coding, used to identify elements from multiple or commingled skeletons, is utilized in this analysis. Each element is identified according to a letter and/or number designation. This coding consists of a prefix code identifying the type of bone (i.e., H for humerus, R for radius, U for ulna, F for femur, T for tibia, and B for fibula) followed by a sequential number (1, 2, 3,...) from largest to smallest in a burial feature, and then concluded by a letter designating the side of the body the element is from. For example, the code BP02-H01R would identify the largest right humerus from Burial Feature 02. If a series of elements could be grouped as belonging to a single person either by color,

morphology, and/or age and sex indicators, but not enough elements are present to designate a new burial, a letter suffix is assigned to these elements. For example, BP02-H01RA and BP02-H01LA represent humeri from the same individual. Each element and fragment is examined and documented using the inventory and coding forms that appear in Appendix IIB of this volume. This coding format is designed for computer input and to facilitate statistical analyses of large skeletal collections. The skeletal elements listed on the inventory form provide the greatest potential for diagnostic and pathology analysis.

A specific example illustrating the process followed in sorting and refitting bone fragments from adjacent commingled burials is based on a mandible that was recovered from two disturbed burials from Burial Feature 26. This example also illustrates the ability to identify and interpret different types of postmortem fracturing. This mandible provides an example illustrating how taphonomic observations can be interpreted to obtain information on bone positioning. This interpretation depends upon careful assessment of differential weathering of the various surfaces of the mandible, articulation of the broken edges, and the overall pattern of breakage.

41RF1-BP26-101

Present are six fragments of an incomplete mandible that were recovered from two disturbed burials in Feature 26. Four pieces (fragments x, y, z, and q) were associated with 41RF1-BP26-095, which is largely comprised of the axial and lower appendicular skeleton of a female aged 25 to 29 years. Two additional pieces of the mandible (fragments r and s) were found with the jumbled remains of 41RF1-BP26-101, an adult female aged 40-49 years (Plate B-1). The mandible belongs to the older adult, and the six fragments are similar in size, color, preservation quality, and dental pathology, and the fragments can be matched and refitted. The reconstructed mandible is nearly complete with only the condyles and right gonial region missing due to postmortem breakage. The mandible is fractured in similar locations on each side; just inferior to the mandibular condyles, anterior to the vertical rami, and at the mental foramina. Old postmortem and recent postmortem fractures are distinguishable on the basis of color differences in the fracture margins. Most of the fractures represent old postmortem damage, which likely occurred when 41RF1-BP26-101 was disturbed by a later interment. The fracture

margins are slightly irregular, but essentially straight and lacking the jagged edges typically observed in perimortem fractures. The color of the fracture edges is golden brown, which matches the outer surfaces of the bone fragments. In contrast, breakage evident in the right gonial region, the superior margin of the right ascending ramus, and the left condyle represents recent postmortem damage. These fracture margins are much lighter in color relative to the rest of the bone.

Although the overall color of the bone is fairly consistent, there are subtle differences in surface coloration and weathering that extend across the broken pieces indicating differential erosion that was effectively established prior to different episodes of breakage and disturbance. This slight variation reflects differential weathering that can be used to reconstruct *in situ* positioning of the bone prior to breakage and separation of the various pieces. The majority of the mandible is a golden brown, and the surface is smooth and shiny in texture (fragments y, z, and q). In contrast, the lateral surface of the left ascending ramus and body (fragments x, r, and s) have a slightly darker color and a rougher surface texture. These minute differences suggest that this surface was likely down, (i.e., the mandible was lying on the left side). This color contrast and subtle variation in the degree of deterioration partially relate to differences in moisture content along the bone surfaces as a result of moisture moving down along the bone surfaces to the low point (i.e., collecting along the lateral surface of the left side of the mandible). The appearance of the older postmortem breakage similarly suggests that the bone was resting on the left side.

Older fractures in the right mandibular body and condyle (fragments y, a, and q) exhibit clean fracture margins on the lateral or external surfaces, while the medial or internal margins are rougher and display slight peeling. These features indicate that the fracture began on the right lateral surface and moved through the ramus to the medial surface. Slight peeling of the medial surface indicates that the bone surfaces were subject to differential tensile and compressive forces that caused the ramus to fracture in a way that allowed peeling of the internal surface to occur. Older fractures in the left mandibular body (fragments y, s, and r) show corresponding features and rearticulation characteristics that also indicate that the left ramus was down, such that the intact mandible was originally resting on its left side.



Plate B-1. Mandible fragments from 41RF1-BP26-101 illustrating the differences in staining.

Determination of Sex, Age, and Ancestry

The basis of skeletal analysis relies on determining age, sex, and ancestry. An accurate determination of these demographic variables can be made using morphological, metric, and multivariate criteria. The demographic data is used to compare trends in mortality and morbidity between skeletal series. Due to the commingled and fragmentary state of some the remains from the Refugio mission site, a few of the individuals could only be assigned to broad age categories and/or tentative sex classification.

Sex Estimation

Sex assessment of complete skeletons is based on pelvic and craniofacial morphology, and, when possible, craniometric multivariate discriminant function analysis. Visual and metric assessments of the os coxae provide the most reliable indicators of sex (Bass 1987; Krogman and Iscan 1986; Phenice 1969; Stewart 1970, 1979; Suchey and Katz 1998). The features used for sex assessment diagnosis include the pubic and ischiopubic rami, the subpubic angle, and the width and depth of the sciatic notch. When a large skeletal series is recovered, intersite seriation standards of muscle attachment development and sexual dimorphism of the skeleton can also be used to assess sex.

Cranial size, morphology, and discriminant function analysis are also useful for assessing sex (Bass 1987; France 1998; Krogman and Iscan 1986; Stewart 1979). Diagnostic features of the cranium include the relative size and robusticity of the external occipital protuberance and nuchal lines, development of the supraorbital torus, size of the mastoid process and supramastoid crest, superior orbital margin contour, mental eminence shape, and gonial angle of the mandible. The cranial morphological indicators were especially useful for the Refugio series when the crania could be reconstructed. In the Refugio series, the tooth and palate size are also useful indicators of sexual dimorphism and sex determination.

Sex can also be determined using postcranial elements when more classic traits of the pelvis and crania are missing or fragmentary. The overall size and robusticity of the elements are used to identify sex (Cole 1994). Observations of the development of muscle attachment can be employed to assess the sex of an individual. Metric analyses of the postcrania, including the diameter of the humeral and femoral heads, also allow the determination of sex (Bass 1995). Sex determination for individuals less than 15 years is difficult because hormones of puberty influence the development of secondary sex characteristics. Unless obvious indicators of sex in the pelvis and/or cranium are present, no sex determination is made for younger individuals.

Age Determination

Morphological changes in the human skeleton occur throughout an individual's life during periods of growth, development, and degeneration. The formation and development of the teeth are the most accurate methods for determining age at death prior to 25 years. The determination of fetal, perinatal, and childhood age using dental calcification is based upon reference standards that document the formation and development of teeth (Deutsch et al. 1984; Moorrees et al. 1963a, 1963b; Ubelaker 1989). The growth of long bones, epiphyseal union, and specific aspects of skeletal development provide secondary, but useful supplementary indicators of juvenile age (Brothwell 1972; Fazekas and Kosa 1978; Krogman and Iscan 1986; McKern and Stewart 1957; Merchant and Ubelaker 1977; Redfield 1970; Scheuer et al. 1980; Stewart 1979; Weaver 1979). Dental calcification standards were the primary indicators of subadult age used for the Refugio series given the state of the long bones and epiphyses damaged due to postmortem destruction from multiple burial episodes and ground pressure breakage.

The determination of age after an individual reaches 25 years is based on morphological and degenerative changes in the skeleton and dental tissues. The pubic symphysis, auricular surfaces of the innominate, and the sternal end of the fourth rib are the primary indicators of adult age. Reference standards have been developed that seriate the degenerative changes in these surfaces (Brooks 1955; Brooks and Suchey 1990; Gilbert and McKern 1973; Iscan et al. 1984; Lovejoy et al. 1985; McKern and Stewart 1957; Meindl et al. 1985). Supplementary methods of age determination include epiphyseal closure, fusion of cranial and palatal sutures, dental attrition, degenerative joint disease, and radiographic assessment of bone density and osteoporosis (Krogman and Iscan 1986; Lovejoy et al. 1985; Mann et al. 1987; McKern and Stewart 1957; Meindl and Lovejoy 1985; Ubelaker 1978; Walker and Lovejoy 1985). Adult age assignment is never based on a single indicator in the skeleton, but rather, all available techniques are considered before assigning an age. In this analysis, cranial and postcranial elements are coded for age and sex when possible, however, the fragmentary state of the bone complicates these estimates. Age and sex assessment is possible for the more complete elements and the reconstructed crania. Broadly, elements and reconstructed crania are assigned into general age categories of infant (<1 year), child (1-9 years), subadult (10-19 years), young adult (20-34 years), and old adult (>34 years). If elements had morphological indicators

corresponding to developing standards, then a narrow midpoint age category was assigned in five year increments for adults (>20 years).

Ancestry

Biological affiliation is based primarily on craniofacial morphology and craniometric discriminant function analysis (Gill 1984, 1998; Gill and Rhine 1986; Ousley and Jantz 1997; Stewart 1979). Certain features of the cranium are good indicators of ancestry, including facial height, orbital shape, interorbital breadth, development and prominence of the nasal bones, nasal aperture width and shape, and the sill of the inferior nasal margin (Bass 1987; Brues 1990; Rhine 1990). In addition, the morphology of the palate and the traits of the dentition provide indicators of biological affiliation, including the degree of alveolar prognathism, shape of the palatal arch, molar crown complexity, and shovel-shaped incisors. The fragmentary condition of the facial region due to perimortem trauma and excavation damage and other taphonomic processes preclude the craniometric assessment of many individuals from the Refugio series.

Ancestry can also be determined using postcranial and dental traits. When cranial morphological traits are missing or fragmentary postcrania can be employed to assess ancestry. The femora provide an indicator of ancestry. Platymeria, the mediolateral expansion of the subtrochanteric region of the femoral shaft, is a trait more commonly found in Native American populations (Gill and Gilbert 1990). In addition, the presence of squatting facets, anterior extension of the distal articular surface of the tibia resulting from tight flexion of the ankle, are also more commonly found in Native American groups (Ubelaker 1978). Nonmetric dental traits, such as shovel-shaped incisors and the Y5 cusp patterns, are also used in determining ancestry (Bass 1995).

Dental Inventory

The dentition of each individual was inventoried and examined for pathology. Inventory of the teeth required noting the status of each tooth on a recording form. The status of each tooth was scored as one of the following:

- 1 = present (tooth only)
- 2 = present (tooth in socket)

- 3 = antemortem loss (socket only)
- 4 = antemortem loss (bone resorption)
- 5 = postmortem loss (socket only)
- 6 = partially erupted
- 7 = unerupted
- 8 = congenital absence

Calculus is mineralized plaque that accumulates at the base of a living plaque deposit, and adheres to the surface of the tooth (Hillson 1996). Calculus deposits on the teeth were scored according to the following:

- 1 = none
- 2 = flecks
- 3 = moderate
- 4 = coalesced
- 5 = heavy
- 6 = 3-dimensional

Surface abrasions on the teeth were noted and scored as to the location of the abrasion. Typically, abrasions are seen as interproximal grooves resulting from a repetitive activity such as pushing a toothpick type object between two teeth. The following codes were used:

- 1 = labial
- 2 = mesial
- 3 = distal
- 4 = mesial & distal
- 5 = occlusal

Pulp exposure was scored according to the cause, as the following:

- 1 = due to marked attrition
- 2 = due to caries lesion

conditions are based on several sources, including Buikstra and Ubelaker (1994), Dihlmann (1985), Dutour (1986), Mann and Murphy (1990), Morse (1969), Ortner and Putschar (1985), Resnick and Niwayama (1981), and Steinbock (1976).

The scoring system used to record skeletal pathology is one of the most detailed and comprehensive systems developed for tabulation of pathology. Pathological changes resulting from infection are coded according to the predominant bone cell response as follows:

- 1 = bone loss
- 2 = bone formation
- 3 = resorption plus formation

The condition is then coded for severity, state of the lesion at the time of death (i.e., active, healing), extent (i.e., localized or widespread), and specific location on the bone.

Changes in the bone due to degenerative joint disease were scored in relation to the presence and severity of hypertrophic bone formation (osteophytes), porosity, and eburnation. Each joint surface was evaluated separately and therefore each could have a different severity score for these conditions (categories adapted, with modification, from Chapman 1972; Dihlmann 1985; Jurmain 1975; Ortner 1968; Palkovich 1978).

Trauma is recorded separately using a similar detailed coding system. Postcranial fractures are coded by location in the body and the severity and state of the lesions. Cranial fractures of the frontal, parietal, temporals, and occipital are coded for the shape, size, severity, and state (e.g., remodeling) of the fracture. The presence of radiating fractures and the number of separate fractures per bone are also recorded. Fractures of the zygoma, maxillae, and mandible are coded for presence and state. All fractures are illustrated on anatomical drawings that document the location, shape, and measurements of the trauma.

Pathology

Bone Pathology

All skeletal elements were examined macroscopically, and when necessary, radiographed (x-rayed) for lesions. Identification and, if possible, diagnosis of any pathological

Dental Pathology

Macroscopic examination for carious lesions were conducted on all teeth in the Refugio series. The inventory and dental pathologies are recorded on a standard form that document the presence or absence of a tooth as well as its condition. The presence and severity of calculus formation

is scored on a scale of 1 to 6. Teeth crowns that exhibit carious lesions are scored as follows:

- 1 = pit or slight fissural start of lesion
- 2 = lesions ranging from more than code 1 to less than half of the tooth crown surface
- 3 = destruction of half or more of the crown surface
- 4 = complete destruction of the tooth crown surface

Each tooth and socket is also examined for alveolar abscessing and antemortem loss according to the following coding system:

- 1 = no disease
- 2 = periodontal abscess, with destruction of the alveolar crest
- 3 = periapical abscess, with perforation of the cortex and destruction of bone
- 4 = tooth, recently lost through abscessing, the alveolar socket not completely remodeled and resorbed
- 5 = tooth lost antemortem and socket remodeled

Hypoplasia collection procedures for the Refugio skeletal series follow the guidelines presented in Buikstra and Ubelaker (1994). Defects were observed for all available dentition macroscopically under normal lighting conditions or with the help of a 10x hand lens. The defects were scored with the following criteria:

- 0 = absence
- 1 = linear horizontal grooves
- 2 = linear vertical grooves
- 3 = linear horizontal pits
- 4 = nonlinear arrays of pits
- 5 = single pits

Location of linear and pit type defects was measured with digital calipers accurate to .01 mm from the midpoint of the buccal/labial cemento-enamel junction to the occlusal-most aspect of the defect. Wide hypoplastic bands were measured from the occlusal-most point to the apical margin of the defect in order to gauge duration of defect formation. If the buccal/labial portion of the cemento-enamel junction was unavailable, the defects were scored for presence or absence only.

The remaining sections of this volume describe and analyze the data recovered from the human skeletal remains. As mentioned previously, the methods of data collection and analysis of the skeletal metrics and dental metrics and morphology are presented in their respective sections.

Osteological Analyses

Section c

Individual Burials

A minimum of 165 individuals were identified as burials in the Refugio series. This section provides an inventory of the burials. For details regarding age, ancestry, sex, dentition, functional morphology, and pathology for each burial see Appendix IIA. The burial descriptions specifically address these features for each individual that has been identified. Table C-1 lists each of the burials providing general burial descriptions with regard to assessments of age, ancestry, sex, and occasionally preservation. Figure C-1 illustrates the location of the primary and disturbed burials identified in each feature. Figure C-2 shows the location of individuals for which an ancestry estimation was assigned.

While 165 individuals in burials were identified, a minimum of 100 identifiable skeletal elements could not be matched to a particular individual or there was not enough sorted

elements to confidently identify as a separate individual. These elements were treated as ossuary bones and given ossuary codes as part of the COMPID. Whenever possible, these elements were matched to other ossuary elements. Sex and age was estimated if diagnostic features were present. The ossuary elements are presented in Table C-2. Elements not coded in this format include vertebrae, ribs, hands and feet. Teeth were not included in ossuary coding or inventory, however these were included in the metric analysis.

In order to estimate a minimum number of individuals (MNI) represented in the ossuary elements, the elements were examined using two major age groups, adults and infants. After identifying the elements by age categories, the MNI is determined based on the most frequently repeated element for each age group. A minimum of eight adults is represented

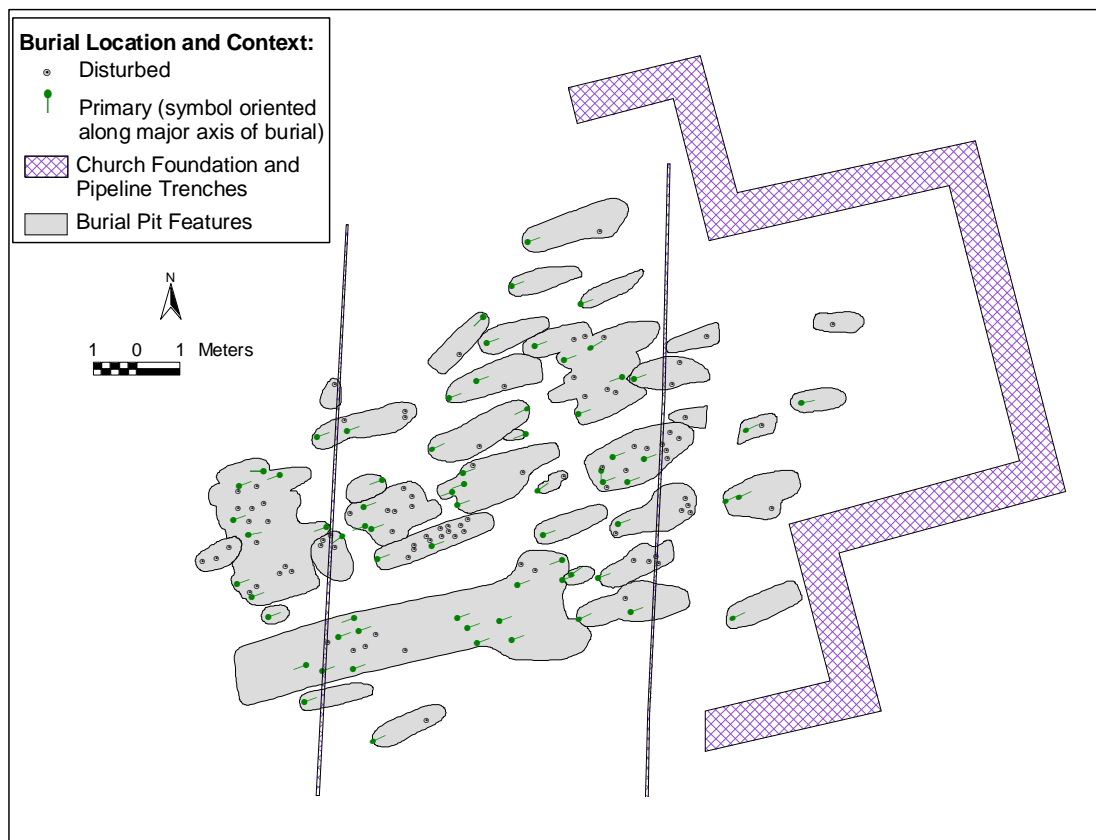


Figure C-1. Location of primary and disturbed burials by feature.

by eight adult left femora. Four left fibulae represent at least four infants. In order to determine the MNI, these groups are added together to produce an MNI of 12 individuals represented in the ossuary elements. In conclusion, a minimum of 177 individuals is represented in the Refugio sample.

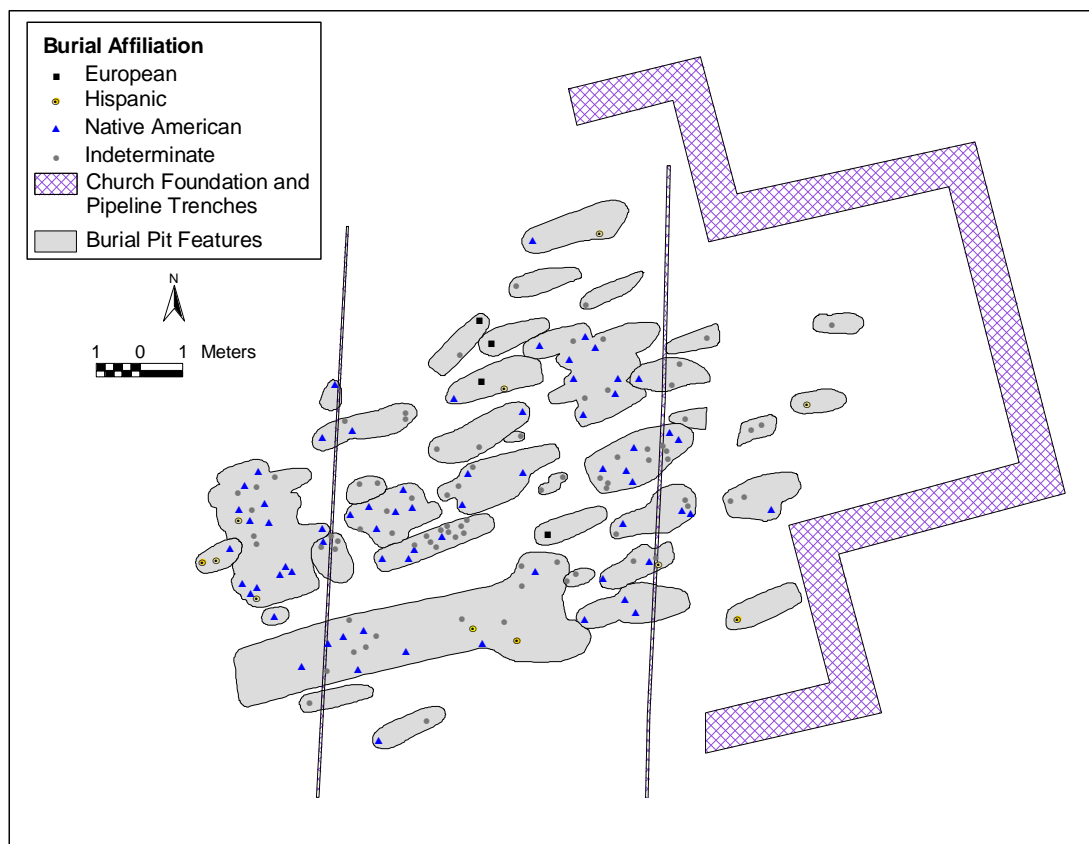

Figure C-2. Individual burials by ancestry in each feature.

Table C-1. List of individual burials

COMPID	Sex	Age	Ancestry	Comments
41RF1-BP02-006	Female	35-44	Possibly Hispanic	
41RF1-BP02-015	Female	60+	Native American	
41RF1-BP03-007	Indeterminate	12-16	Indeterminate	From a sort.
41RF1-BP04-008	Male	22-26	Native American	Extreme development of upper arms.
41RF1-BP04-012	Male	50+	Indeterminate	From a sort.
41RF1-BP04-013	Female	17-20	Native American	
41RF1-BP04-014	Female	25-34	Indeterminate	From a sort.
41RF1-BP04-016	Male	50-60	Native American/Hispanic	Numerous pathological conditions.
41RF1-BP04-018	Male	40-49	Native American	From a sort.
41RF1-BP04-019	Male	35-44	Native American/Hispanic	From a sort.
41RF1-BP04-021	Male	45-54	Native American/Hispanic	From a sort.
41RF1-BP04-022	Indeterminate	Birth - 6 months	Indeterminate	Fragmentary infant scattered around Burial 16. Extra elements found with 41RF-BP04-016 and 41RF1-BP-BP04-021.
41RF1-BP04-025	Male	30-39	Native American	From a sort.
41RF1-BP04-025A	Female	25-35	Indeterminate	From a sort.
41RF1-BP04-030	Female	14-16	Native American	
41RF1-BP05-009	Male	25-29	Native American	
41RF1-BP05-010	Indeterminate	Birth - 6 months	Indeterminate	
41RF1-BP05-011	Indeterminate	Birth - 6 months	Indeterminate	
41RF1-BP05-017	Female	20-24	Native American	
41RF1-BP05-032	Possibly Female	11-14	Possibly Native American	From a sort, severe hypoplasia on first molars and lateral incisors.
41RF1-BP05-033	Male	15-35	Indeterminate	Very disturbed burial.
41RF1-BP05-034	Indeterminate	9-12	Indeterminate	From a sort. Moderate cribra orbitalia bilaterally.
41RF1-BP05-035	Indeterminate	Birth - 6 months	Indeterminate	From a sort, duplicate infant remains mixed with burial 41RF1-BP05-055.
41RF1-BP05-036	Female	30-39	Native American	From a sort, very gracile.
41RF1-BP05-039	Male	20-24	Indeterminate	Scalped, traumatic death, cutmarks on rib, staining on verts, projectile recovered during excavation.
41RF1-BP05-040	Male	30-39	Indeterminate	From a sort, Schmorl's nodes on T12 and L1, hypoplasia on upper P4.
41RF1-BP05-040A	Male	20-29	Indeterminate	From a sort, fractured R. radius, spondylolysis of 4th lumbar.
41RF1-BP05-055	Indeterminate	Birth - 6 months	Indeterminate	From a sort, mixed with burial 41RF1-BP05-035.
41RF1-BP05-066	Possibly Male	35-50	Possibly Native American	From a sort, very fragmented skull and upper vertebrae.
41RF1-BP05-073	Indeterminate	2.5-3.5	Native American	
41RF1-BP06-031	Female	40-49	Indeterminate	
41RF1-BP07-038	Female	50+	European/Hispanic	
41RF1-BP08-020	Female	25-34	Possibly Native American	Very fragmentary, commingled with BP08-026, but not requiring a sort.
41RF1-BP08-020A	Indeterminate	Birth - 6 months	Indeterminate	From a sort.
41RF1-BP08-026	Male	25-35	Indeterminate	Very fragmented.
41RF1-BP09-041	Indeterminate	Birth - 6 months	Indeterminate	Very little is present.
41RF1-BP09-042	Female	40-49	Possibly European	Periostitis on ribs indicating pleural adhesions.
41RF1-BP10-043	Male	25-35	Indeterminate	
41RF1-BP11-044	Male	35-45	Possibly Native American	Very fragmentary. Additional teeth and maxilla were identified with Burial 58.
41RF1-BP11-044A	Indeterminate	Birth - 6 months	Indeterminate	From a sort, infant associated with 41RF1-BP11-044.
41RF1-BP11-045	Female	18-24	Native American	
41RF1-BP11-054	Male	25-35	Possibly Native American	
41RF1-BP11-058	Male	15-35	Indeterminate	Very fragmentary.

Table C-1. Continued...

COMPID	Sex	Age	Ancestry	Comments
41RF1-BP11-059	Indeterminate	Newborn	Indeterminate	
41RF1-BP12-046	Female	30-40	Native American	Very fragmentary.
41RF1-BP12-050	Male	40-44	Indeterminate	Well preserved skeleton.
41RF1-BP12-050A	Indeterminate	Birth - 6 months	Indeterminate	From a sort. Very young, late term.
41RF1-BP13-047	Male	25-35	Possibly Native American	Very fragmentary.
41RF1-BP13-053	Female	16-18	Possibly European	Odd proximal ulnae, malalignment of mandibular dentition.
41RF1-BP13-057	Male	25-35	Possibly Hispanic	From a sort, possibly an individual of mixed decent, unusual wear on upper incisors, os acromiale.
41RF1-BP14-049	Indeterminate	1.5-2.5	Indeterminate	From a sort.
41RF1-BP14-051	Indeterminate	2.5-3.5	Native American	Mostly complete porotic Hyperostosis.
41RF1-BP14-056	Male	30-34	Native American	From a sort.
41RF1-BP14-056A	Indeterminate	Birth - 6 months	Indeterminate	Infant mixed with BP14-056.
41RF1-BP14-063	Male	23-30	Native American	From a sort, associated with Burials 56, 49, and 51. Cranium identified on map but not identified during analysis.
41RF1-BP14-063A	Indeterminate	0.5-1.5	Indeterminate	From a sort.
41RF1-BP15-048	Male	30-34	Possibly Native American	From a sort, primary burial with fractured left clavicle and ankylosed thoracic vertebrae.
41RF1-BP15-048A	Male	9.5-10.5	Indeterminate	From a sort, from disturbed remains on top of Burial 52. Associated with Burials 48, 48B and 52.
41RF1-BP15-048B	Female	25-34	Indeterminate	From a sort, from disturbed remains on top of Burial 52. Associated with Burials 48, 48A, and 52.
41RF1-BP15-052	Female	19-22	Native American/Hispanic	Primary burial.
41RF1-BP15-081	Possibly Male	35+	Indeterminate	Disturbed elements recovered on the northern margin of Burial Feature 15. These elements do not match with the other burials identified in the feature.
41RF1-BP16-060	Male	25-34	Indeterminate	From a sort - very commingled burial pit.
41RF1-BP16-060A	Male	25-34	Possibly Native American	From a sort.
41RF1-BP16-060B	Indeterminate	7.5-8.5	Indeterminate	From a sort.
41RF1-BP16-060C	Indeterminate	0.5-1.5	Indeterminate	From a sort.
41RF1-BP16-067	Female	12.5-13.5	Indeterminate	From a sort.
41RF1-BP16-072	Female	17-19	Indeterminate	From a sort, commingled with many others.
41RF1-BP16-083	Male	30-39	Possibly Native American	From a sort, very muscular shoulders and arm.
41RF1-BP16-083A	Female	18-22	Native American	From a sort.
41RF1-BP16-083B	Indeterminate	10.5-11.5	Indeterminate	From a sort.
41RF1-BP16-093	Male	30-40	Native American	Very fragmentary.
41RF1-BP16-CRE1	Female	25-34	Indeterminate	From a sort, cremated remains on top of Burials 60, 67, and 72.
41RF1-BP16-CRE2	Female	30-39	Indeterminate	From a sort. Cremation one of five.
41RF1-BP16-CRE3	Male	22-30	Indeterminate	From a sort, cremation on top of Burials 60, 67, and 72.
41RF1-BP16-CRE4	Male	25-39	Indeterminate	From a sort, cremation on top of Burials 60, 67, and 72.
41RF1-BP16-CRE5	Female	25-34	Indeterminate	From a sort, cremation on top of Burials 60, 67, and 72.
41RF1-BP17-062	Male	30-45	Possibly Native American	Partially disturbed, extremely fragmentary.
41RF1-BP17-070	Indeterminate	Birth - 6 months	Indeterminate	Mostly complete.
41RF1-BP17-071	Indeterminate	2-4	Indeterminate	From a sort, fragments mixed with Burials 62 and 74. Slight cribra orbitalia.

Table C-1. Continued...

COMPID	Sex	Age	Ancestry	Comments
41RF1-BP17-074	Indeterminate	9-11	Possibly Native American	From a sort, fragmentary elements mixed with Burials 62 and 71.
41RF1-BP17-078	Male	30-34	Native American	
41RF1-BP17-079	Indeterminate	Birth - 6 months	Indeterminate	Relatively complete.
41RF1-BP17-086	Female	30-39	Native American	
41RF1-BP17-087	Male	27-35	Native American/Hispanic	From a sort, scalping cutmarks and other perimortem.
41RF1-BP17-090	Male	35-45	Native American	From a sort, possible treponemal infection.
41RF1-BP17-094	Indeterminate	fetal	Indeterminate	Possible congenital syphilis.
41RF1-BP18-061	Indeterminate	Birth - 6 months	Indeterminate	Highly fragmentary.
41RF1-BP19-064	Indeterminate	Birth - 6 months	Indeterminate	Very fragmentary.
41RF1-BP19-065	Indeterminate	Birth - 6 months	Indeterminate	
41RF1-BP20-002	Possibly Male	60+	Possibly European	Multiple Myeloma, DJD.
41RF1-BP21-069	Male	35-40	Native American	Well represented individual.
41RF1-BP21-075	Female	20-29	Possibly Native American	From a sort.
41RF1-BP21-076	Female	30-35	Native American	From a sort.
41RF1-BP22-001	Female	20-24	Native American	Very complete.
41RF1-BP22-003	Indeterminate	Birth - 6 months	Indeterminate	Very complete.
41RF1-BP22-004	Indeterminate	Birth - 6 months	Indeterminate	Almost complete, but very fragmentary.
41RF1-BP22-005	Indeterminate	Birth - 6 months	Indeterminate	Very fragmentary, systemic periosteal reaction.
41RF1-BP22-028	Possibly Male	15-35	Indeterminate	Very fragmentary and incomplete. Burial had lead ball associated with it, a piece was found with the bones.
41RF1-BP22-028A	Indeterminate	Birth - 6 months	Indeterminate	From a sort, lower portion of infant, sorted from the adult.
41RF1-BP22-077	Male	45-49	Possibly Native American	Congenital radioulna synostosis of left arm.
41RF1-BP22-082	Male	30-39	Hispanic	Trauma death scalping.
41RF1-BP22-084	Indeterminate	Birth - 6 months	Indeterminate	Very fragmentary.
41RF1-BP22-091	Male	40-50	Native American	Well represented, but fragmentary.
41RF1-BP22-097	Male	25-30	Indeterminate	Complete, but fragmentary.
41RF1-BP22-107	Male	20-24	Native American	Trauma death, scalping and skull fracture.
41RF1-BP22-109	Female	30-35	Native American	From a sort.
41RF1-BP22-112	Male	16-19	Native American	Good condition, fractured left elbow with atrophy.
41RF1-BP22-116	Male	55+	Indeterminate	Very fragmentary.
41RF1-BP22-117	Female	60+	Native American/Hispanic	Healed fractures, osteoporosis.
41RF1-BP22-117A	Indeterminate	Birth - 6 months	Indeterminate	From a sort.
41RF1-BP22-121	Indeterminate	Birth - 6 months	Indeterminate	Very fragmentary, but well represented.
41RF1-BP22-127	Male	30-39	Possibly Native American	From a sort.
41RF1-BP22-129	Male	14-17	Hispanic	Well preserved and complete.
41RF1-BP23-023	Male	25-34	Native American	From a sort, disturbed/redeposited burial represented at least two individuals.
41RF1-BP24-037	Male	18.5-19.5	Possibly Native American	From a sort, fractured lateral incisor.
41RF1-BP24-068	Female	35-44	Native American	
41RF1-BP24-080	Possibly Male	13.5-14.5	Indeterminate	From a sort, highly fragmentary.
41RF1-BP24-085	Male	25-29	Possibly Hispanic	From a sort.
41RF1-BP24-085A	Possibly Female	15-35	Indeterminate	From a sort, only dentition and mandible.
41RF1-BP25-088	Indeterminate	1-2	Indeterminate	
41RF1-BP25-089	Indeterminate	Birth - 6 months	Indeterminate	
41RF1-BP26-092	Male	50+	Possibly Native American	
41RF1-BP26-095	Female	25-29	Possibly Native American	From a sort.
41RF1-BP26-100	Male	25-29	Indeterminate	From a sort.
41RF1-BP26-100A	Female	25-34	Indeterminate	From a sort.

Table C-1. Continued...

COMPID	Sex	Age	Ancestry	Comments
41RF1-BP26-101	Female	40-50	Indeterminate	Well preserved, fragmentary.
41RF1-BP26-103	Indeterminate	1.5-2.5	Indeterminate	
41RF1-BP26-104	Indeterminate	9.5-12.5	Indeterminate	Very fragmentary.
41RF1-BP26-111	Female	60+	Possibly Native American	Osteoporosis.
41RF1-BP26-113	Female	20-24	Possibly Native American	From a sort.
41RF1-BP26-114	Indeterminate	6.5-7.5	Indeterminate	From a sort, very fragmentary.
41RF1-BP26-119	Male	25-30	Possibly Hispanic	Traumatic death - cranial and dental fractures, also congenital hip dislocation.
41RF1-BP26-119A	Male	20-30	Possibly Native American	From a sort, appendicular elements mixed with BP26-119.
41RF1-BP26-120	Male	50+	Native American	From a sort, partial skeleton, fragmentary.
41RF1-BP26-122	Female	20-29	Native American	From a sort, good preservation.
41RF1-BP26-123	Female	20-29	Possibly Native American	From a sort, fair preservation.
41RF1-BP26-125	Male	30-35	Possibly Hispanic	
41RF1-BP26-126	Male	45-60	Native American	Fragmentary.
41RF1-BP26-128	Female	20-29	Possibly Native American	From a sort.
41RF1-BP26-130	Male	20-25	Possibly Native American	From a sort.
41RF1-BP26-130A	Female	15-35	Possibly Native American	From a sort.
41RF1-BP26-131	Male	20-29	Possibly Native American	From a sort.
41RF1-BP27-098	Male	Birth - 6 months	Possibly Native American	Robust for age, very fragmentary, but mostly complete.
41RF1-BP28-096	Indeterminate	Birth - 6 months	Indeterminate	Moderately complete, very fragmentary infant.
41RF1-BP28-099	Indeterminate	1.5-2.5	Indeterminate	Highly fragmented and incomplete.
41RF1-BP30-024	Male	40-44	Possibly Hispanic	From a sort.
41RF1-BP30-102	Female	30-40	Native American/Hispanic	From a sort.
41RF1-BP30-118	Female	20-24	Hispanic	From a sort, very incomplete.
41RF1-BP31-105	Female	35-45	Possibly Native American	
41RF1-BP31-110	Male	15-35	Indeterminate	Very incomplete, quite robust.
41RF1-BP32-029	Possibly Male	35+	Indeterminate	Very incomplete, hit by pipe trench.
41RF1-BP33-115	Possibly Male	15-35	Indeterminate	Fragmented left leg bones only.
41RF1-BP34-106	Male	25-34	Indeterminate	From a sort.
41RF1-BP34-106A	Male	50-54	Possibly Native American	From a sort.
41RF1-BP34-106B	Male	15-35	Indeterminate	From a sort, lose elements grouped together based on pathological condition.
41RF1-BP34-108	Indeterminate	2.5-3.5	Indeterminate	From a sort.
41RF1-BP34-108A	Indeterminate	4.5-5.5	Indeterminate	From a sort.
41RF1-BP35-134	Male	30-40	Hispanic	Antemortem gunshot trauma to right distal femur. Green staining from buttons on ventral sacrum, and prox. R tibia.
41RF1-BP36-132	Possibly Male	15-17	Indeterminate	
41RF1-BP36-133	Male	21-29	Indeterminate	
41RF1-BP36-135	Male	25-29	Possibly Native American	
41RF1-BP37-137	Indeterminate	9.5-11.5	Indeterminate	<i>In situ</i> partial skeleton, upper half removed in trench, mixed with 41RF1-BP37-138.
41RF1-BP37-138	Indeterminate	2.5-3.5	Indeterminate	Associated with burial 41RF-BP37-137.
41RF1-BP38-136	Indeterminate	4.5-5.5	Possibly Hispanic	Very fragmentary, but complete, next to "altar."
41RF1-BP39-139	Probable Female	Probable Older Adult (35+)	Indeterminate	Extremely poor condition. Estimates based on photograph of <i>in situ</i> burial.

Table C-2. List of ossuary elements

COMPID	Sex	Age	Ancestry
41RF1-BP00-F01L	Male	Adult	Indeterminate
41RF1-BP00-F01R	Male	Young Adult	Indeterminate
41RF1-BP00-F02L	Indeterminate	Adult	Indeterminate
41RF1-BP00-F02R	Male	Adult	Indeterminate
41RF1-BP00-F03R	Indeterminate	Young Adult	Indeterminate
41RF1-BP00-H01L	Indeterminate	Adult	Indeterminate
41RF1-BP00-H02L	Indeterminate	Adult	Indeterminate
41RF1-BP00-R01L	Indeterminate	Adult	Indeterminate
41RF1-BP00-T01R	Indeterminate	Adult	Indeterminate
41RF1-BP00-V01C	Indeterminate	0.5-1.5 Months	Indeterminate
41RF1-BP04-B01R	Indeterminate	Adult	Indeterminate
41RF1-BP04-F01LB	Male	Old Adult	Indeterminate
41RF1-BP04-F01RB	Male	Old Adult	Indeterminate
41RF1-BP04-F02L	Possibly Female	Young Adult	Indeterminate
41RF1-BP04-F02RA	Female	Young Adult	Possibly Native American
41RF1-BP04-H01RC	Indeterminate	Birth - 6 months	Indeterminate
41RF1-BP04-R01RC	Indeterminate	Birth - 6 months	Indeterminate
41RF1-BP04-T01RA	Female	Young Adult	Possibly Native American
41RF1-BP04-U01L	Possibly Female	Young Adult	Indeterminate
41RF1-BP04-X01R	Indeterminate	Young Adult	Indeterminate
41RF1-BP05-B01L	Possibly Female	Young Adult	Indeterminate
41RF1-BP05-B01R	Male	Young Adult	Indeterminate
41RF1-BP05-F01LA	Possibly Female	Young Adult	Native American
41RF1-BP05-F01R	Male	Young Adult	Indeterminate
41RF1-BP05-F02RA	Possibly Female	Young Adult	Native American
41RF1-BP05-I01L	Male	Young Adult	Indeterminate
41RF1-BP05-I01R	Male	Young Adult	Indeterminate
41RF1-BP05-I02L	Male	Young Adult	Indeterminate
41RF1-BP05-I02R	Female	Young Adult	Indeterminate
41RF1-BP05-I03L	Female	Young Adult	Indeterminate
41RF1-BP05-M01C	Possibly Male	Old Adult	Indeterminate
41RF1-BP05-P01L	Possibly Male	Young Adult	Indeterminate
41RF1-BP05-P01R	Possibly Male	Old Adult	Indeterminate
41RF1-BP05-P02R	Possibly Male	Young Adult	Indeterminate
41RF1-BP05-R01LB	Male	Young Adult	Indeterminate
41RF1-BP05-R02L	Possibly Female	Young Adult	Indeterminate
41RF1-BP05-S01C	Indeterminate	Young Adult	Indeterminate
41RF1-BP05-S02C	Indeterminate	Young Adult	Indeterminate
41RF1-BP05-U01L	Male	Young Adult	Indeterminate
41RF1-BP05-U02LB	Male	Young Adult	Indeterminate
41RF1-BP05-U03L	Female	Young Adult	Indeterminate
41RF1-BP05-V01C	Possibly Male	Young Adult	Indeterminate
41RF1-BP05-X01L	Indeterminate	Young Adult	Possibly Native American
41RF1-BP07-T01L	Possibly Male	13-17 Years	Indeterminate
41RF1-BP07-T01R	Indeterminate	4-6 Years	Indeterminate
41RF1-BP09-U01R	Female	Young Adult	Indeterminate
41RF1-BP13-H01L	Male	Young Adult	Indeterminate
41RF1-BP13-H01R	Possibly Male	Young Adult	Indeterminate
41RF1-BP13-M01C	Male	Young Adult	Native American
41RF1-BP16-B01R	Male	Adult	Indeterminate
41RF1-BP16-I01L	Indeterminate	Adult	Indeterminate
41RF1-BP16-P01L	Male	Adult	Indeterminate
41RF1-BP16-V01C	Possibly Female	Young Adult	Indeterminate
41RF1-BP17-F01L	Indeterminate	Young Adult	Indeterminate
41RF1-BP17-R01R	Possibly Male	Young Adult	Indeterminate
41RF1-BP20-F01L	Indeterminate	Birth - 6 months	Indeterminate
41RF1-BP20-U01L	Indeterminate	Birth - 6 months	Indeterminate

Table C-2. Continued...

COMPID	Sex	Age	Ancestry
41RF1-BP22-B01L	Indeterminate	Birth - 6 months	Indeterminate
41RF1-BP22-B01R	Indeterminate	Birth - 6 months	Indeterminate
41RF1-BP22-B02L	Indeterminate	Birth - 6 months	Indeterminate
41RF1-BP22-B03L	Indeterminate	Birth - 6 months	Indeterminate
41RF1-BP22-F01R	Possibly Male	Young Adult	Indeterminate
41RF1-BP22-H01L	Female	Young Adult	Indeterminate
41RF1-BP22-I01R	Female	Old Adult	Indeterminate
41RF1-BP22-M01C	Indeterminate	Old Adult	Indeterminate
41RF1-BP22-R01L	Indeterminate	Birth - 6 months	Indeterminate
41RF1-BP22-S01C	Possibly Female	Old Adult	Indeterminate
41RF1-BP22-S02C	Possibly Male	Adult	Indeterminate
41RF1-BP23-H01LA	Possibly Female	Young Adult	Indeterminate
41RF1-BP23-R01LA	Possibly Female	Young Adult	Indeterminate
41RF1-BP23-U01LA	Possibly Female	Young Adult	Indeterminate
41RF1-BP23-U02L	Indeterminate	Young Adult	Indeterminate
41RF1-BP26-B01L	Indeterminate	Indeterminate	Indeterminate
41RF1-BP26-B01RC	Possibly Male	Young Adult	Indeterminate
41RF1-BP26-B02LC	Possibly Male	Young Adult	Indeterminate
41RF1-BP26-F01L	Indeterminate	Young Adult	Indeterminate
41RF1-BP26-H01L	Indeterminate	Adult	Indeterminate
41RF1-BP26-H02L	Male	Adult	Indeterminate
41RF1-BP26-I01LA	Male	Old Adult	Indeterminate
41RF1-BP26-I01R	Male	Old Adult	Indeterminate
41RF1-BP26-I02L	Indeterminate	Adult	Indeterminate
41RF1-BP26-I02RA	Male	Old Adult	Indeterminate
41RF1-BPBP26-I03L	Male	Old Adult	Indeterminate
41RF1-BP26-I03R	Male	Old Adult	Indeterminate
41RF1-BP26-I04LB	Female	Young Adult	Indeterminate
41RF1-BP26-I04RB	Female	Young Adult	Indeterminate
41RF1-BP26-I05R	Female	Young Adult	Indeterminate
41RF1-BP26-T01R	Indeterminate	Adult	Indeterminate
41RF1-BP26-U01R	Possibly Male	Adult	Indeterminate
41RF1-BP30-F01R	Possibly Male	Young Adult	Indeterminate
41RF1-BP30-H01L	Indeterminate	Old Adult	Indeterminate
41RF1-BP32-B01LA	Indeterminate	Birth - 2 Years	Indeterminate
41RF1-BP32-F01LA	Indeterminate	Birth - 6 months	Indeterminate
41RF1-BP32-H01L	Possibly Male	Old Adult	Indeterminate
41RF1-BP34-F01L	Male	Young Adult	Indeterminate
41RF1-BP34-R01LA	Indeterminate	Young Adult	Indeterminate
41RF1-BP34-S01C	Indeterminate	Young Adult	Indeterminate
41RF1-BP34-U01LA	Indeterminate	Young Adult	Indeterminate
41RF1-BP36-F01L	Indeterminate	Birth - 6 months	Indeterminate
41RF1-BP39-F01R	Male	Adult	Possibly Native American

Osteological Analyses

Section D

Bone Inventory

In this section, bone counts and comparison of Refugio with Rooms 17 and 26 from Mission San Juan Capistrano are presented. Inventory of each element was taken according to previously discussed methods. Tables D-1 through D-8 provide bone counts of the adult cranial bones (frontal, parietal, occipital, temporal, and zygomatic), axial elements (sternum, scapula, clavicle, and os coxa), long bones (humerus, radius, ulna, femur, tibia, and fibula) and foot bones (talus and calcaneus). Inventory of the joint surfaces is also presented. All bone counts are presented by age and site.

Overall, the Refugio series represents a greater number of individuals and proportionately a greater number of elements as seen in the tables. While occurring more frequently (Table D-1), cranial remains are considerably more fragmentary in the Refugio series when compared to the San Juan Capistrano samples.

The postcranial skeletal inventories of adults are presented in Tables D-2 through D-8. These tables provide inventories by sex and age group for each of the three groups. Table D-2 provides the inventory for elements of the axial skeleton and non long bones (excluding the small bones of the hand and foot). The table includes the number of bones complete and partial. Tables D-3 through D-8 provide the inventory of the long bones. These tables include the presence and completeness of the proximal and distal joint surfaces. The long bone diaphyses are divided into thirds and counts are presented by side. As with the cranial inventory, the postcranial inventories reflect the larger sample size of the Refugio series when compared to the two samples from San Juan Capistrano.

Tables D-9 through D-15 present the cranial and long bone inventory for infants and children. The samples include Refugio and Rooms 17 and 26 from San Juan Capistrano.

Table D-1. Cranial bone inventory by age and sex

SEX/ AGE	SAMPLE	FRONTAL		PARIETAL				OCCIPITAL		TEMPORAL				ZYGOMATIC				MAXILLA				MANDIBLE	
		C	P	L	P	L	P	C	P	L	P	L	P	L	P	L	P	L	P	L	P	C	P
Males 15-34	REFUGIO	8	12	4	14	3	16	6	15	5	13	5	14	9	5	9	7	3	11	4	12	8	13
	CAPISTRANO ROOM 17	4	1	4	1	5	0	3	2	4	1	3	1	5	0	2	0	5	0	4	0	3	3
	CAPISTRANO ROOM 26	7	1	8	0	6	2	7	1	6	1	7	0	5	1	7	1	6	1	7	1	3	0
Males 35+	REFUGIO	5	13	6	15	6	14	6	10	7	13	8	11	11	2	11	3	4	14	4	12	9	8
	CAPISTRANO ROOM 17	8	2	8	2	8	2	5	4	6	4	4	4	3	0	3	1	5	0	4	0	3	4
	CAPISTRANO ROOM 26	6	1	7	0	4	3	5	2	6	0	7	0	6	0	6	0	6	2	5	3	4	2
Females 15-34	REFUGIO	3	17	7	12	5	14	2	17	8	9	6	13	6	8	3	8	3	8	6	6	4	13
	CAPISTRANO ROOM 17	5	1	3	3	4	2	3	3	3	0	4	2	4	0	3	0	5	0	4	0	4	4
	CAPISTRANO ROOM 26	7	1	6	1	6	3	7	2	5	0	7	0	4	1	4	1	6	3	7	2	5	1
Females 35+	REFUGIO	3	5	1	10	3	6	3	9	3	6	2	7	5	2	5	1	0	8	1	8	4	5
	CAPISTRANO ROOM 17	3	0	3	0	4	0	3	1	2	0	2	1	1	1	2	1	5	0	4	0	3	4
	CAPISTRANO ROOM 26	5	0	3	2	3	2	3	1	2	1	2	3	3	0	3	0	3	0	3	0	3	0
Total*	REFUGIO	19	48	18	52	17	51	17	52	23	42	21	46	31	17	28	20	10	42	15	40	25	41
	CAPISTRANO ROOM 17	20	4	18	6	21	4	14	10	15	5	13	8	13	1	10	2	15	8	12	7	13	15
	CAPISTRANO ROOM 26	25	3	24	3	19	10	22	6	19	2	23	3	18	2	20	2	21	6	22	6	15	3

Key: C = complete bone; P = partial bone

*Count reflects inclusion of adults unidentified as to either age and/or sex.

Table D-2. Postcranial bone inventory by age and sex

SEX/ AGE	SAMPLE	MANUBRIUM		STERNAL BODY		SCAPULA				CLAVICLE				INNOMINATE			
		C	P	C	P	C	P	C	P	C	P	C	P	C	P	C	P
Males 15-34	REFUGIO	4	9	6	11	1	18	1	19	7	9	6	13	2	19	2	17
	CAPISTRANO ROOM 17	2	0	1	0	1	1	1	0	1	1	2	0	1	2	0	3
	CAPISTRANO ROOM 26	3	0	1	1	1	3	3	3	4	0	6	1	3	4	3	6
Males 35+	REFUGIO	2	7	1	8	0	19	0	15	7	9	6	9	5	18	4	22
	CAPISTRANO ROOM 17	1	1	0	2	2	1	2	0	1	1	2	0	2	1	2	2
	CAPISTRANO ROOM 26	2	0	2	2	2	2	2	4	5	1	4	0	3	4	5	2
Females 15-34	REFUGIO	3	4	2	9	2	12	2	15	7	12	7	10	6	8	7	12
	CAPISTRANO ROOM 17	4	0	4	0	1	2	2	1	1	1	2	0	1	1	1	3
	CAPISTRANO ROOM 26	3	0	4	0	1	4	2	3	5	0	5	0	3	3	2	4
Females 35+	REFUGIO	0	3	0	2	0	11	0	10	3	6	4	5	0	9	2	8
	CAPISTRANO ROOM 17	3	0	1	1	1	1	1	1	1	1	2	0	1	2	2	1
	CAPISTRANO ROOM 26	3	1	2	1	0	3	1	3	3	1	4	0	3	1	3	1
Total*	REFUGIO	9	23	9	30	3	61	3	59	24	37	23	37	13	56	15	59
	CAPISTRANO ROOM 17	0	1	6	3	5	5	6	2	8	4	10	3	5	6	5	9
	CAPISTRANO ROOM 26	11	1	9	4	4	12	8	13	17	2	19	1	12	12	13	13

Key: C = complete bone; P = partial bone

*Count total reflects inclusion of adults unidentified as to either age and/or sex.

Table D-2. Continued...

SEX/ AGE	SAMPLE	ACETABULUM				SACRUM		PATELLA				TALUS				CALCANEUS			
		C	P	C	P	C	P	C	P	C	P	C	P	C	P	C	P	C	P
Males 15-34	REFUGIO	5	12	2	12	2	15	18	1	12	1	14	5	15	3	12	6	10	8
	CAPISTRANO ROOM 17	1	1	2	1	1	0	2	0	2	0	3	0	3	0	3	0	3	0
	CAPISTRANO ROOM 26	4	3	4	4	5	3	3	0	3	0	6	0	5	0	6	0	5	0
Males 35+	REFUGIO	7	11	5	14	1	20	8	4	10	3	11	2	11	2	8	4	7	5
	CAPISTRANO ROOM 17	1	1	3	2	4	0	3	0	3	0	4	0	6	0	2	3	3	0
	CAPISTRANO ROOM 26	4	1	4	2	0	5	4	0	4	0	6	0	5	0	5	1	6	0
Females 15-34	REFUGIO	4	5	7	4	2	10	10	2	12	2	8	3	11	3	7	5	6	7
	CAPISTRANO ROOM 17	1	1	3	1	1	1	2	0	3	1	5	0	5	0	3	0	4	0
	CAPISTRANO ROOM 26	3	0	1	3	2	3	4	0	3	0	5	1	6	0	7	0	8	0
Females 35+	REFUGIO	1	5	2	6	0	9	7	0	4	1	6	2	7	0	2	7	2	6
	CAPISTRANO ROOM 17	2	1	2	1	2	1	3	0	1	0	1	0	2	0	1	0	1	0
	CAPISTRANO ROOM 26	2	0	0	2	0	1	3	0	4	0	2	0	2	0	3	0	3	0
Total*	REFUGIO	17	33	16	36	5	58	43	8	38	7	39	12	44	8	29	22	25	26
	CAPISTRANO ROOM 17	5	4	10	5	8	2	10	0	9	1	13	0	16	0	9	3	11	0
	CAPISTRANO ROOM 26	13	4	9	11	7	12	14	0	14	0	19	1	18	0	21	1	22	0

Key: C = complete bone; P = partial bone

*Count total reflects inclusion of adults unidentified as to either age and/or sex.

Table D-3. Bone inventory by age and sex of the diaphyses and joint surfaces of the humerus

SEX/ AGE	SAMPLE	PROXIMAL JOINT SURFACE				PROXIMAL		MIDDLE		DISTAL		DISTAL JOINT SURFACE			
		L		R		L	R	L	R	L	R	L		R	
		C	P	C	P							C	P	C	P
Males 15-34	REFUGIO	11	9	9	11	17	19	19	17	23	21	18	6	11	9
	CAPISTRANO ROOM 17	4	0	2	0	5	4	7	4	6	5	4	0	4	1
	CAPISTRANO ROOM 26	5	1	6	1	6	7	7	7	6	8	4	2	6	2
Males 35+	REFUGIO	4	8	7	4	13	12	17	13	15	14	13	6	9	7
	CAPISTRANO ROOM 17	3	1	4	0	8	5	7	3	9	3	8	1	2	0
	CAPISTRANO ROOM 26	5	0	6	1	5	9	6	9	4	7	4	1	6	1
Females 15-34	REFUGIO	8	5	10	3	14	13	18	18	20	17	12	6	10	5
	CAPISTRANO ROOM 17	7	0	3	0	8	5	6	8	7	9	4	1	5	1
	CAPISTRANO ROOM 26	5	1	5	0	6	6	8	6	7	8	5	0	4	3
Females 35+	REFUGIO	3	5	4	5	7	7	9	10	9	10	6	3	7	4
	CAPISTRANO ROOM 17	3	0	1	1	3	2	3	2	3	2	3	0	2	0
	CAPISTRANO ROOM 26	3	1	5	0	4	5	4	5	4	5	4	0	4	0
Total*	REFUGIO	27	28	31	25	51	53	66	59	71	63	50	22	38	25
	CAPISTRANO ROOM 17	17	1	10	1	24	16	23	17	25	19	19	2	13	2
	CAPISTRANO ROOM 26	18	3	22	2	21	27	21	28	21	28	17	3	20	6

Key: C = Complete bone diaphysis, P = partial diaphysis

*Count total reflects inclusion of adults unidentified as to either age and/or sex

Table D-4. Bone inventory by age and sex of the diaphyses and joint surfaces of the radius

SEX/ AGE	SAMPLE	PROXIMAL JOINT SURFACE				PROXIMAL		MIDDLE		DISTAL		DISTAL JOINT SURFACE			
		L		R		L	R	L	R	L	R	L		R	
		C	P	C	P							C	P	C	P
Males 15-34	REFUGIO	14	7	16	2	20	18	18	20	19	17	16	4	11	4
	CAPISTRANO ROOM 17	3	0	3	1	3	3	3	1	1	3	1	0	3	1
	CAPISTRANO ROOM 26	6	1	5	0	8	6	8	6	7	6	5	1	5	0
Males 35+	REFUGIO	14	4	12	4	15	13	15	13	9	9	9	4	12	2
	CAPISTRANO ROOM 17	3	0	6	0	4	7	4	7	3	7	3	0	4	1
	CAPISTRANO ROOM 26	6	1	6	0	8	7	7	6	6	5	5	0	5	0
Females 15-34	REFUGIO	10	6	14	2	19	14	21	18	20	15	9	6	13	1
	CAPISTRANO ROOM 17	1	1	3	0	2	5	4	4	2	5	2	0	5	0
	CAPISTRANO ROOM 26	5	0	5	0	9	7	8	9	6	7	6	0	4	1
Females 35+	REFUGIO	6	3	5	4	7	9	9	8	6	7	6	1	6	4
	CAPISTRANO ROOM 17	3	0	2	0	4	3	3	2	2	1	4	0	1	0
	CAPISTRANO ROOM 26	4	1	3	0	5	4	5	5	6	5	5	0	4	0
Total*	REFUGIO	46	20	47	12	63	55	66	61	55	49	40	15	42	12
	CAPISTRANO ROOM 17	10	1	14	1	13	18	14	14	8	16	10	0	13	2
	CAPISTRANO ROOM 26	21	3	19	0	30	24	28	26	25	23	21	1	18	1

Key: C = Complete bone diaphysis, P = partial diaphysis

*Count total reflects inclusion of adults unidentified as to either age and/or sex

Table D-5. Bone inventory by age and sex of the diaphyses and joint surfaces of the ulna

SEX/ AGE	SAMPLE	PROXIMAL JOINT SURFACE				PROXIMAL		MIDDLE		DISTAL		DISTAL JOINT SURFACE			
		L		R		L	R	L	R	L	R	L		R	
		C	P	C	P							C	P	C	P
Males 15-34	REFUGIO	17	4	20	4	22	20	19	20	20	18	16	0	13	2
	CAPISTRANO ROOM 17	2	0	7	0	2	7	2	6	2	2	2	0	2	0
	CAPISTRANO ROOM 26	6	1	6	1	9	7	7	7	7	7	5	1	6	0
Males 35+	REFUGIO	15	3	14	6	18	15	18	15	15	12	10	3	14	0
	CAPISTRANO ROOM 17	4	1	3	0	5	4	4	4	2	2	3	0	2	0
	CAPISTRANO ROOM 26	5	1	7	0	6	9	5	5	4	6	3	1	7	0
Females 15-34	REFUGIO	17	3	10	6	20	15	20	17	19	14	11	0	8	0
	CAPISTRANO ROOM 17	7	1	6	0	8	6	5	6	2	2	3	0	3	0
	CAPISTRANO ROOM 26	8	1	4	0	9	5	6	5	7	6	5	0	3	0
Females 35+	REFUGIO	7	3	4	6	8	9	10	9	9	8	5	1	7	2
	CAPISTRANO ROOM 17	4	0	3	0	4	3	2	2	2	2	2	0	1	0
	CAPISTRANO ROOM 26	4	1	2	0	5	2	5	2	5	3	3	0	3	0
Total*	REFUGIO	56	13	49	22	68	61	69	63	64	53	42	4	43	4
	CAPISTRANO ROOM 17	17	2	19	0	19	20	13	18	10	10	10	0	8	0
	CAPISTRANO ROOM 26	23	4	19	1	29	23	23	19	23	22	16	2	19	0

Key: C = Complete bone diaphysis, P = partial diaphysis

*Count total reflects inclusion of adults unidentified as to either age and/or sex

Table D-6. Bone inventory by age and sex of the diaphyses and joint surfaces of the femur

SEX/ AGE	SAMPLE	PROXIMAL JOINT SURFACE				PROXIMAL		MIDDLE		DISTAL		DISTAL JOINT SURFACE			
		L		R		L	R	L	R	L	R	L		R	P
		C	P	C	P							C	P	C	P
Males 15-34	REFUGIO	21	7	20	5	23	25	21	27	21	24	13	9	16	6
	CAPISTRANO ROOM 17	2	1	3	1	5	8	5	4	5	6	1	2	3	2
	CAPISTRANO ROOM 26	7	2	5	1	10	7	11	7	9	9	7	1	6	2
Males 35+	REFUGIO	11	5	13	4	18	18	19	19	17	16	11	6	13	6
	CAPISTRANO ROOM 17	5	1	2	2	9	5	8	6	7	6	5	2	5	1
	CAPISTRANO ROOM 26	7	2	8	1	9	10	9	10	9	10	6	2	7	2
Females 15-34	REFUGIO	15	2	14	3	18	18	22	23	17	20	8	11	9	11
	CAPISTRANO ROOM 17	5	1	6	0	8	8	8	7	8	5	4	0	3	0
	CAPISTRANO ROOM 26	5	1	3	1	7	6	7	5	5	5	3	2	2	2
Females 35+	REFUGIO	6	4	6	3	10	9	10	10	7	9	2	8	2	7
	CAPISTRANO ROOM 17	3	0	1	3	3	5	2	5	2	6	1	1	3	1
	CAPISTRANO ROOM 26	2	0	2	1	3	3	4	3	4	3	3	1	3	0
Total*	REFUGIO	53	18	54	15	71	72	75	80	63	70	34	34	40	30
	CAPISTRANO ROOM 17	15	3	12	6	25	26	23	22	22	23	11	5	14	4
	CAPISTRANO ROOM 26	21	5	18	4	29	26	31	25	27	27	19	6	18	6

Key: C = Complete bone diaphysis, P = partial diaphysis

*Count total reflects inclusion of adults unidentified as to either age and/or sex

Table D-7. Bone inventory by age and sex of the diaphyses and joint surfaces of the tibia

SEX/ AGE	SAMPLE	PROXIMAL JOINT SURFACE				PROXIMAL		MIDDLE		DISTAL		DISTAL JOINT SURFACE			
		L		R		L	R	L	R	L	R	L		R	
		C	P	C	P							C	P	C	P
Males 15-34	REFUGIO	17	3	15	6	21	21	21	20	19	21	20	3	21	2
	CAPISTRANO ROOM 17	2	1	4	0	4	4	5	4	4	5	4	0	3	1
	CAPISTRANO ROOM 26	7	0	7	0	5	7	6	8	5	7	4	0	7	0
Males 35+	REFUGIO	9	10	9	9	17	17	19	18	16	17	14	2	10	5
	CAPISTRANO ROOM 17	2	1	5	4	7	10	6	6	10	10	8	1	8	0
	CAPISTRANO ROOM 26	7	1	5	1	8	8	7	8	8	8	8	0	8	1
Females 15-34	REFUGIO	6	10	4	13	18	18	17	21	16	19	11	3	12	5
	CAPISTRANO ROOM 17	5	0	4	0	5	6	4	7	5	7	5	0	7	0
	CAPISTRANO ROOM 26	3	4	3	2	7	6	6	7	6	6	6	0	4	0
Females 35+	REFUGIO	3	5	3	5	10	9	11	10	8	7	7	2	5	2
	CAPISTRANO ROOM 17	2	0	2	0	2	2	2	2	2	2	2	0	2	0
	CAPISTRANO ROOM 26	4	0	2	0	4	3	4	3	4	3	4	0	3	0
Total*	REFUGIO	35	28	31	33	66	65	68	70	59	65	52	10	48	14
	CAPISTRANO ROOM 17	11	2	15	4	18	22	17	19	21	24	19	1	20	1
	CAPISTRANO ROOM 26	21	5	17	3	24	24	23	26	23	24	22	0	22	1

Key: C = Complete bone diaphysis, P = partial diaphysis

*Count total reflects inclusion of adults unidentified as to either age and/or sex

Table D-8. Bone inventory by age and sex of the diaphyses and joint surfaces of the fibula

SEX/ AGE	SAMPLE	PROXIMAL		MIDDLE		DISTAL	
		L	R	L	R	L	R
Males 15-34	REFUGIO	21	18	24	18	20	19
	CAPISTRANO ROOM 17	3	4	4	4	3	2
	CAPISTRANO ROOM 26	3	6	5	8	4	7
Males 35+	REFUGIO	16	15	18	16	16	16
	CAPISTRANO ROOM 17	5	4	5	5	6	6
	CAPISTRANO ROOM 26	7	4	8	6	9	8
Females 15-34	REFUGIO	15	14	18	17	17	15
	CAPISTRANO ROOM 17	4	5	3	5	3	5
	CAPISTRANO ROOM 26	6	6	8	6	6	9
Females 35+	REFUGIO	9	8	9	8	7	8
	CAPISTRANO ROOM 17	3	2	3	2	4	3
	CAPISTRANO ROOM 26	6	2	5	3	3	3
Total	REFUGIO	61	57	70	59	60	58
	CAPISTRANO ROOM 17	15	15	15	16	16	16
	CAPISTRANO ROOM 26	22	18	26	23	22	27

Key: C = Complete bone diaphysis, P = partial diaphysis

*Count total reflects inclusion of adults unidentified as to either age and/or sex

Table D-9. Cranial bone inventory by age for infants and children

AGE	SAMPLE	FRONTAL		PARIETAL			OCCIPITAL		TEMPORAL			ZYGOMATIC			MAXILLA			MANDIBLE					
		C	P	C	L	R	C	P	C	L	R	C	L	R	C	L	R	C	P				
Birth-0.5	REFUGIO	1	9	0	16	0	15	2	12	2	9	1	18	4	1	6	2	0	3	0	3	1	18
	CAPISTRANO ROOM 17	1	4	0	3	1	1	2	7	1	5	4	4	4	0	4	1	2	1	2	2	8	4
	CAPISTRANO ROOM 26	0	0	0	0	0	0	0	0	0	0	0	0	0	0	0	0	0	0	0	0	0	0
1-4	REFUGIO	1	6	2	5	1	7	1	5	0	4	0	5	1	1	0	0	1	3	0	2	1	2
	CAPISTRANO ROOM 17	0	2	1	1	0	1	2	0	0	2	0	2	1	0	1	0	2	1	2	2	1	2
	CAPISTRANO ROOM 26	0	0	0	0	0	0	0	0	0	0	0	0	0	0	0	0	0	0	0	0	0	0
5-9	REFUGIO	0	0	0	1	0	1	0	1	0	1	0	1	0	0	0	0	0	1	0	1	0	0
	CAPISTRANO ROOM 17	0	0	0	1	0	1	0	0	0	1	0	0	1	0	0	0	2	1	2	2	1	0
	CAPISTRANO ROOM 26	1	1	2	0	1	1	0	2	1	0	1	0	1	0	1	0	2	0	1	0	1	1
10-14	REFUGIO	1	5	2	3	1	3	1	3	1	1	0	4	1	1	0	1	0	3	0	2	3	1
	CAPISTRANO ROOM 17	0	0	0	1	0	0	0	1	0	1	0	0	0	0	0	0	2	1	2	2	0	1
	CAPISTRANO ROOM 26	1	0	1	1	1	1	2	0	1	0	2	0	0	1	1	0	1	0	1	0	1	0
Total	REFUGIO	3	20	4	25	2	26	4	21	3	15	1	28	6	3	6	3	1	10	0	8	5	21
	CAPISTRANO ROOM 17	1	6	1	6	1	3	4	8	1	9	4	6	6	0	5	1	2	1	2	2	10	7
	CAPISTRANO ROOM 26	2	1	3	1	2	2	2	2	2	0	3	0	1	1	2	0	3	0	2	0	2	1

Key: C = Complete, P = Partial

Table D-10. Humerus diaphyses inventory for infants and children

AGE	SAMPLE	PROXIMAL		MIDDLE		DISTAL	
		L	R	L	R	L	R
Birth-0.5	REFUGIO	9	8	13	13	9	12
	CAPISTRANO ROOM 17	8	11	11	14	12	17
	CAPISTRANO ROOM 26	2	2	3	0	1	0
1-4	REFUGIO	2	4	3	4	3	3
	CAPISTRANO ROOM 17	2	3	3	4	3	5
	CAPISTRANO ROOM 26	2	1	2	1	1	0
5-9	REFUGIO	1	2	1	2	1	2
	CAPISTRANO ROOM 17	1	1	1	3	2	3
	CAPISTRANO ROOM 26	2	0	2	1	2	1
10-14	REFUGIO	3	1	2	1	2	1
	CAPISTRANO ROOM 17	0	0	0	0	0	0
	CAPISTRANO ROOM 26	1	1	1	1	1	1
Total	REFUGIO	15	15	19	20	15	18
	CAPISTRANO ROOM 17	11	15	15	21	17	25
	CAPISTRANO ROOM 26	7	4	8	3	5	2

Table D-11. Radius diaphyses inventory for infants and children

AGE	SAMPLE	PROXIMAL		MIDDLE		DISTAL	
		L	R	L	R	L	R
Birth-0.5	REFUGIO	10	7	14	10	12	8
	CAPISTRANO ROOM 17	7	9	10	11	12	11
	CAPISTRANO ROOM 26	3	2	2	1	3	0
1-4	REFUGIO	2	1	5	3	2	1
	CAPISTRANO ROOM 17	2	4	10	11	3	4
	CAPISTRANO ROOM 26	3	2	3	6	2	5
5-9	REFUGIO	1	0	1	0	1	1
	CAPISTRANO ROOM 17	1	1	10	11	1	1
	CAPISTRANO ROOM 26	2	0	1	0	0	0
10-14	REFUGIO	0	1	1	3	3	2
	CAPISTRANO ROOM 17	0	0	10	11	0	0
	CAPISTRANO ROOM 26	1	1	2	1	2	1
Total	REFUGIO	13	9	21	16	18	12
	CAPISTRANO ROOM 17	10	14	10	11	16	16
	CAPISTRANO ROOM 26	9	5	8	8	7	6

Table D-12. Ulna diaphyses inventory for infants and children

AGE	SAMPLE	PROXIMAL		MIDDLE		DISTAL	
		L	R	L	R	L	R
Birth-0.5	REFUGIO	15	13	14	13	8	7
	CAPISTRANO ROOM 17	9	10	9	9	7	7
	CAPISTRANO ROOM 26	3	3	0	2	0	0
1-4	REFUGIO	2	2	4	1	1	1
	CAPISTRANO ROOM 17	4	6	4	6	2	3
	CAPISTRANO ROOM 26	0	1	0	0	0	1
5-9	REFUGIO	0	0	1	0	2	1
	CAPISTRANO ROOM 17	0	1	0	1	0	1
	CAPISTRANO ROOM 26	2	0	1	1	0	1
10-14	REFUGIO	3	1	2	4	0	3
	CAPISTRANO ROOM 17	0	0	0	0	0	0
	CAPISTRANO ROOM 26	2	1	2	1	2	1
Total	REFUGIO	20	16	21	18	11	12
	CAPISTRANO ROOM 17	13	17	13	16	9	11
	CAPISTRANO ROOM 26	7	5	3	4	2	3

Table D-13. Femur diaphyses inventory for infants and children

AGE	SAMPLE	PROXIMAL		MIDDLE		DISTAL	
		L	R	L	R	L	R
Birth-0.5	REFUGIO	16	11	19	12	8	6
	CAPISTRANO ROOM 17	13	16	13	13	13	12
	CAPISTRANO ROOM 26	0	0	0	1	2	2
1-4	REFUGIO	5	5	6	8	5	2
	CAPISTRANO ROOM 17	4	5	5	5	4	4
	CAPISTRANO ROOM 26	3	3	0	1	0	0
5-9	REFUGIO	3	2	3	2	0	2
	CAPISTRANO ROOM 17	1	1	1	1	1	1
	CAPISTRANO ROOM 26	1	2	1	2	1	2
10-14	REFUGIO	0	1	2	2	3	3
	CAPISTRANO ROOM 17	0	0	0	0	0	0
	CAPISTRANO ROOM 26	3	3	3	3	3	3
Total	REFUGIO	24	19	30	24	16	13
	CAPISTRANO ROOM 17	18	22	19	19	18	17
	CAPISTRANO ROOM 26	7	8	4	7	6	7

Table D-14. Tibia diaphyses inventory for infants and children

AGE	SAMPLE	PROXIMAL		MIDDLE		DISTAL	
		L	R	L	R	L	R
Birth-0.5	REFUGIO	8	7	12	9	6	5
	CAPISTRANO ROOM 17	13	12	11	12	12	12
	CAPISTRANO ROOM 26	0	1	0	2	0	0
1-4	REFUGIO	3	3	3	3	1	1
	CAPISTRANO ROOM 17	3	4	3	4	2	3
	CAPISTRANO ROOM 26	2	5	2	4	2	1
5-9	REFUGIO	2	1	0	0	0	1
	CAPISTRANO ROOM 17	2	2	1	2	1	1
	CAPISTRANO ROOM 26	1	1	1	1	1	0
10-14	REFUGIO	5	3	3	2	2	1
	CAPISTRANO ROOM 17	0	0	0	0	0	0
	CAPISTRANO ROOM 26	3	3	3	3	3	3
Total	REFUGIO	18	14	19	14	9	8
	CAPISTRANO ROOM 17	18	18	15	18	15	16
	CAPISTRANO ROOM 26	6	10	6	10	6	4

Note: Count reflects inclusion of subadults unidentified as to specific age range

Table D-15. Fibula diaphyses inventory for infants and children

AGE	SAMPLE	PROXIMAL		MIDDLE		DISTAL	
		L	R	L	R	L	R
Birth-0.5	REFUGIO	6	6	12	8	6	7
	CAPISTRANO ROOM 17	7	5	9	5	9	5
	CAPISTRANO ROOM 26	0	0	1	2	1	2
1-4	REFUGIO	2	2	2	2	2	2
	CAPISTRANO ROOM 17	3	1	4	2	2	2
	CAPISTRANO ROOM 26	3	3	2	4	2	6
5-9	REFUGIO	1	1	1	2	1	1
	CAPISTRANO ROOM 17	2	1	0	1	2	1
	CAPISTRANO ROOM 26	1	0	1	0	1	1
10-14	REFUGIO	1	1	4	2	2	2
	CAPISTRANO ROOM 17	0	0	0	0	0	0
	CAPISTRANO ROOM 26	3	3	3	3	3	3
Total	REFUGIO	10	10	19	14	11	12
	CAPISTRANO ROOM 17	12	7	15	8	13	8
	CAPISTRANO ROOM 26	7	6	7	9	7	12

Osteological Analyses

Section E
Demography

In this section, we describe and compare the demographic structure of skeletal sample as derived from our analysis and the recorded burial sample as interpreted from various historical documents associated with Mission Nuestra Señora del Refugio (Oberste 1942). The Refugio burial sample offers a rare opportunity to compare archaeologically derived skeletal data to historical records. Both skeletal data and historic records are far from ideal, and numerous problems exist in these samples. However, each sample provides a unique picture of life at the Refugio mission. Comparisons are based on a series of demographic parameters as derived from the analysis of each data source. This section includes: Methods, Sample Descriptions, Mortality Models and Results, Discussion, and Conclusion. CAR staff compiled the Burial Record data utilizing Oberste's (1942) history of the mission supplemented by the 1810 census. The skeletal data is derived directly from our analysis. Finally, the age-at-death profile from the Refugio skeletal data is compared to the profile derived from skeletal data from San Juan Capistrano. For this comparison we utilized age data published by Humphreys (1971), which focuses on the eighteenth-century Coahuiltecan Mission population.

Methods

We compiled the skeletal data based on age range and sex. Basic vital statistics were calculated including sex ratios and adult to juvenile ratios (Buikstra and Konigsberg 1985). Similar data were distilled from the burial records. The burial records provide good information for juveniles and typically identify the sex of the deceased. However, adult ages are frequently missing. These individuals (n=30) were simply assumed to be adults and an age range of 15 to 100 years was utilized in the demographic reconstruction.

Comparisons of the skeletal data and burial record were based on the vital statistics as well as on the estimated survivorship and hazard function for each sample. To facilitate the comparison of the survivorship and mortality hazard, parameters of these functions (i.e., Siler or Gompertz) were modeled with *MLE* (Holman 2000). *MLE* is a programming language for estimating parameters of likelihood models, especially survival models (Holman 2000:1). In our analysis of the skeletal sample,

general age ranges (not the specific age codes within the aging system) were utilized to model the age-at-death distributions. The large age ranges were selected to provide a less biased age-at-death distribution as compared to the restricted one to five year age ranges associated with the specific age codes. For the data from the mission burial record, specific ages were bracketed by one to six months for the subadults and one year for the adults. For the adults of unknown age in the burial record, we assigned an age range of 15 to 100 years.

Using *MLE*, a four-parameter Siler model as specified below was modeled to examine the entire age-at-death distribution of both the burial records and the skeletal sample.

$$S(a) = \exp\left(-\frac{a_1}{b_1}(1-e^{-b_1a}) + \frac{a_3}{b_3}(1-e^{-b_3a})\right)$$

$$h(a) = a_1 \exp(-b_1a) + a_3 \exp(b_3a)$$

Here a is a random variate representing an exact age at death, α_1 and β_1 are parameters that represent the juvenile component of mortality, and α_3 and β_3 represent the senescent component (Wood et al. 1992). The baseline hazard parameter (α_2) is excluded in this analysis given that the parameter is rarely estimable from paleodemographic data (Konigsberg, personal communication).

A two-parameter Gompertz model as specified below was employed to examine the adult and sex mortality and survivorship.

$$S(a) = \exp\left[\frac{a}{b}(1-e^{-ba})\right]$$

$$h(a) = a \exp(ba)$$

Here a is a random variate representing an exact age at death, and α and β represent the scale and shape parameters, respectively (Holman 2000).

Statistical tests consisted of basic Chi-Square Test of Similarity of the sex and age ratios and Likelihood Ratio Tests of the modeled functions. If the functions were significantly different, then the modeled functions and parameters were examined in an effort to identify the sources of the difference.

Sample Descriptions

The burial record sample consists of 125 individuals in ranging age from newborn (or stillborn) to 80. There are 54 aged subadults (<15 years) in the sample. Three individuals are simply identified as children, and we assigned an age of 3 to 15 years to these individuals within our *MLE* model. Subadults represent roughly 46 percent of individuals recorded in the mission documents. The remaining 68 individuals are adults of which 36 have ages. An examination of the known age adults reveals moderate age heaping at the decade nodes (e.g., 40, 50, and 70), especially in the older adults (see Figure E-1). This pattern suggests that most adult ages are estimates rather than known ages. Such a pattern would be consistent with the history of the mission given that most of the adult Native American inhabitants of the mission were born prior to significant interaction with the Spanish mission system. The sex ratio for the entire burial record is 1.8 (see Table E-1). For adults, this ratio is 2 to 1 in favor of males.

The skeletal sample consists of 165 individuals ranging in age from neonate to over 60 years. Most of these individuals are fragmentary, but general age ranges could be made on most individuals. A plot of the burials by general age class is shown in Figure E-2. As is evident in the plot, the distribution of burials by age is fairly consistent and even across the entire cemetery area. Fifty-two subadults

(32 percent) are present in the skeletal series. The remaining individuals (n=113) are adults who were over 15 years old at death. Adult age ranges typically vary from 10 to 15 years. For older adults aged greater than 50 or 60 years, age ranges assigned extend to 100 years to account for the variability in older age estimates. The adult sex ratio of the skeletal series is 1.6. This value is lower but not significantly different from the adult ratio documented in the burial records ($X^2 = .51$, $p = .48$, d.f. = 1).

The age structures of the two samples appear dramatically different with nearly half of the burial record consisting of subadults as compared to only a third in the skeletal sample. Detailed examination of the ages of each sample reveals the primary difference lies in the newborn to one-year range. In this age cohort, infants are under-represented in the skeletal series as compared to the burial records with one-year old infants (0-0.9 years) representing 22 percent and 29 percent of each sample, respectively. The relative abundance of infants in the burial record as compared to the skeletal series is significant based on a chi-square test ($X^2 = 6.47$, $p = .011$, d.f. = 1). Following procedures recommended by Konigsberg et al. (1989) and Bocquet-Appel and Masset (1977), two different age ratios were calculated which are thought to circumvent the problem of infant under-numeration (Table E-2). The ratios are not significantly different, and they suggest marked infant under-numeration in the skeletal sample as compared to the burial record.

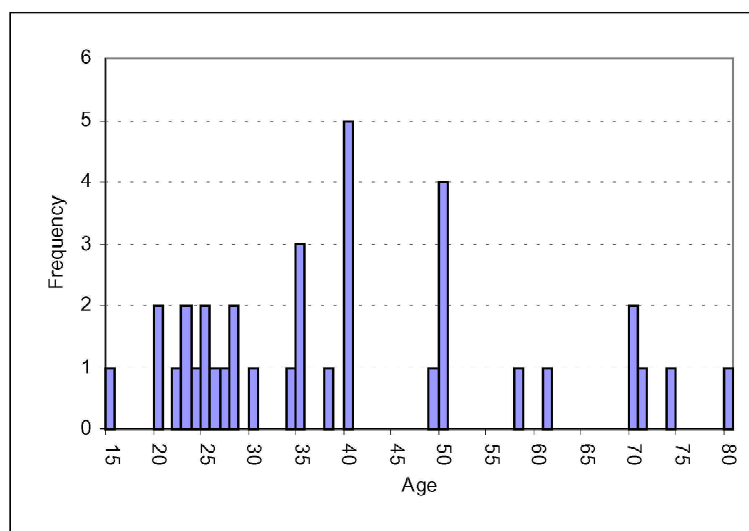


Figure E-1. *Frequency distribution of the Adult Ages identified in the Refugio church records.*

Table E-1. Sex counts and ratios in the burial records and skeletal sample

Sex	Skeletal Sample (Adults)	Burial Records (All / Adults)
Male	72	80 / 48
Female	45	45 / 24
Ratio	1.6	1.8 / 2.0

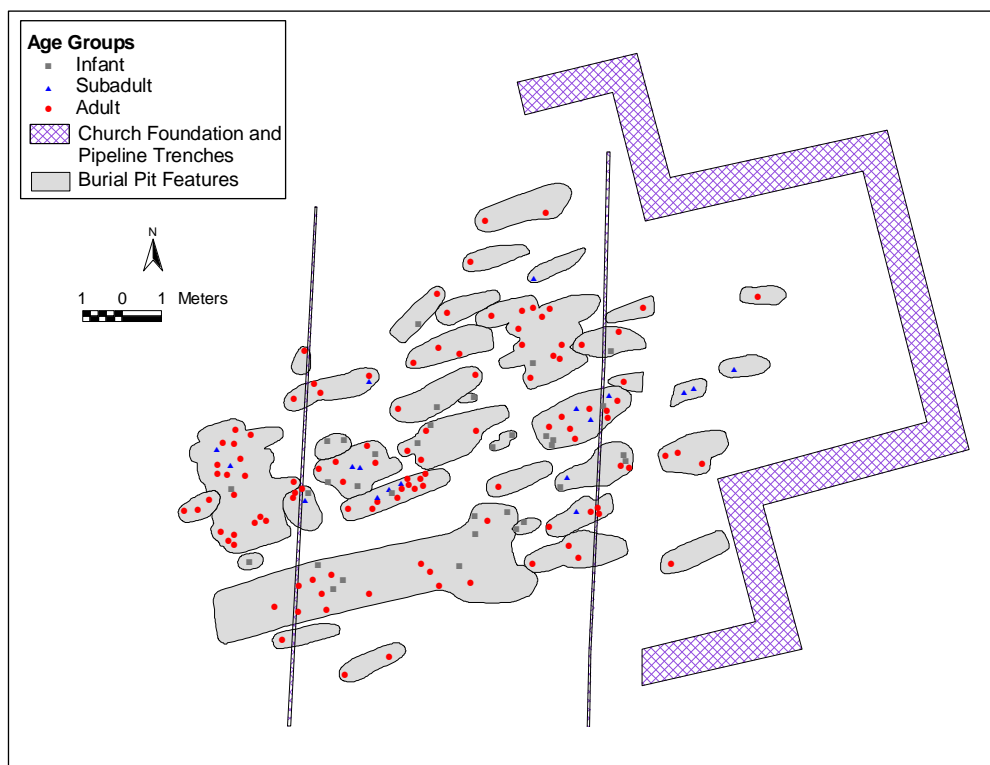


Figure E-2. Location of individual burials by age group within features.

Table E-2. Juvenile to adult ratio tests

Test	Skeletal Sample	Burial Records
Juvenile:Adult Ratio	0.133 (14/105)	0.104 (7/67)
(5-14.9/20+) ¹		
20+/5+ ²	0.827 (105/127)	0.870 (67/77)

¹ Bacquet-Appel and Masset (1977)² Konigsberg et al. (1989)

Mortality Models and Results

Four different model comparisons were conducted using *MLE*. First, we examined the fit of a four-parameter Siler model to the full data sets, both the burial record and the skeletal sample. Second, we examined the age-at-death distributions of the two samples for those individuals three years old or greater using a two-parameter Gompertz model. This procedure was conducted to examine the influence of infant mortality component on the overall model. Third, sex specific adult age-at-death distributions (>15 years) were modeled for the skeletal sample using a two-parameter Gompertz model. Fourth, we examine the Refugio skeletal data to a skeletal sample from San Juan Capistrano (n=84) described by Humphreys (1971). Finally, we examine the Burial Record in detail examining the monthly distribution of deaths by various population subsets (e.g., Native American, infants, and traumatic deaths).

The fit of Siler competing hazards models converged normally for both samples. The high percentage of infants and low representation of mid-aged juveniles (3-10) in both samples results in extreme values for the infant mortality

parameters (α_1 and β_1), especially for the skeletal sample (Table E-3). Also, the expanded standard deviation in the adult range of the Church Record sample illustrates the influence of the unaged adults, which were placed in the model as ranging in age from 15 to 100. These differences result in a significant Likelihood Ratio Test ($\Lambda = 18.17$, $p = .0018$, d.f. = 4). A plot of survivorship in Figure E-3 clearly shows these differences.

In order to test the influence of infant under-numeration in the skeletal sample, all individuals below three years old at death were excluded from both samples. Two-parameter Gompertz models of mortality were fitted to the reduced samples (Table E-4). The models both converged normally, but the marked differences in age-at-death distribution remained (Figure E-4). Survivorship is much lower in the skeletal sample, and the Likelihood Ratio Test supports this observation with a value of 15.1 ($p = .0005$, d.f. = 2). These differences probably relate to a combination of factors. Specifically, the adult age-at-death distribution based on the church records is moderately muted due to the large number of unaged adults. These individuals act to flatten the adult age-at death distribution. In addition, skeletal age-at-death

Table E-3. Parameter estimates of the Siler Model for the burial record and skeletal samples from Refugio mission¹

Parameter	Skeletal Sample	Burial Records
α_1	23.94	4.62
β_1	144.39	14.60
α_3	0.0136	0.0177
β_3	0.0429	0.0208
$\ln(L)$	-394.1	-356.1

¹ Likelihood Ratio Test: $\ln(L)$ combined samples -758.8, $\Lambda = 18.17$, $p = .0018$, d.f. = 4

Table E-4. Parameter estimates of the Gompertz Model for the reduced¹ burial record and skeletal samples from Refugio mission²

Parameter	Skeletal Sample	Burial Records
α	0.0101	0.0105
β	0.0514	0.0320
$\ln(L)$	-287.5	-215.8

¹For individuals over 3 years old.

² Likelihood Ratio Test: $\ln(L)$ combined samples -510.9, $\Lambda = 15.1$, $p = .0005$, d.f. = 2

estimates are likely biased. Older adults are probably under-aged as has been demonstrated with numerous paleodemographic studies.

We also examined the age-at-death distribution differences of the sexes within the skeletal sample. Within the skeletal sample males outnumbered females by a ratio of eight to five (1.6). Using a two-parameter Gompertz model of mortality, male and female age-at-death distributions were estimated. The parameters and the log-likelihoods of these models are provided in Table E-5. Mortality for males and females in the skeletal sample do not significantly differ ($\Lambda = 2.31$, $p = .315$, d.f. = 2). Survivorship curves based on these models do illustrate a common pattern evident in sex-specific mortality (Figure E-5). In the case of the Refugio skeletal sample, females show increased mortality during young adult ages as compared to male. However,

older female survivorship is greater than their older male counterparts. This pattern is consistent in the Burial Record as well with females showing higher, but not significant, survivorship in older age ranges ($\Lambda = 2.20$, $p = .333$, d.f. = 2).

A comparison of Refugio to a skeletal sample from San Juan Capistrano proved interesting. The Capistrano skeletal demographic data was derived from Humphreys (1971). For individuals with assigned ages, one-year intervals were incorporated in the *MLE* estimation. For unknown adults and subadults, age ranges were utilized in the model (15 to 100 for adults, 0 to 1 for infant, and 0 to 15 for general subadult). The Siler model parameters are presented in Table E-6. The infant mortality parameters (α_i and β_i) are quite different and suggest differences in subadult mortality between the sites. This difference is evident in

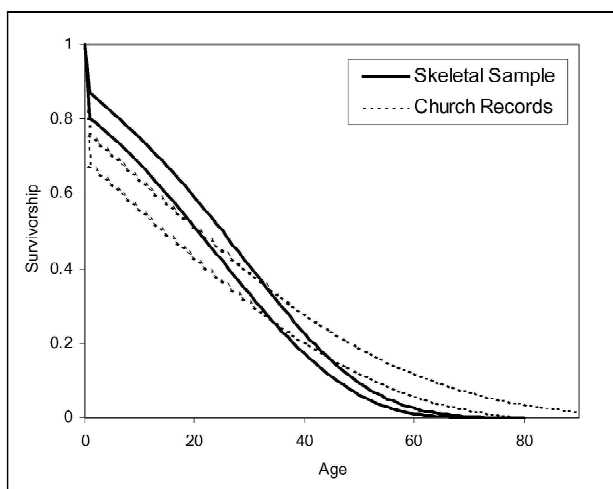


Figure E-3. Skeletal and Church Record Survivorships bounding one standard deviation around the parameter estimate.

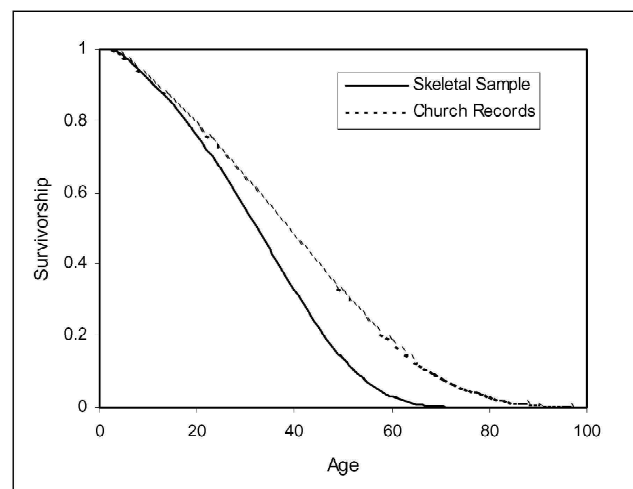


Figure E-4. Survivorship based on the reduced sample and from a two-parameter Gompertz Model of mortality.

Figure E-6 where the survivorship for Refugio individuals below ten is higher than this group at Capistrano. These differences do not hold for the adult parameters (α_3 and β_3), and the fit of the Siler models is not significantly different based on a Likelihood Ratio Test ($\Lambda = 1.35$, $p = .930$ d.f. = 4). The similarity in the mortality pattern at these

two missions is interesting and may suggest similar mortality hazards. Acknowledged factors from the historic records that may have contributed to deaths at these missions include pestilence, malnutrition, and hostile attacks. Thus, the mortality profile may reflect a general pattern of “Mission” mortality.

Table E-5. Parameter estimates of the Gompertz Model for sex-specific mortality for the skeletal sample from Refugio mission¹

Parameter	Males	Females
α	0.0041	0.0075
β	0.0764	0.0548
$\ln(L)$	-124.8	-86.1

¹ Likelihood Ratio Test: $\ln(L)$ combined samples -212.1, $\Lambda = 2.31$, $p = .315$, d.f. = 2

Table E-6. Parameter estimates of the Siler Model for the Refugio and San Juan Capistrano skeletal samples¹

Parameter	Refugio Sample	Capistrano Sample
μ_1	23.94	0.60
σ_1	144.39	2.60
μ_3	0.0136	0.0134
σ_3	0.0429	0.0396
$\ln(L)$	-394.1	-277.6

¹ Likelihood Ratio Test: $\ln(L)$ combined samples -772.4, $\Lambda = 1.35$, $p = .930$, d.f. = 4

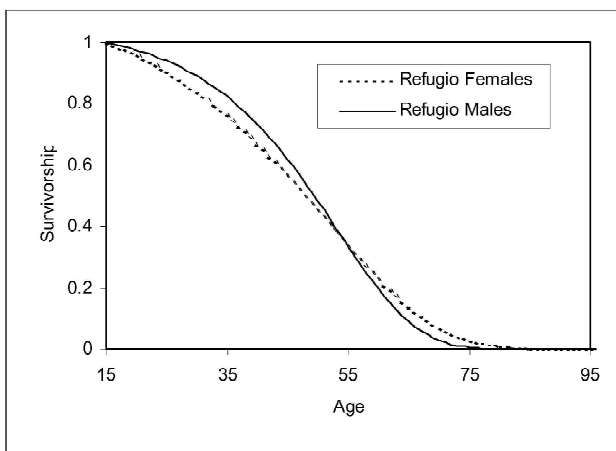


Figure E-5. Male and Female Survivorship derived from the skeletal sample from the Refugio Mission cemetery.

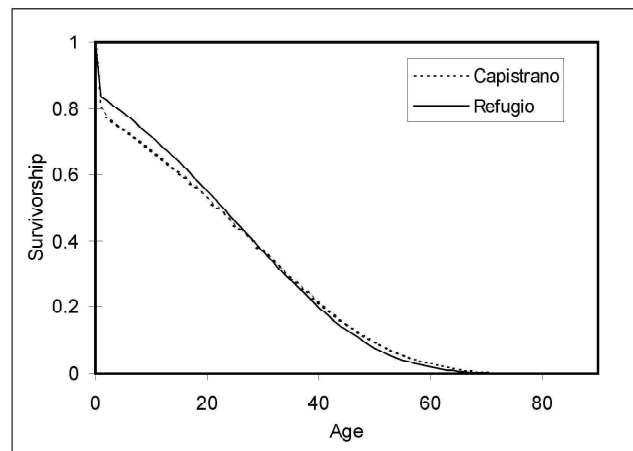


Figure E-6. Survivorship of the Refugio and San Juan Capistrano skeletal samples from a four-parameter Siler Model of mortality.

Discussion

In addition to the demographic reconstruction and comparisons, the Burial Records from the Mission Documents (Oberste 1942) and 1810 Census provide some very interesting insights into life at the Refugio mission. With these records we can compare mortality of various subsets of the populations including Native Americans to non-Native individuals and infants to non-infants. In addition, data concerning infant and seasonal mortality as well as traumatic deaths are available. Although these data are obviously deficient in providing a complete record of death at Refugio, the documents offer a general pattern of mortality.

Historical records describe variations in residence patterns of the Native American population at the mission (see Ricklis 1996:162-165). Ricklis found that various Karankawan groups would arrive at missions during certain periods of the year. As is evident from the burial record, a majority of Amerindians at the mission were Karankawan (see Table E-7). Ricklis suggests that these movements were associated with variations in the availability of food resources at the mission. In order to investigate this observation further, we tabulated annual and monthly mortality by Native and non-Native groups at the mission (Figures E-7 and E-8). Deaths of individuals recorded as Native American occur in all but two years: 1808 and 1818. Deaths of Amerindians are recorded in every month of the sixteen year period. In addition, Native American deaths are typically restricted to one or two months per year. It should be noted that deaths of individuals identified as Native American are limited in each year with a maximum of seven individuals in 1820

Table E-7. Native American groups identified in the burial records

Group Identification*	Count
<i>Coco/Paraque</i>	1
<i>Copan</i>	2
<i>Cujan</i>	6
<i>Karankawa</i>	23
<i>Karankawa/Copan</i>	1
<i>Karankawa/Cujan</i>	8
<i>Karankawa/Guapit</i>	1
<i>Karankawa/Paraque</i>	1
<i>Karankawa/Pihuique</i>	1
<i>Karankawa/Toboso</i>	1
<i>Lipan</i>	2
<i>Malaquiiit/Pahalachi</i>	1
<i>Toboso</i>	1
Native American	4
Total	53

**Italicized* names represent Karankawan tribal groups (Ricklis 1996).

and average only 3.3 deaths per year. The combined monthly pattern does not suggest a specific *seasonal* migration of the Karankawa population to and from the mission as Ricklis (1996:162-164) has suggested, but group movements are more than likely related to yearly variations in subsistence resources. Ricklis does point out that some groups did move to the mission during the fall and winter, possibly as a result of large coastal bands and over exploitation of coastal resources.

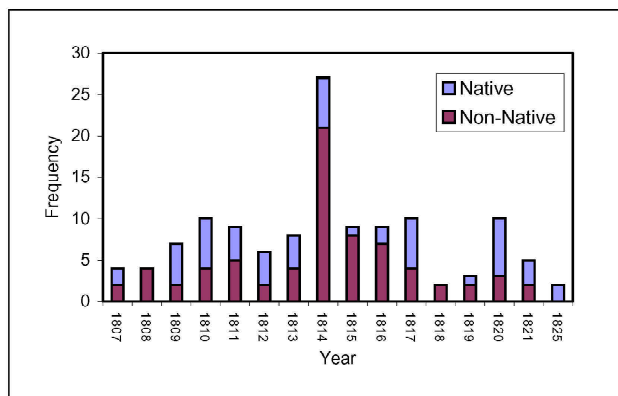


Figure E-7. Distribution of deaths at Refugio mission by year. No data available for 1822-1824.

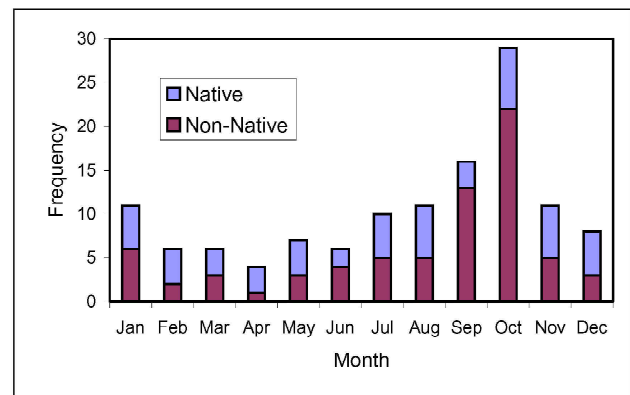


Figure E-8. Distribution of deaths at Refugio mission by month.

Infant mortality in the mission records is quite high with 48 of the 125 deaths (38 percent) representing individuals 3 years old or under. When we exclude the traumatic death individuals then infant death represents close to half (48.5 percent) of all deaths at the mission. At least one infant death was recorded in every year of the Burial Record, except 1809 (Figure E-9). From a monthly perspective, the pattern of infant deaths is high during the first three months of the year then gradually declines through the summer months (Figure E-10). Deaths then increase in September and remain constant throughout the rest of the year. A close inspection of the infant deaths listed in the record reveals that Amerindian infant deaths represent over half of all infant deaths (52.1 percent). The monthly pattern of Native

American infants death as compared to non-Native infant deaths varies considerably (Figure E-11). Overall frequencies are low, and the extreme fluctuations evident in the data are probably related to sampling error. We do see a marked increase in non-Native infant deaths throughout the fall and winter months, possibly suggesting a higher stress period for the resident Hispanic or European population.

The distribution of traumatic deaths is also an interesting avenue of investigation given the history of the mission and the high number of burials identified with evidence of perimortem trauma (Figure E-12). A total of 26 traumatic deaths are documented in the mission records (Oberste 1942). Fourteen of these deaths occurred on October 30,

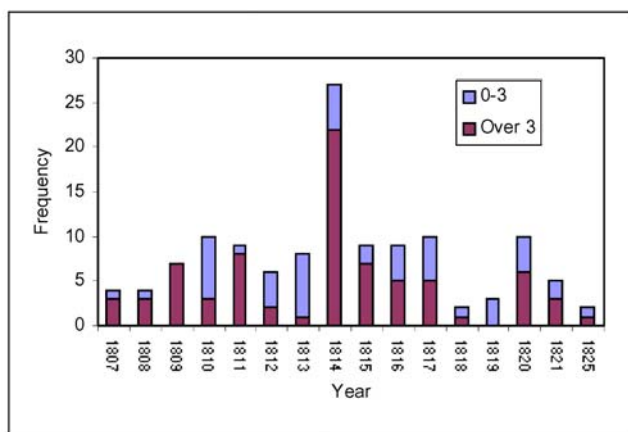


Figure E-9. Distribution of infant deaths by year.

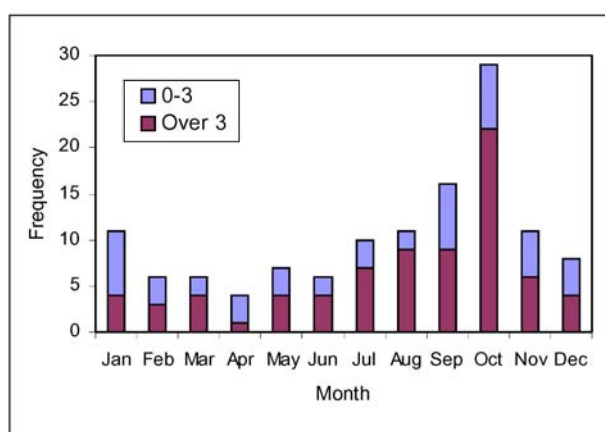


Figure E-10. Distribution of infant deaths by month.

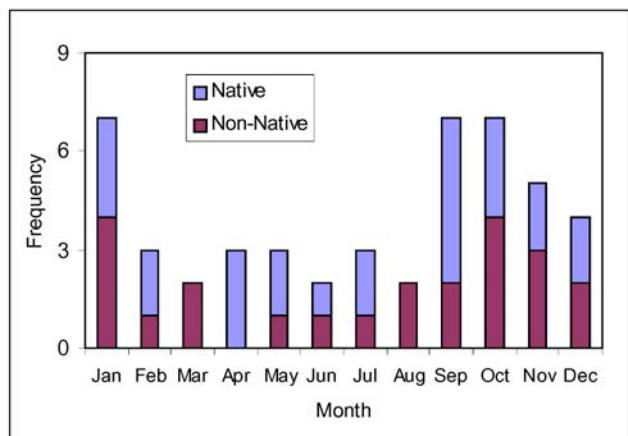


Figure E-11. Distribution of Native American and non-Native American infant deaths by month.

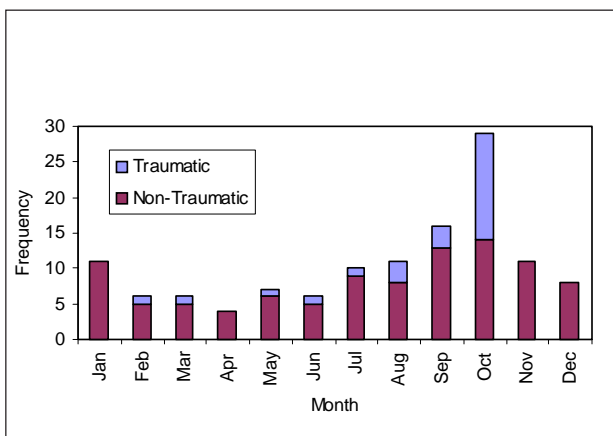


Figure E-12. Distribution of traumatic deaths by month.

1814, and are described in the record as killed on the ranch of the Diezmero on the banks of the Nueces by *Barbarian Indians*. These individuals skew the distribution of traumatic death, but there appears to be a slight increase in traumatic deaths during the late summer relative to the spring and early summer. This increased violence may relate to the availability of food at the mission or surrounding rancheros during the harvest period. No traumatic deaths are recorded during the winter months of November through January.

The distribution of non-traumatic deaths shown in Figure E-12 suggests a seasonal pattern in the mortality at the Refugio mission. Numerous tests are available in the epidemiological and statistic literature (Edwards 1961; Marrero 1983; Reijneveld 1990); however, a majority of these tests, especially the Edwards Test, are limited by sample size and susceptible to Type I errors due to small sample sizes (Marrero 1983). St. Leger (1976) presents a modification of the Edwards Test that uses a Likelihood Ratio Test to compare a fitted sine curve across the monthly distribution to a null hypothesis of an equal distribution of deaths (Table E-8). The Likelihood Ratio Test is significant indicating a marked seasonal pattern to the pooled mortality of the documented deaths at the Refugio mission. It should be noted that these are pooled data and yearly variation in mortality does not consistently conform to the seasonal pattern evident in the pooled data. In addition, annual and monthly variations in mission documentation may have contributed to the pattern evident. The seasonal mortality pattern evident at Refugio mission is possibly a reflection of the residential movement of the Karankawa groups (i.e., more deaths when the mission population was high). However, Ricklis (1996:163-165) found that Karankawa groups typically move to the coastal prairie missions in the

spring from March to May (11 of 16 documented arrivals) with a second peak during the fall to early winter. This residence pattern appears counter to the Refugio mortality data by suggesting low mortality when the mission population was supposed to be increasing based upon historical records.

Conclusions

The Refugio skeletal sample has provided a unique opportunity to compare skeletal data derived from a historically documented population. Due to a combination of confounding factors, the age-at-death distributions derived from the skeletal sample and the historic mission records are significantly different. Specific data concerning sex and adult to subadult ratios are similar suggesting that errors in age-at-death documentation, adult age estimation, and subadult underenumeration have contributed to the differences in the age-at-death distributions. Examined independently, each data set is quite informative. The pooled mission mortality data indicates:

- 1) A strong seasonal pattern with high mortality in the late summer through early winter; and
- 2) A consistent, annual Native American population.

The skeletal data suggests a similar mortality pattern for males and females with slightly greater female survivorship. The comparison to the San Juan Capistrano sample indicated a similar mortality profile for the two mission samples. This pattern may be related to similar mortality hazards faced by the living communities at small Spanish missions.

Table E-8. Likelihood Ratio Test for seasonality in mortality of the Refugio mission burial records using St. Leger (1976) method

Model	$\ln(L)$
$\ln M_1 = \sum_{i=1}^{12} N_i \ln \left(\left[1 + \hat{A} \sin(W_i + \hat{B}) \right] / 12 \right)$ <p>ML estimates: $A = 1$ and $B = 0$</p>	-340.44
$\ln M_0 = N \ln(1/12)$	-241.04
Likelihood Ratio Test: $-2(\ln M_0 - \ln M_1)$	$\Lambda = -198.8$ $p < .000001, \text{ d.f.} = 2$

Osteological Analyses

Section F Bone Pathology

This section is devoted to the description of the pathological changes observed in the Refugio skeletal series. The overall health of a population can be discerned from careful documentation of disease, degeneration, and/or trauma. While short-term disease episodes do not affect the skeleton, long-term infection or nutrient deficiencies do affect skeletal change in the form of bony development or loss. General categories are presented with specific discussion for disease processes. The results of the Refugio analysis are presented and compared to the results of Mission San Juan Capistrano Rooms 17 and 26. Due to the small samples in the San Juan series, significance tests were not conducted. For most of the results, frequencies are calculated using the number of the specific element observed. Section D provides the inventory counts for each element and joint surface. Finally, specific examples from Refugio are discussed.

Joint Diseases

Osteoarthritis

Osteoarthritis, a chronic inflammatory disease that frequently results in the destruction of weight-bearing joints, is the most common joint disease observed in archaeological human remains. The term, “osteoarthritis” refers to the condition of the destruction of hyaline cartilage-covered joints. The disease is associated with one or a combination of the following: aging, a genetic predisposition, obesity, activity level, and environmental factors. Osteoarthritis is characterized initially by the development of osteophytes or lipping on the margins of joints, pitting of the joint surfaces, and deformation of the joint contour. In the most severe cases eburnation on the joint surface can also occur. Osteoarthritis can be observed on any joint surface, however, it occurs most commonly on the hips and knees (Roberts and Manchester 1995:105).

The following tables (Tables F-1 through F-6) provide frequencies of joint surfaces that exhibit mild osteophytic lipping from the Refugio series and Rooms 26 and 17 from San Juan Capistrano. Tables F-2 through F-6 are long bone joints, while Table F-1 features all of the other non-vertebral joint surfaces. As expected, arthritic changes occur most often in the older adults. The most commonly affected region

is the knee including the distal femur and proximal tibia. The young adults in all samples exhibit mild arthritic changes infrequently.

Tables F-7 and F-8 detail the individuals that were coded for moderate or severe osteophytic lipping. One example of osteoarthritis on long bone joints is observed in a male, aged 30-35 years (41RF1-BP26-125). The right distal femur and proximal tibia exhibit moderate osteophyte development (Plate F-1).

Osteoarthritis (OA) is also documented in the vertebrae. Figure F-1 illustrates via bar graphs the frequency of any type of arthritic change in vertebrae for the adult age groups for the Refugio and San Juan Capistrano samples. The calculation of frequencies is based on the number of individuals that have any cervical, thoracic, or lumbar vertebrae present (Table F-9), and the number of individuals that have any type of OA recorded. While more precise inventories and pathology codes were taken, only general presence or absence was considered for this analysis. Possible pathological changes include lipping, porosity or eburnation. Cervical, thoracic, and lumbar vertebrae are presented by articular facets and centra. Pathological changes in the centra may represent osteophytosis, which is discussed in the next section.

The articular facets and the centra show an expected pattern of greater arthritic changes occurring in the older adults. Overall, Room 26 of the San Juan series exhibits higher frequencies of OA in the vertebrae. By sex and age group, the older females exhibit the greatest frequency of OA in the vertebrae. Comparison of the frequency across the vertebral class shows that lumbar vertebrae are prone to greater joint stress than the cervical or thoracic. Ankylosis of vertebrae occurs in all three rooms at a relatively low rate. Refugio includes a total of three individuals that exhibit fusion or ankylosis of vertebrae; two individuals exhibit ankylosis in the thoracic vertebrae (a male in each age group) and one older male exhibits ankylosis in the cervical vertebrae. The San Juan samples each have a single instance of ankylosis; an older female from Room 17 has ankylosis in the thoracic region, and an older male from Room 26 has ankylosis in the cervical region.

Table F-1. Mild osteoarthritic lipping by age and sex

SEX/ AGE	SAMPLE	TMJ			MANDIBLE			SCAPULA GLENOID			ACETABULUM			SACROILIAC			PATELLA			CALCANEUS			
		L	N	%	L	N	%	L	N	%	L	N	%	L	N	%	L	N	%	L	N	%	
Males 15-34	REFUGIO	11	0	11	0	21	0	19	10.5	20	0	17	0	14	0	13	0	9	0	19	5.3	13	7.7
	CAPISTRANO ROOM 17	5	0	3	0	6	33.3	2	0	1	0	2	0	3	0	3	0	2	0	2	0	2	0
	CAPISTRANO ROOM 26	5	0	5	0	3	0	4	0	6	0	7	28.6	8	12.5	5	0	6	0	3	33.3	3	0
Males 35+	REFUGIO	11	9.1	13	0	17	5.9	19	31.6	15	20.0	18	50.0	19	26.3	15	0	15	0	12	41.7	13	46.2
	CAPISTRANO ROOM 17	7	14.3	6	0	7	28.6	3	0	2	100.0	2	0	5	20.0	2	0	4	0	3	0	3	0
	CAPISTRANO ROOM 26	5	20.0	6	16.7	6	0	4	25.0	6	66.7	5	80.0	6	50.0	4	0	6	0	4	50.0	4	25.0
Females 15-34	REFUGIO	7	0	6	0	17	0	14	0	17	0	9	0	11	9.1	7	0	14	7.1	12	0	14	7.1
	CAPISTRANO ROOM 17	5	0	6	0	8	0	3	0	3	0	2	0	4	0	2	0	3	0	2	0	4	0
	CAPISTRANO ROOM 26	5	0	7	0	6	0	5	0	5	20.0	3	0	4	0	4	0	5	0	4	0	3	0
Females 35+	REFUGIO	6	16.7	6	0	9	0	11	27.3	10	10.0	6	33.3	8	37.5	5	20.0	7	14.3	7	42.9	5	40.0
	CAPISTRANO ROOM 17	3	0	4	25.0	7	14.3	2	0	2	0	3	100.0	3	100.0	3	0	3	0	3	1	1	0
	CAPISTRANO ROOM 26	2	0	3	33.3	3	0	3	66.7	4	75.0	2	0	2	0	2	0	2	0	3	33.3	4	50.0

Note: Refugio has 2 and Room 17 has 9 young adults of unknown sex unaffected by osteoarthritis.

Table F-2. Mild osteoarthritic lipping of the humerus by age and sex

SEX/ AGE	SAMPLE	PROXIMAL JOINT SURFACE				DISTAL JOINT SURFACE			
		L		R		L		R	
		N	%	N	%	N	%	N	%
Males 15-34	REFUGIO	20	0	20	0	24	16.7	20	15.0
	CAPISTRANO ROOM 17	4	0	2	0	4	0	5	0
	CAPISTRANO ROOM 26	6	0	7	0	6	0	8	0
Males 35+	REFUGIO	12	16.7	11	18.2	19	47.4	16	50.0
	CAPISTRANO ROOM 17	4	50.0	4	0	9	22.2	2	0
	CAPISTRANO ROOM 26	5	40.0	7	42.9	5	40.0	7	85.7
Females 15-34	REFUGIO	13	0	13	0	18	11.1	15	6.7
	CAPISTRANO ROOM 17	7	0	3	33.3	5	0	6	0
	CAPISTRANO ROOM 26	6	0	5	0	5	0	7	14.3
Females 35+	REFUGIO	3	33.3	4	25.0	11	9.1	11	45.5
	CAPISTRANO ROOM 17	3	0	1	100.0	3	66.6	2	50.0
	CAPISTRANO ROOM 26	3	33.3	5	0	4	75.0	4	25.0

Table F-3. Mild osteoarthritic lipping of the radius by age and sex

SEX/ AGE	SAMPLE	PROXIMAL JOINT SURFACE				DISTAL JOINT SURFACE			
		L		R		L		R	
		N	%	N	%	N	%	N	%
Males 15-34	REFUGIO	21	4.8	18	0	20	25.0	15	6.7
	CAPISTRANO ROOM 17	3	0	4	0	1	0	4	0
	CAPISTRANO ROOM 26	6	0	5	0	5	0	5	20.0
Males 35+	REFUGIO	18	11.1	16	6.3	13	53.8	14	28.6
	CAPISTRANO ROOM 17	3	33.3	3	66.7	3	0	5	40.0
	CAPISTRANO ROOM 26	6	33.3	7	28.5	5	20.0	7	28.5
Females 15-34	REFUGIO	16	0	16	0	15	0	14	0
	CAPISTRANO ROOM 17	2	0	3	0	2	0	5	0
	CAPISTRANO ROOM 26	5	0	5	0	6	0	5	0
Females 35+	REFUGIO	9	11.1	9	11.1	7	28.6	10	30.0
	CAPISTRANO ROOM 17	3	33.3	2	0	4	25.0	1	0
	CAPISTRANO ROOM 26	4	25.0	3	0	5	20.0	4	25.0

Table F-4. Mild osteoarthritic lipping of the ulna by age and sex

SEX/ AGE	SAMPLE	PROXIMAL JOINT SURFACE				DISTAL JOINT SURFACE			
		L		R		L		R	
		N	%	N	%	N	%	N	%
Males 15-34	REFUGIO	21	9.5	24	12.5	16	12.5	15	0
	CAPISTRANO ROOM 17	2	0	7	0	2	0	2	0
	CAPISTRANO ROOM 26	7	0	7	0	6	0	6	0
Males 35+	REFUGIO	18	50.0	20	45.0	13	7.7	14	21.4
	CAPISTRANO ROOM 17	6	33.3	3	66.6	3	0	2	0
	CAPISTRANO ROOM 26	6	33.3	7	85.7	4	50.0	7	42.9
Females 15-34	REFUGIO	20	0	16	0	11	0	8	0
	CAPISTRANO ROOM 17	8	0	6	0	3	0	3	0
	CAPISTRANO ROOM 26	9	11.1	4	25.0	5	0	3	33.3
Females 35+	REFUGIO	10	60.0	10	60.0	6	0	9	11.1
	CAPISTRANO ROOM 17	4	75.0	3	66.6	2	0	1	100.0
	CAPISTRANO ROOM 26	5	40.0	2	0	3	0	3	0

Table F-5. Mild osteoarthritic lipping of the femur by age and sex

SEX/ AGE	SAMPLE	PROXIMAL JOINT SURFACE				DISTAL JOINT SURFACE			
		L		R		L		R	
		N	%	N	%	N	%	N	%
Males 15-34	REFUGIO	28	0	25	0	22	13.6	22	9.1
	CAPISTRANO ROOM 17	3	0	4	0	3	0	5	0
	CAPISTRANO ROOM 26	9	0	6	0	8	25.0	8	12.5
Males 35+	REFUGIO	16	12.5	17	17.6	17	52.9	19	63.2
	CAPISTRANO ROOM 17	6	0	4	0	7	71.4	6	33.3
	CAPISTRANO ROOM 26	9	33.3	9	11.1	8	100.0	9	77.8
Females 15-34	REFUGIO	17	0	17	0	19	0	20	10.0
	CAPISTRANO ROOM 17	6	0	6	0	4	0	3	0
	CAPISTRANO ROOM 26	6	0	4	0	5	20.0	4	0
Females 35+	REFUGIO	10	10.0	9	22.2	10	60.0	9	77.8
	CAPISTRANO ROOM 17	3	0	4	25.0	2	100.0	4	0
	CAPISTRANO ROOM 26	2	50.0	3	33.3	4	50.0	3	33.3

Table F-6. Mild osteoarthritic lipping of the tibia by age and sex

SEX/ AGE	SAMPLE	PROXIMAL JOINT SURFACE				DISTAL JOINT SURFACE			
		L		R		L		R	
		Total	OA	Total	OA	Total	OA	Total	OA
Males 15-34	REFUGIO	20	5.0	21	4.8	23	0	23	0
	CAPISTRANO ROOM 17	3	0	4	0	4	0	4	0
	CAPISTRANO ROOM 26	7	14.3	7	14.3	4	25.0	7	14.3
Males 35+	REFUGIO	19	26.3	18	38.9	16	25.0	15	26.7
	CAPISTRANO ROOM 17	3	66.6	9	44.4	9	22.2	8	12.5
	CAPISTRANO ROOM 26	8	87.5	6	66.6	8	50.0	9	44.4
Females 15-34	REFUGIO	16	0	17	0	14	0	17	0
	CAPISTRANO ROOM 17	5	0	4	0	5	0	7	0
	CAPISTRANO ROOM 26	7	0	5	0	6	0	4	0
Females 35+	REFUGIO	8	25.0	8	12.5	9	22.2	7	14.3
	CAPISTRANO ROOM 17	2	0	2	0	2	0	2	0
	CAPISTRANO ROOM 26	4	50.0	2	100.0	4	25.0	3	0

OA is also documented in the sacrum at the promontory and the articular facets. Refugio and Room 26 each have a single young male that exhibits some arthritic change of this element. The occurrence of OA in the sacrum is predominately seen in the older individuals. All of the older females from Rooms 17 and 26 (3 and 1 respectively) exhibit OA. Two of the 9 older females from Refugio display arthritic change of the sacrum. Twenty to thirty percent of the older males from each sample exhibit some type of OA on the sacrum.

Table F-7. Refugio individuals that display moderate to severe osteophytic lipping

COMPID	SEX	AGE GROUP	JOINT SURFACE	SIDE	SEVERITY
41RF1-BP02-006	Female	35+	Humerus Distal	Left	Moderate
41RF1-BP02-015	Female	35+	Acetabulum	Left & Right	Moderate
41RF1-BP04-016	Male	35+	Patellar Facet	Right	Moderate
			TMJ	Right	Moderate
41RF1-BP04-018	Male	35+	Scapula Glenoid	Left	Moderate
41RF1-BP07-038	Female	35+	TMJ	Right	Moderate
41RF1-BP13-047	Female	15-34	Radius Distal	Left	Moderate
41RF1-BP15-081	Indet.	35+	Radius Distal	Right	Moderate
			Ulna Proximal	Right	Moderate
41RF1-BP17-090	Male	35+	Ulna Proximal	Left & Right	Moderate
41RF1-BP20-002	Poss. Male	35+	Acetabulum	Left & Right	Severe
			Radius Distal	Right	Severe
			Sacroiliac	Left & Right	Ankylosis
			Scapula Glenoid	Right	Moderate
			Ulna Distal	Left	Moderate
			Ulna Proximal	Right	Moderate
41RF1-BP22-116	Male	35+	Tibia Proximal	Right	Severe
41RF1-BP22-101R	Female	35+	Acetabulum	Right	Moderate
41RF1-BP26-119	Male	15-34	Femur Proximal	Right	Moderate
41RF1-BP26-120	Male	35+	Scapula Glenoid	Left	Moderate
			Ulna Proximal	Right	Moderate
41RF1-BP26-125	Male	15-34	Femur Distal	Right	Moderate
			Tibia Proximal	Right	Moderate
41RF1-BP26-126	Male	35+	Acetabulum	Right	Moderate
			Femur Proximal	Right	Moderate
41RF1-BP26-U01R	Poss. Male	35+	Ulna Proximal	Right	Moderate
41RF1-BP30-H01L	Indet.	35+	Humerus Proximal	Left	Moderate
41RF1-BP34-106A	Male	35+	Femur Proximal	Right	Moderate
41RF1-BP35-134	Male	15-34	Femur Distal	Right	Moderate
			Patellar Facet	Right	Moderate

Table F-8. San Juan Capistrano individuals that display moderate to severe osteophytic lipping

COMPID	SEX	AGE GROUP	JOINT SURFACE	SIDE	SEVERITY
41BX5-17-10A01	Male	35+	Sacroiliac	Left & Right	Ankylosis
41BX5-17-1202	Female	35+	Femur Distal	Left	Severe
			Femur Distal	Right	Moderate
41BX5-17-F12L	Male	35+	Femur Distal	Left	Moderate
41BX5-17-H16R	Male	35+	Humerus Proximal	Right	Moderate
41BX5-26-100	Male	35+	Femur Proximal	Left	Moderate
41BX5-26-11D	Male	35+	Ulna Distal	Right	Moderate
41BX5-26-1301	Male	35+	Scapula Glenoid	Left	Moderate
41BX5-26-16A01	Female	35+	Acetabulum	Left & Right	Moderate
41BX5-26-1701	Male	15-34	Femur Distal	Left	Severe
			Tibia Proximal	Left	Severe
41BX5-26-403	Male	35+	Acetabulum	Right	Moderate
			Scapula	Right	Moderate
			Glenoid	Right	Moderate
41BX5-26-705	Female	35+	Patellar Facet	Left	Severe
			Patellar Facet	Right	Moderate
41BX5-26-900	Male	15-34	Calcaneus	Left	Moderate
			Tibia Proximal	Right	Moderate

Table F-9. Number of individuals with vertebrae by age and sex

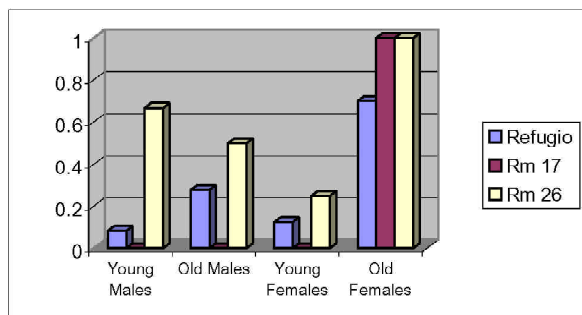
Age/Sex	Group	Cervical	Thoracic	Lumbar
Males 15-34	Refugio	24	33	27
	Room 17	3	3	2
	Room 26	7	5	7
Males 35+	Refugio	18	23	20
	Room 17	3	4	5
	Room 26	8	7	7
Females 15-34	Refugio	19	18	16
	Room 17	3	4	2
	Room 26	8	8	7
Females 35+	Refugio	10	11	10
	Room 17	3	4	2
	Room 26	2	3	4

Spinal Osteophytosis

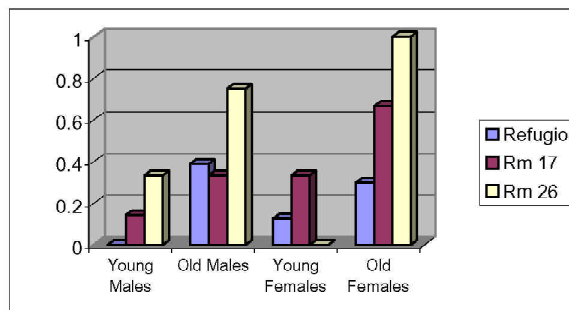
Spinal osteophytosis, or osteoarthritis of the vertebrae, is also seen frequently in archaeological human remains, especially in older individuals. The disease results in lipping, or osteophytes, developing on the vertebrae. Lipping develops first on the margins of the vertebral body, progressing to the posterior apophyseal joints and the transverse processes. The advanced stages of osteophytosis can result in the osteophytes from contiguous vertebra growing together and fixing spinal segments, a process

termed ankylosis (Roberts and Manchester 1995:107). Figure F-1 shows the frequencies of osteophytosis in the samples. The frequency increases as you move inferiorly from cervical down to lumbar vertebrae.

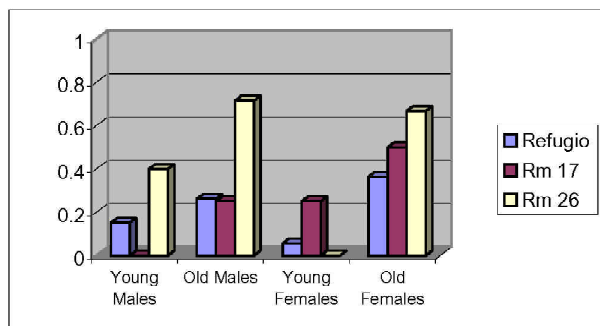
Osteophytosis is exhibited in a male, aged 55+ years (41RF1-BP22-116). The lumbar vertebrae have severe porosity of the endplates and margins of the centra. The margins also exhibit severe osteophytic lipping and expansion (Plate F-2).



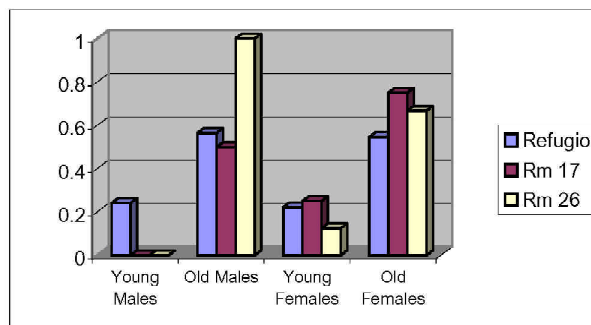
Cervical Facets



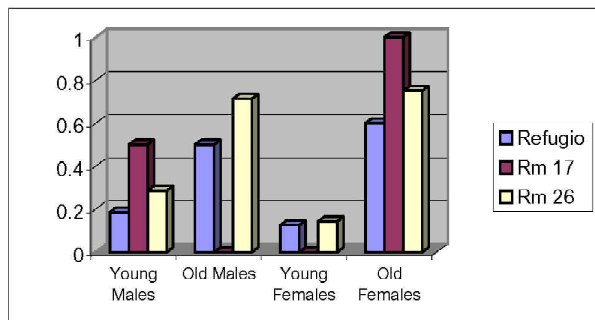
Cervical Centra



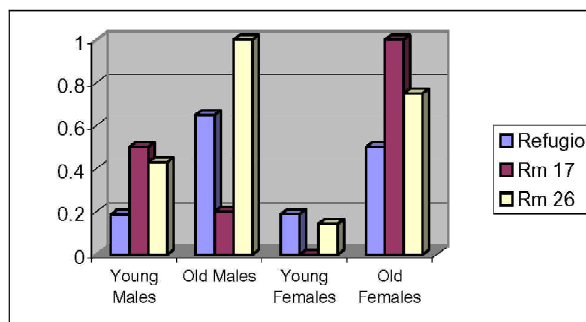
Thoracic Facets



Thoracic Centra



Lumbar Facets



Lumbar Centra

Figure F-1. Frequency of vertebral osteoarthritis and spinal osteophytosis by location.

Schmorl's Depressions

The degeneration of the intervertebral discs of the vertebrae and resulting osteophytosis are termed Schmorl's depressions. Schmorl's depressions occur at the site of pressure from the vertebral disc exerted on the vertebral body (Plate F-3). The Schmorl's depressions are usually located in the lower thoracic and lumbar vertebrae. The etiology of Schmorl's depressions is unknown, although their development has been associated with trauma in combination with an underlying infection that weakens the bone (Roberts and Manchester 1995:107). Figures F-2 and F-3 illustrate the frequency of Schmorl's depressions across the Refugio and San Juan rooms. Young adult males from Room 17 exhibit the highest frequency at 66 percent, which indicates that two of the three individuals that have thoracic vertebra are effected.

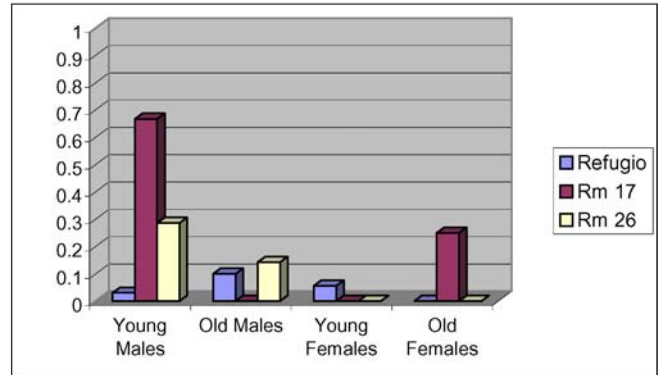


Figure F-2. Frequency of Schmorl's depressions in thoracic vertebrae.

The lumbar vertebrae exhibit the overall highest rates of occurrence. Room 17 exhibits the highest frequencies of all three groups. The least effected group is Refugio. This suggests that individuals from Room 17 were participating in activities that strained their backs more often than the individuals from Room 26 or Refugio. Room 26 is in the moderate range of the groups.

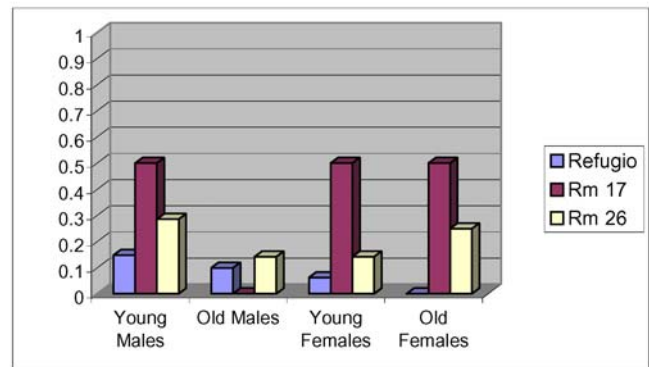


Figure F-3. Frequency of Schmorl's depressions in lumbar vertebrae.

Schmorl's depressions are present on the vertebrae of a male from Refugio, aged 45-60 years (41RF1-BP26-126). In this individual, five thoracic and three lumbar centra exhibit slight to moderate Schmorl's depressions (Plate F-3). Table F-10 presents the dimensions of the defects.

Table F-10. Dimensions of Schmorl's nodes recorded in 41RF1-BP26-126

Vertebra	Superior Surface		Inferior Surface	
	Length (mm)	Width (mm)	Length (mm)	Width (mm)
T6			10	4
T7	12	3		
T10			16	11
T11			24	11
T12	12	6	16	8
L1	24	15	16	10
L2 (?)			24	16
L5	13	8		

Enthesophytes

Enthesophytes are projections of bone in the form of spikes, spurs, and irregular ridges of ossification often occurring at muscle attachment sites. Common sites for enthesophytes are muscle attachment sites of the proximal ulna, radius, the iliac crest, ischial crest and tuberosities of the innominate, the femur along the linea aspera, trochanteric fossa, greater and lesser trochanters, tibia, and calcaneus. Enthesophytosis is associated with old age, obesity, or high activity level (Mann and Murphy 1990:72).

Figures F-4 and F-5 illustrate the distribution of enthesophytosis for males and females for Refugio and each of the San Juan series. These frequencies were calculated

using males and females of combined age groups and the total number of bones observed for each element. Males in all groups display an overall greater frequency of enthesophytic development than females. The most obvious pattern that occurs is the differences between males and females; males exhibit enthesophytosis in the bones of the lower legs and feet, whereas females have none in this region. While the frequencies are low, this is primarily reflecting the occurrence of the disease process in single individuals. Appendix IIC provides a list of the individuals and elements affected by enthesophytosis from Refugio and San Juan.

One instance of enthesophytosis is reported for a male, aged 40-44 years (41RF1-BP12-050). The lateral distal third of the tibial shaft has enthesophytic development as does the corresponding surface on the fibula (Plate F-4).

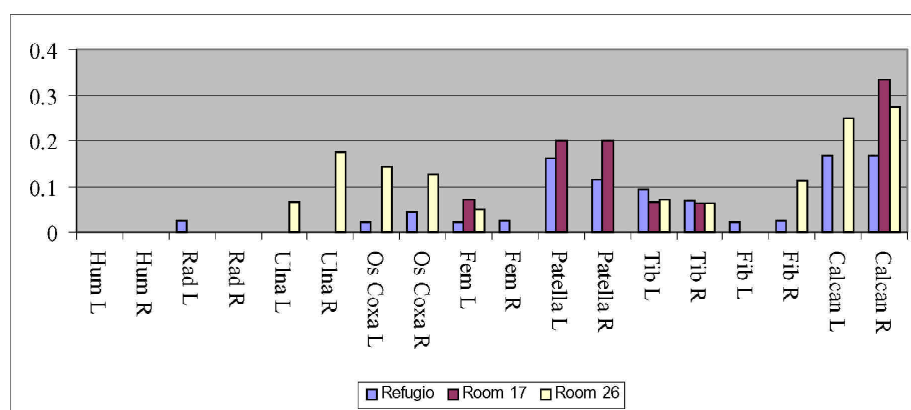


Figure F-4. Distribution of enthesophytosis in males.

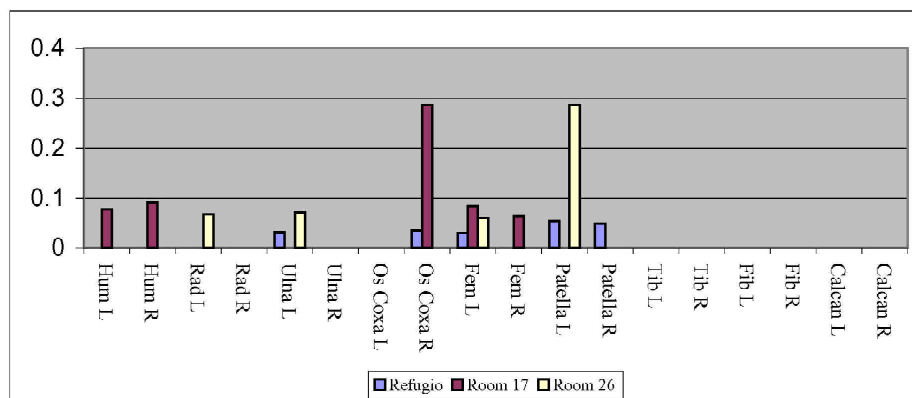


Figure F-5. Distribution of enthesophytosis in females.

Myositis Ossificans

Myositis ossificans is the ossification of muscle into bone. This is usually the result of trauma and inflammation of the muscle. The trauma associated with this condition almost inevitably has tendon or ligament involvement (Mann and Murphy 1990:113) Myositis ossificans is observed on a female, aged 40-44 years (41RF1-BP31-105). Myositis ossificans is present on the distal $\frac{1}{3}$ -shaft of the left femur (Plate F-5).

Dislocation

Dislocation occurs when there is a loss of contact between two osseous surfaces that are normally a joint. The cause of a dislocation may be congenital, traumatic, or the result of a disease. The hip and shoulder joints are the most commonly affected by dislocation. The recognition of a dislocation in an archaeological setting is difficult and requires that the joint was reduced or altered well before death occurred. Hip dislocations will sometimes result in the formation of a false or secondary acetabulum on the ilium. Congenital hip dislocation can be differentiated from traumatic hip dislocation due to the malformation of the acetabulum in the congenital dislocation. The acetabulum in a traumatic dislocation usually appears normal, with some possible new bone formation (Aufderheide and Rodriguez-Martin 1998:26).

Traumatic Dislocation

An unmatched os coxa identified as, 41RF1-BP26-I05R, a female, aged 20-29 years, provides a good example of a traumatically dislocated hip. The entire ilium exhibits healed severe osteomyelitis and deformation, all of which is most likely the result of a traumatic injury that occurred many years before death (see Osteomyelitis section for description). This injury resulted in fracturing of the ilium and dislocation of the hip joint. Orientation of the ilium is irregularly displaced laterally in a more horizontal plane. The lateral anterior edge of the perforation has a complete fracture and pseudoarthrosis. The original acetabulum shows nearly complete atrophy with only the central non-articulating surface remaining. The location of a secondary articulation is not clear. The bone remains dense and shows no evidence of osteoporosis or atrophy (Plate F-6).

Congenital Dislocation

Congenital dislocation of the hip is defined as the loss of the normal relationship between the femoral head and the acetabulum. The dislocation can result in the acetabulum becoming dysplastic and also in the deformation and flattening of the femoral head. There is a high degree of genetic inheritance associated with congenital hip dislocation. Females are affected five to eight times more frequently than males (Aufderheide and Rodriguez-Martin 1998:70).

The Refugio series has one case of congenitally dislocated hips, 41RF1-BP26-119, a male, aged 25-30 years. This individual displays a bilateral congenital dislocation of the hips. Both femoral heads have become flattened and oval shaped with the horizontal diameter of the head (left = 53 mm, right = 58 mm) greatly exceeding that of the vertical diameter (left = 42 mm, right = 46 mm). Both femoral necks are shortened, and the angle of the neck is close to 90 degrees. Malformation of this kind may be the result of repeated dislocation of the femoral head from the acetabulum during early childhood into adolescence. Degenerative changes associated with the dislocation include only slight marginal porosity on both femoral heads and moderate marginal osteophytic formation on the right femoral head. Although fragmentary, the acetabula also show modification of the lunate surface to accommodate the malformed femoral heads. Due to the fragmentary nature of the bone, the full extent of the modification cannot be assessed.

Infectious/Inflammatory Diseases

Treponematoses

Treponemal infections occur in four different diseases:

- 1) Venereal syphilis;
- 2) Endemic syphilis;
- 3) Yaws; and
- 4) Pinta.

Only the first three may affect the skeleton, and the bone lesions produced by the three diseases are so similar that diagnostic differentiation is complicated (Ortner and Putschar 1985). Often more than one bone is affected, with

the tibiae, bones surrounding the nasal cavity and the cranial vault affected the most. Lesions are characterized by an osteosclerotic response to the infection, including inflammation of the periosteum and/or bone (Ortner and Putschar 1985). The pathological process is one of gross destruction and irregular repair. Affected bones of the cranial vault have a worm-eaten appearance that has been termed caries sicca (Roberts and Manchester 1995). The response in postcranial elements includes osteomyelitis, hyperostosis, medullary osteosclerosis, periostitis, and lytic lesions (Ortner and Putschar 1985). In cases of congenital syphilis, osteomyelitis of the tibia produces the characteristic saber shin along with notched, or Hutchinson's, teeth, mulberry molars, and moderate to severe periostitis (Roberts and Manchester 1995). Five individuals from the Refugio series exhibited evidence of treponemal infections.

The first individual to be discussed is a child aged 11 to 14 years (code 14) possibly of Native American ancestry (41RF1-BP05-032). Hypoplastic defects are evident in eight teeth from this individual. The defects present in the first molars and incisors are located in the occlusal third of each crown and correlate to an age-at-insult between 1.5 to 2.5 years based on Wright's (1997) developmental standards for Maya. The mandibular premolars exhibit linear defects in the apical third of the crown that correlate to an age-at-insult between 5 and 5.5 years.

The first molars exhibit morphological characteristics consistent with "Mulberry molars" as described by Hillson et. al. (1998). The occlusal planes are dominated by severe hypoplasias, resulting in malformed cusps and dentin exposure. The hypoplastic defects consist of localized pits near the occlusal margin and linear field bands across the buccal surfaces (Plate F-7). Approximately 75 percent occlusal enamel is missing from all the first molars. These areas probably represent locations of defective and incomplete enamel that has fractured or quickly worn down due to normal mastication. The remaining crown and root development in the molar is normal.

The two lateral incisors, one mandibular and one maxillary, exhibit severe linear hypoplastic defects. In the maxillary incisor, the defect is near the incisal margin that has resulted in a reduced incisal diameter. Such a pattern is consistent with a Hutchinson's incisor (Hillson et. al. 1998), but this term is typically restricted to central incisors. In the mandibular incisor, the hypoplasia represents a wide field defect extending from the incisal third of the tooth to the middle of the crown. These defects have resulted in a reduced incisal diameter.

Various researchers identify Mulberry molars and Hutchinson's as classic dental stigmata of congenital syphilis (see Hillson et al. 1998 for a review). The dental defect present in this individual is consistent with these descriptions, but the age-at-insult between 1.5 and 2.5 years is later than typically documented in congenital syphilis cases (Hillson 1998:26). No postcranial skeletal elements are present, and no bone pathology is evident in the cranium.

The pathological characteristics of 41RF1-BP13-047, a probable female aged 25- 35 years, are indicative of congenital or endemic syphilis. General porosity is evident on the cranium. The pitting is restricted to the area between the temporal fascia extending from the posterior frontal squamous to the superior occipital squamous. The molars are characteristic Moon's molars, which are recognized by their small size in comparison to adjacent teeth and their unusual shape. The cusps are more centrally located on the occlusal surface, and constricted in size (Plate F-8). In addition the maxillary and mandibular incisors and canines show reduced occlusal areas, characteristic of Hutchinson's incisors (Jacobi et al. 1992). The crown exhibits numerous linear and pit hypoplasias and constriction of the incisal margin. This pattern is present in all the anterior dentition from this individual.

Evidence of congenital syphilis is present in a premature fetus (33 weeks gestational age), 41RF1-BP17-094. The long bones show pronounced thickening of the diaphyses due to formation of an abnormal layer of subperiosteal woven bone (Plate F-9). These changes are evident along the entire circumferences and lengths of the diaphyses. Postmortem loss of some of this woven bone allows direct measurement of the thickness of this layer relative to the underlying cortical bone. These thicknesses range between 1.8 to 2.8 mm. Medullary cavities are represented by small channels, due to internal apposition and stenosis. Even the ribs show subperiosteal bone formation. Changes observed in infant skeletons due to congenital syphilis include "multiosseous, usually symmetrical, circumferential deposition of subperiosteal bone on the shafts of long bones. The trabeculae of this bone deposit often show a radial arrangement" (Ortner and Putschar 1985:198-199).

The fourth case of possible treponemal infection is identified in 41RF1-BP17-090. This Native American male, aged 35-45 years, displays marked periosteal expansion on the femora, tibiae and to a lesser extent the fibulae. Activity in the femora is restricted to the distal third of the shafts. On the right side, periosteal lesions begin 5.5 cm distal from the midshaft. On the left femur, activity is present at 4.0 cm

distal from the midshaft. Activity in the tibiae is present on all shaft surfaces. Periosteal lesions in the fibulae are limited and are typically near the interosseous crest. In all cases, the lesions are healed, and the areas show sclerotic surface deposits or plaques. On both femora, surface apposition is well defined with approximately 1 to 2 mm of bony expansion from the original lamellar/periosteal surface. These lesions indicate a long-term systemic infection in this individual. The activity pattern is consistent with a treponemal infection (Plate F-9). However, cranial lesions (e.g., caries sicca) are absent.

Similarly, a fifth individual 41RF1-BP34-106B displays pathological alterations consistent with treponemal infection. The pathological alterations of the ulna and scapula of this young adult male are diagnostic of a treponemal infection (possibly syphilis). The ulna exhibits severe periostitis/osteomyelitis. The entire shaft of the bone is swollen by periosteal bony build up. The swelling is best appreciated by the measurements of the midshaft, 23 mm anterior-posterior (a-p) and 24 mm medial-lateral (m-l). Several rather large cloaca are present on the outer surface of the bone extending into the cortex of the cortical bone, appearing as scooped out regions, characterized by thin rough edges. The largest of these cloaca is located on the lateral surface, just posterior to the supinator crest. The defect measures approximately 15 mm (proximal-distal[p-d]) by 6 mm (medial-lateral [m-l]) and is 5 mm deep. Another cloaca, measuring 5 mm (p-d) by 3 mm (m-l) and 3 mm deep, is located on the posterior surface, just below the olecranon. Several defects are present on the anterior surface of the distal third of the shaft. The margins of these defects are smoother than the proximal defects, suggesting that these defects may be the result of small sequestra. The largest in this area measures 7 mm (p-d) by 3 mm (m-l) and 4 mm deep. Postmortem damage at this location provides a view of the medullary cavity. The cavity is almost completely obliterated by endosteal bone formation. While the shaft of the ulna has been greatly altered, the joint surfaces do not appear to have been affected (Plate F-11). Although the scapula is highly fragmented by postmortem damage, several fragments are clearly pathological. The blade exhibits several small lesions that have completely perforated the bone. The margins of these lesions are smooth and clearly the result of antemortem pathology. The fragmentary nature of the element prohibits dimensional measurements of all but one of the lesions. A lesion located at the junction of the lateral border and the blade measures 9 mm (p-d) by 4 mm (m-l). The lesions are very similar to those displayed in Ortner and Putschar (1985:196).

Osteomyelitis

Osteomyelitis is an infection and inflammation of the compact and cancellous bone that can occur following trauma or infection of soft tissue or bone. The pathological process of osteomyelitis is one of bone destruction with pus formation and simultaneous bone repair resulting in enlarged or swollen bones that are deformed from their normal state (Roberts and Manchester 1995). The bone destruction includes pitting and irregularity of the bone surface with formation of cloaca. The bone repair process includes the formation of bony plaques on the cortical surface.

Osteomyelitis was observed in five individuals in the series. For all but one of the individuals, infection was the result of fractures. The osteomyelitis exhibited by individual 34-106B is the result of a treponemal infection (see description in Treponematoses section). The osteomyelitis displayed by 41RF1-BP26-111 is the result of a fracture caused by osteoporosis (see Osteoporosis section for complete description).

Another example of trauma induced osteomyelitis is 41RF1-BP17-078, an adult male age 30-34 of possible Native American ancestry. Severe osteomyelitis is present on one left rib (#'s 3-10), most likely resulting from a previous fracture, or series of fractures. The lesion is widespread on the rib with nine cloacae present (seven located plural side, two exterior side) and signs of moderate healing (Plate F-12).

Similarly, an adult female, aged 35 to 44 years, of Native American ancestry (41RF1-BP24-068), displays osteomyelitic response to a fracture. The distal articular facet of the left third metacarpal is fractured and exhibits evidence of infection. An osteomyelitic reaction extends from the fracture along the shaft. A small fistula (2 mm in diameter) is present along the fracture line, and bony changes related to the osteomyelitic infection are present on the co-lateral metacarpal (second and fourth) (Plate F-13).

An unmatched right os coxa, 41RF1-BP26-I05R, including a small portion of the sacrum fused at the sacroiliac joint displays evidence of infection (element discussed in the Dislocation section). Hypertrophic bone is present on the medial and lateral surfaces. The cortical surface on the medial side is smoother and undulating with several cloaca present. The largest cloaca perforates the ilium and measures 9 mm x 6 mm. The lateral surface exhibits moderate porosity

and irregularity. A large oval shaped perforation with smoothed edges is located superior to the acetabulum and measures 31 mm x 13 mm. The lateral anterior edge of the perforation has a complete fracture and pseudoarthrosis.

Periostitis

Periostitis is an inflammatory reaction of the periosteum that results in the production of new bone along the outer surface. The periosteum is a thin layer of connective tissue that covers the bones of the skeleton, the inner layer of which is capable of producing new bone. The osseous manifestation of bone production is called periostitis. Bone production can be stimulated by a number of conditions including trauma, fracture of adjacent hard tissue, or infection (Roberts and Manchester 1995). The severity of the periostitis is determined by a combination of factors, including the type and severity of the injury, duration of the disease, host defense, and involvement of infectious agents. Periostitis is expressed in the skeleton as bony lumps on the bone cortex, most often on the long bone diaphyses of the leg (i.e., tibia and femur). These shafts will appear thickened or swollen, reflecting a severe or long-term inflammation of the periosteum. Periosteal new-bone formation is usually covered with pits and striations

where the affected areas are undergoing vascularization and repair (Mann and Murphy 1990).

Table F-11 gives the frequencies of periostitis present on the long bones in the Refugio series and Rooms 26 and 17 from San Juan Capistrano. As anticipated periostitis occurs most frequently in older adults in all of the series. Periostitis is recorded most often in the lower limbs in all of the populations. Examples of periostitis observed in the Refugio series are seen in Plate F-14.

Sinusitis

Bacterial infection in the nasal sinuses or dental abscesses can cause sinusitis of the maxillary sinuses. In dry bone, sinusitis manifests as irregular pitting and new bone formation on the interior surface of the sinuses (Roberts and Manchester 1995). Often the new bone growth forms a plaque like covering and/or bony spicules on the interior sinus surface.

Sinusitis was observed in four individuals in the series, 41RF1-BP04-016, 41RF1-BP09-042, 41RF1-BP15-052, and 41RF1-BP17-090 (Plate F-15).

Table F-11. Frequency of periostitis on long bones for adults by sex and age

SEX/ AGE	SAMPLE	HUMERUS				RADIUS				ULNA				FEMUR				TIBIA				FIBULA			
		L	R	L	R	L	R	L	R	L	R	L	R	L	R	L	R	L	R	L	R	L	R	L	R
Males 15-34	REFUGIO	24	0	24	0	23	0	20	0	23	0	21	0	27	3.7	30	0	24	8.3	25	4.0	25	8.0	22	4.5
	CAPISTRANO ROOM 17	7	0	6	0	3	0	3	0	2	0	7	0	5	0	8	0	5	0	5	0	4	50.0	5	20.0
	CAPISTRANO ROOM 26	7	0	8	0	8	0	7	0	9	0	7	0	11	0	9	0	6	16.6	8	12.5	5	0	10	0
Males 35+	REFUGIO	18	0	16	0	17	0	15	0	20	0	18	0	19	10.5	21	9.5	19	21.1	19	36.8	18	16.7	18	11.1
	CAPISTRANO ROOM 17	11	0	5	0	4	0	7	0	6	0	4	0	9	22.2	7	14.3	10	20.0	11	0	7	28.6	6	0
	CAPISTRANO ROOM 26	6	0	9	11.1	8	0	8	0	6	16.6	10	0	9	22.2	11	9.1	8	37.5	8	37.5	10	20.0	8	25.0
Females 15-34	REFUGIO	22	0	19	0	24	0	18	5.6	22	0	18	0	23	0	23	4.3	20	5.0	21	9.5	20	5.0	17	5.9
	CAPISTRANO ROOM 17	10	0	9	0	5	0	6	0	8	12.5	7	0	9	0	9	0	6	16.6	8	12.5	4	25.0	6	16.6
	CAPISTRANO ROOM 26	9	0	10	10.0	9	0	9	0	9	0	7	0	8	0	7	0	8	12.5	8	12.5	9	0	9	0
Females 35+	REFUGIO	10	0	10	0	10	0	10	40.0	10	0	10	0	11	9.1	12	16.6	11	18.2	10	20.0	10	10.0	10	10.0
	CAPISTRANO ROOM 17	3	0	2	0	4	0	3	66.6	4	0	3	0	3	0	7	0	2	0	2	50.0	4	0	3	33.3
	CAPISTRANO ROOM 26	5	40.0	5	0	6	0	5	20.0	5	0	3	0	4	0	3	0	4	25.0	3	0	6	33.3	3	33.3

Metabolic Diseases

Cribra Orbitalia

Cribra orbitalia appears as small (0.5 mm) to large (2.0 mm) pits in the orbital plates (Roberts and Manchester 1995). Cribra orbitalia can be accompanied by pitting and/or thickening of the outer table of the skull (ectocranial porosis/porotic hyperostosis). The etiology of this condition is under considerable debate, although most researchers attribute it to iron deficiency anemia. Factors considered to cause, contribute, and/or affect the severity of this condition include malnutrition, scurvy, epidemic disease, parasite infestation, and the heterozygous adaptation to malaria and sickle cell (Stuart-Macadam 1985; Mann and Murphy 1990).

Cribra orbitalia was present in seven individuals in Refugio, four in Room 17 and four in Room 26 from San Juan Capistrano (Table F-12). One of these individuals, 41RF1-BP22-112, a young adult male, also suffered from multiple pathological processes, most notably multiple antemortem fractures as well as porotic hyperostosis. Of the remaining Refugio individuals exhibiting cribra orbitalia, four are juveniles, one is a young child, and one is a young adult. The individuals from San Juan Capistrano exhibiting cribra orbitalia are all adults. This may be an artifact of the selection process during the analysis of the San Juan series. Moderate cribra orbitalia is present bilaterally in individual 41RF1-BP05-034. This child, aged 9 to 12 years, exhibits spicule development in the central portion of the supraorbital plate.

The left orbit appears more severe than the right, however both sides are fragmentary. Similarly, slight cribra orbitalia is evident on the orbital roof of individual 41RF1-BP16-83A. The orbital roof area is expanded and displays slight porosity (Plate F-16).

Porotic Hyperostosis

Porotic hyperostosis appears as lesions of porous periosteal bone deposition on the cranial vault and orbital plates (Ortner and Putschar 1985). The etiology of porotic hyperostosis is unknown. Several morbid conditions have been proposed as the cause including anemia, rickets, chronic infection, and other general nutritional deficiencies (Ortner and Putschar 1985). Two individuals displayed porotic hyperostosis, 41RF1-BP14-051 and 41RF1-BP22-112.

The cranial vault of a child, aged 2.5-3.5 years, possibly of Native American ancestry (41RF1-BP14-051), exhibits several areas of pathological changes. The posterior parietals exhibit porotic hyperostosis. The right posterior parietal along the lambdoidal suture approximately 40 mm lateral of lambda exhibits an area of porosity that measures approximately 18 mm (a-p) and a minimum of 16 mm (m-l). A more accurate measure of the breadth is prevented due to postmortem breakage. The left posterior parietal adjacent to asterion also exhibits a small region of thickening and porosity typical of porotic hyperostosis. This area measures approximately 14 mm by 13 mm. The left temporal exhibits slight widespread ectocranial porosis.

Table F-12. Individuals exhibiting cribra orbitalia

COMPID	SEX	AGE	SEVERITY
41RF1-BP05-034	Indeterminate	9.5-10.5	Moderate
41RF1-BP16-083A	Female	18.5-19.9	Mild
41RF1-BP17-071	Indeterminate	2.5-3.5	Mild
41RF1-BP20-002	Male	60+	Moderate
41RF1-BP22-112	Male	16.5-17.5	Mild
41RF1-BP26-104	Indeterminate	10.5-11.5	Mild
41RF1-BP26-119	Male	25-29	Mild
41BX5-17-1600	Male	35-39	Mild
41BX5-17-200	Male	20-24	Moderate
41BX5-17-400	Female	30-34	Mild
41BX5-17-701	Male	55-59	Mild
41BX5-26-16F	Male	20-24	Mild
41BX5-26-1701	Male	30-34	Moderate
41BX5-26-402	Female	25-29	Mild
41BX5-26-700	Female	25-29	Mild

Another individual, 41RF1-BP22-112, a Native American male aged 16 to 19 years, displays bilateral slight cribriform orbitalia and porotic hyperostosis. The anterior margins of the orbits exhibit mild porosity with slight bony expansion. Slight expanded areas of porous bone are present on both parietals near the lambdoidal suture superior to the temporal line. On the left parietal, slight surface porosity extends along the temporal line to the coronal suture. The maxillae and zygomatics exhibit active surface porosity. The zygomatics exhibit porosity on the orbital and external surface with slight bony expansion near the infraorbital canals and the zygomatico-orbital foramen (Plate F-17).

Osteoporosis

Osteoporosis is a common skeletal metabolic disease. Osteoporosis manifests as generalized reduction in total bone volume due to thinning of cortical bone, loss of trabeculae, and increased porosity of cancellous bone (Burr and Martin 1989). Age and sex are common correlates of the condition, with older females being at higher risk. Poor diet and nutrition have also been linked to the condition (Roberts and Manchester 1995). The loss of bone mass often leads to fractures (both macroscopic and microscopic) of the bones. Fractures of the wrist, hip, and compression fractures of the vertebral bodies are the most common (Roberts and Manchester 1995). Osteoporosis was noted in four individuals in the Refugio series, 41RF1-BP04-016, 41RF1-BP22-117, 41RF1-BP26-111, and 41RF1-BP26-I05R.

The most severe case of generalized osteoporosis was seen in a female, aged 60+ years, of probable Native American ancestry, 41RF1-BP26-111. The skeletal elements exhibit a suite of pathological alterations. The majority of the alterations are a direct result of age related degeneration, notably osteoporosis and arthritis. This individual displays generalized osteoporosis, as indicated by extreme thinning of the trabecular and cortical bone resulting in light and fragile bones. The extent of the osteoporosis can be appreciated in the near total degeneration of trabecular bone in the diaphyses and epiphyses of the long bones.

The right femur exhibits two distinct fractures. The proximal femur has a healed fracture to the neck region. This fracture is likely a result of weakening of the bone due to osteoporosis. The fracture resulted from a collapsing of the femur neck. This collapsing of the neck lead to compression and deformation of the greater and lesser trochanters and displaced the entire proximal end of the femur posteriorly

at an angle of approximately 15 degrees off vertical. The bone healed in this compressed and deformed state. The deformation of the lesser trochanter has extended and pulled the lesser trochanter lateral and anterior, creating a fossa (approximately 8 mm deep) between the proximal shaft and lesser trochanter. The fracture did not lead to any appreciable deformation of the femoral head, and the acetabulum is too fragmentary to reveal any evidence of deformation.

The distal third of the femur also has a fracture. The fracture itself can not be appreciated due to resulting osteomyelitis and postmortem damage to the distal third of the shaft. The shaft in the area of the infection is considerably swollen, and the bone is extremely porous and remodeled. The infection can also be appreciated on the rest of the shaft as periostitis and porosity. A cloaca, 4 mm in diameter, is present on a fragment located on the posterior surface of the shaft, indicating that the infection was active and draining at the time of death. The bone in the area of the fracture and infection was obviously unstable and likely immobilized the leg.

The fractures to the right femur appear to have affected the other leg elements. The right tibia and fibula are generally smaller than the left elements, suggesting that the muscles and bones had atrophied likely from non-use (Plate F-18).

Neoplastic Diseases

Multiple Myeloma or possibly Metastatic Carcinoma

Myeloma is a highly malignant tumor of plasma cells, arising in an area of hemopoietic bone marrow that in time can involve extensive portions of the skeleton. Males are more frequently affected than females, and the condition rarely occurs in individuals less than 40 years of age (Ortner and Putschar 1985).

Burial 41RF1-BP20-002 represents an old adult probable male, age 60+, of European or non-Native American ancestry. Numerous pathological lesions are evident in this individual. The pattern of lytic lesions is consistent with a relatively rare hemopoietic disorder, *Multiple Myeloma* (MM) or possibly metastatic carcinoma. Numerous lytic lesions develop in the bone marrow spaces, gradually enlarge, and destroy the surrounding bone. Multiple small

cavitations are evident on the endosteal surfaces and cortical cross-sections of all major long bones. The osteolytic defects exhibit no marginal osteoblastic reaction. Typically, this pattern of osteoclastic reactions is associated with MM, or possibly metastatic carcinoma (given the variation in lesion size). The distribution of the lytic defects is consistent with this description. Scalloped areas and small cavitations are present on the endosteal surface of the humerus, radius, ulna, proximal femur, tibia, and fibula. The vertebral and rib elements are extremely fragmented, and presence of lesions on these elements is unknown. Defects in the right humerus are large, with a maximum diameter of approximately 35 mm. Cavitations evident on the radiographs of the other long bones are smaller with diameters ranging from 2 to 20 mm. Two to three possible defects are visible in the radiograph of the fragmentary cranial material. These lesions are restricted to diploë and have not expanded to the ecto- or endo-cranial bone layers (Plate F-19).

Other Diseases

Bilateral Osteochondritis Dessicans

Osteochondritis dessicans is a benign, non-inflammatory condition of young adults characterized by areas of small necrosis on epiphyseal joint surfaces, resulting in partial or complete detachment of a segment of the subchondral bone and articular cartilage (Aufderheide and Rodriguez-Martin 1998). Osteochondritis dessicans most commonly affects individuals between the ages of 10 and 25 years, and males are more likely affected than females, though a number of cases have been observed in middle-aged and elderly females (Aufderheide and Rodriguez-Martin 1998). A consequence of osteochondritis dessicans can be the early onset of degenerative joint disease (DJD), which may be accelerated in athletes or highly active individuals (Aufderheide and Rodriguez-Martin 1998). Lesions are most commonly found on the medial femoral condyle, followed by the talus and elbow joint, although any other joint can be affected. Initially a small area of necrosis forms on the convex surface of the joint. Eventually the lesion's roof may become detached to become a loose body in the joint (Aufderheide and Rodriguez-Martin 1998). This exposes a crater in the cancellous bone which will eventually be lined with a new layer of bone as the defect heals (Ortner and Putschar 1985).

Within the Refugio series, one individual (41RF1-BP02-015) was noted to have bilateral osteochondritis dessicans on the distal femora. This individual, a Native American

female aged 60+ years, displays healed lesions on the medial condyles (Plate F-20).

Ectocranial/Endocranial Porosis

Ectocranial porosis manifests in tiny pits in the outer vault without increased vault thickness. This condition is fairly common in most populations. The etiology of this condition is unknown (Mann and Murphy 1990). This condition was noted in 19 individuals of various ages and sexes from Refugio. Table F-13 provides the specific cranial bone affected as well as the state of the porosis. Males are affected more frequently than females (53 percent and 37 percent, respectively, while 10 percent are of unknown sex). Nine of the individuals affected exhibited healed lesions, while the remaining ten displayed active ectocranial porosis. Table F-14 provides the individuals from Rooms 17 and 26 from San Juan Capistrano that were coded for this pathological condition. All of the affected individuals are males from San Juan rooms, and only two of the six individuals display evidence of healing.

Endocranial porosis appears as tiny areas of microporosity that often reflects inflammation in the outer table of the skull. This uncommon finding has an unknown etiology (Mann and Murphy 1990).

Only one instance of endocranial porosis was noted in the Refugio series, in a male aged 30 to 35 years (41RF1-BP26-125). The left temporal exhibits endocranial porosity or possibly lytic activity in the area of the mandibular fossa and just anterior to the mandibular fossa. Endocranially, the bone has a dimpled porous appearance in this area where bone has been lost. This bone loss has resulted in postmortem breakage of the exterior surface of the bone.

Nonosseous Tarsal Coalition

Nonosseous tarsal coalition appears as articular surface defects of the third metatarsal and third cuneiform. The defect ranges from a smooth pit to a very large depression on both elements. Tarsal coalition occurs when two adjacent bones fail to completely separate during development of the joint (Regan et al. 1999). This condition was noted in a female aged 30-34 years of Native American ancestry (41RF1-BP05-036). The coalition consists of a small (2 mm) defect on the plantar margin of the anterior/proximal cuneiform and posterior/distal metatarsal.

Table F-13. Individuals from Refugio with ectocranial porosis

Burial	Sex	Age	Bone	Side	State
41RF1-BP05-017	Female	20-24	Occipital		Active
			Parietal	Left & Right	Active
41RF1-BP05-039	Male	20-24	Frontal		Active
			Parietal	Left & Right	Active
41RF1-BP13-047	Female	25-29	Parietal	Left	Active
41RF1-BP13-057	Male	25-29	Frontal		Healed
			Parietal	Left & Right	Healed
41RF1-BP14-049	Indeterminate	1.5-2.5	Frontal		Active
			Temporal	Left & Right	Active
41RF1-BP14-051	Indeterminate	2.5-3.5	Temporal	Left	Active
41RF1-BP16-060	Male	25-29	Parietal	Right	Active
41RF1-BP16-072	Female	17.5-18.5	Parietal	Right	Active
41RF1-BP16-083	Male	35-39	Parietal	Left	Active
41RF1-BP16-093	Male	35-39	Occipital		Active
			Parietal	Left & Right	Active
41RF1-BP21-076	Female	30-34	Parietal	Right	Healed
41RF1-BP22-001	Female	20-24	Occipital		Healed
			Parietal	Left & Right	Active
41RF1-BP22-082	Male	35-39	Occipital		Healed
			Parietal	Left & Right	Healed
41RF1-BP22-107	Male	20-24	Frontal		Healed
			Occipital		Healed
			Parietal	Left & Right	Active
41RF1-BP22-109	Female	30-34	Parietal	Left & Right	Active
41RF1-BP22-129	Male	15.5-16.5	Frontal		Healed
41RF1-BP26-111	Female	60+	Mandible		Active
			Maxilla	Left	Active
			Occipital		Active
			Parietal	Left & Right	Active
			Temporal	Left & Right	Active
			Zygomatic	Left & Right	Active
41RF1-BP26-119	Male	25-29	Parietal	Left & Right	Active
41RF1-BP34-106A	Male	50-54	Frontal		Active
			Parietal	Left & Right	Active
41BX5-17-101	Male	35-39	Parietal	Left & Right	Healed
41BX5-17-10A03	Male	45-49	Frontal		Active
			Occipital		Active
			Parietal	Left & Right	Active

Table F-14. Individuals from San Juan Capistrano with ectocranial porosis

Burial	Sex	Age	Bone	Side	State
41BX5-17-12C01	Male	45-49	Frontal		Active
			Occipital		Active
			Parietal	Left & Right	Active
41BX5-26-404	Male	20-24	Frontal		Active
			Parietal	Left & Right	Active
41BX5-26-1605	Male	25-29	Frontal		Active
			Parietal	Left	Active
41BX5-26-16C01	Male	25-29	Occipital		Healed
			Parietal	Left & Right	Healed
41BX5-26-1201	Male	30-34	Occipital		Healed
			Parietal	Right	Healed
41BX5-26-801	Male	45-49	Occipital		Active

Brachymetacarpia and Brachymetatarsia

Brachymetacarpia and brachymetatarsia are abnormally short metacarpal and/or metatarsal elements in comparison to the other metacarpal and/or metatarsal elements. This condition was noted in one individual in the Refugio series.

A female, 41RF1-BP17-086, age 34-39 years of Native American ancestry, exhibits bilateral brachymetacarpia and brachymetatarsia of the 1st, 4th, and 5th metacarpals and the 4th metatarsal. Table F-15 provides the dimensions of the metacarpals and metatarsals. The right 5th metatarsal is shortened but the left element is normal. These elements are short in comparison to the other rays. Plate F-21 shows the shortened elements. The distal articular ends of the metatarsals are flattened and irregular in the shortened bones. Immature fusion of the distal epiphysis may have reduced the overall length of these elements. The middle phalanges of the 4th and 5th digits are also reduced as compared to the middle phalanges of the 2nd and 3rd digits (Plate F-21). The expression of this disorder is highly variable in a Japanese sample from Nagoya, Japan (Takayuki et al. 1986). The pattern of reduction seen in this burial is consistent with only one individual from the Japanese study. Recent research by Cervantes and colleagues (1988) suggests that this disorder is frequently associated with individual of familial short stature.

Table F-15. Measurements of the hand and foot bones (in mm) of 41RF1-BP17-086

Element	Left	Right
MC1	28.0	28.0
MC2	53.5	55.0
MC3	53.0	52.0
MC4	34.0	34.0
MC5	30.0	30.0
MT1	51.5	52.0
MT2	59.0	--
MT3	55.0	--
MT4	42.0	41.0
MT5	51.5	43.0

Trauma

Antemortem Trauma

Spondylolysis

Spondylolysis is the separation of the neural arch from the vertebral body. The cause of spondylolysis is unknown, although genetic, congenital, or trauma may all be factors associated with the condition. Merbs (1996) suggests that the defect is traumatically induced; whereas, other researchers have suggested a significant genetic component (Stewart 1956; Lester and Shapiro 1968). The most common location of spondylolysis is the lower two lumbar vertebrae (Mann and Murphy 1990:53). Table F-16 lists the individuals from Refugio and San Juan Capistrano affected by spondylolysis. Three of the five individuals from Refugio are males, and six of the seven individuals total are in the third decade of life.

Several cases of spondylolysis were observed in the Refugio series including, 41RF1-BP21-069. This individual, a male aged 35-40 years, has spondylolysis of the fifth lumbar vertebra. The posterior neural arch is completely separated through the lamina from the pedicles and transverse processes. The separation has resulted in compression of spinous process the fourth and fifth lumbar vertebrae. The inferior margin of the fourth spinous process has created an articular facet on the superior surface of the fifth. The angulation of the separated neural arch is almost perpendicular to the spine. The loose articulation between the fifth lumbar and first sacral unit has resulted in moderate marginal osteophytosis and intervertebral disk degeneration. Moderate osteophytes extend from the centrum margins of these two elements. The articular facets exhibit slight marginal lipping (Plate F-22).

Table F-16. Individuals that exhibit spondylolysis

Burial	Sex	Age
41RF1-BP05-040	Male	30-34
41RF1-BP12-046	Female	30-34
41RF1-BP21-069	Male	35-39
41RF1-BP22-109	Female	30-34
41RF1-BP22-127	Male	30-34
41BX5-17-402	Female	60+
41BX5-26-1201	Male	30-34

Antemortem Fractures

Skeletal fractures can be classified into two categories, pathological and non-pathological. Pathological fractures can occur at sites weakened by disease processes, such as osteoporosis. Non-pathological fractures are those associated with trauma or injury, resulting from sharp or blunt force blows. In archaeological samples, antemortem fractures are those in which some healing has occurred. Perimortem fractures are fractures at or near the time of death, of green bone where no healing has occurred, and this may include fractures from the true antemortem and postmortem periods. Postmortem fractures are those that occur after the bone is no longer fresh and may occur from ground pressure or other disturbances (Galloway 1999:12). Fractures can be further classified according to type and direction of force applied to the bone. The forces associated with fractures are tension, compression, shearing, rotation, and angulation. The types of complete fractures are transverse, oblique, spiral, comminuted, butterfly, and segmental (Galloway 1999:53). “The distinct morphology of the fractures can provide significant information upon which to base an interpretation of the forces involved, the direction of the loading and the effect of bone strength” (Galloway 1999:62).

Antemortem trauma to the head suggests that individuals faced and survived interpersonal violence. Novak (1998, 1999) and Meadows Jantz et al. (1999) showed that the head is likely to be the target of blows by assailants as well as being vulnerable in accidents. Table F-17 provides the individuals that suffered from antemortem trauma to the face or head as evidenced by healing or healed fractures. One of the females, 41RF1-BP02-006, aged 35-44 years, suffered a strong blow to the face that resulted in fracturing of the maxilla as well as fracturing of the central incisors. These fractures were in the process of healing indicating a relatively

recent event. An antemortem cranial fracture includes the right parietal which exhibits a well-healed chop type fracture. This defect has a long medial margin (21 mm) and is approximately 10 mm wide. The middle and lateral portions of the defect appear to be incomplete spalls that have healed. Remodeling has rounded the margins of the wound. No evidence of active infection is present as the surface texture of this defect is consistent with the surrounding ectocranial surface (Plate F-22). It seems clear that this individual suffered a minimum of two different violent events or attacks.

Figure F-6 illustrates the frequencies of antemortem fractures across Refugio and Rooms 17 and 26 from San Juan Capistrano by sex. The frequencies are calculated by the number of observed elements fractured divided by the number of the same element counted in inventory. The fractures are specifically reported by location on the bones, and the states of healing include healed with callus formation or healing. The most obvious feature that stands out in Figure F-6 is that Refugio has a much higher rate of occurrence of fractures compared the Capistrano series. While many more elements exhibit evidence of fracture in Refugio, the actual counts of elements fractured are very low, i.e., typically only one male in Refugio has a fractured distal femur. This holds true for all the samples. One individual from Refugio also exhibited evidence of healed rib fractures, however the frequency of ribs was not calculated. Appendix IID lists the individuals that exhibit fractures.

An example of an antemortem, postcranial fracture is seen on a male, aged 16-19 years (41RF1-BP22-112). The distal humerus articular surface is bifurcated and malformed. A compression force, directed up from the radius and ulna, has fractured the lateral aspect of the distal metaphysis and epiphysis. A healed fracture extends along the anterior surface from medial margin of the capitulum to the lateral margin of the metaphysis (45 m from the distal end of the

Table F-17. Individuals exhibiting antemortem trauma to the head or face

Burial	Sex	Age	Bone	Side	State
41RF1-BP02-006	Female	35+	Maxilla Parietal	Left Right	Healed Healing
41RF1-BP05-017	Female	15-35	Frontal	Center	Healed
41RF1-BP11-044	Male	35+	Nasal	Left & Right	Healed
41RF1-BP26-125	Male	15-35	Zygomatic	Right	Healed

capitulum). The central portion of the distal articulation was severely damaged and may have necrosed. The subchondral bone of the trochlea and capitulum is irregular. Osteoarthritic changes in the joint include mild surface osteophytes and surface porosity. The stability of the joint has been greatly reduced as a result of the bifurcated articulation that allows lateral movement of the ulna and radius.

The proximal ulna has a healed incomplete fracture of the coronoid process. The trauma has affected the morphology of process, joint surface, and the radio-ulnar articulation. The articular surface of the coronoid process is concave and roughened to accommodate the modified trochlea of the humerus. The radial notch on the ulna is concave and irregular with mild marginal lipping on the posterior border and mild surface porosity.

The radius has an incomplete compression fracture of the radial head. The fracture has healed, but the radial head is enlarged and irregular. The surface of the head is relatively flat and posteriorly elongated. The ulnar articular surface on the margin of the head was damaged postmortem. The compressive trauma may have fractured the proximal epiphysis during fusion (Plate F-22).

Perimortem Trauma

Perimortem Fractures

Researchers have found that the head is usually the target of interpersonal violence as the brain and skull are the most vulnerable areas of the body when damaged. Furthermore, in accidental falls the head is likely to be injured (Roberts and Manchester 1995:79; also see Meadows Jantz et al. 1999; Novak 1998, 1999). However, both cranial and postcranial perimortem fractures were documented in the Refugio series (Table F-17). For further discussion of fractures see previous section, Antemortem Fractures.

All of the individuals that suffered traumatic deaths were males, and the majority of these males were young adults. Table F-18 provides the general type of trauma that was identified for the eight individuals. Five of these males exhibit evidence of scalping in the form of cutmarks, two of the males display evidence of blunt trauma to the head, and the last individual suffered from perimortem fracturing of the leg. An associated femur from Burial Feature 26 also exhibits blunt trauma.

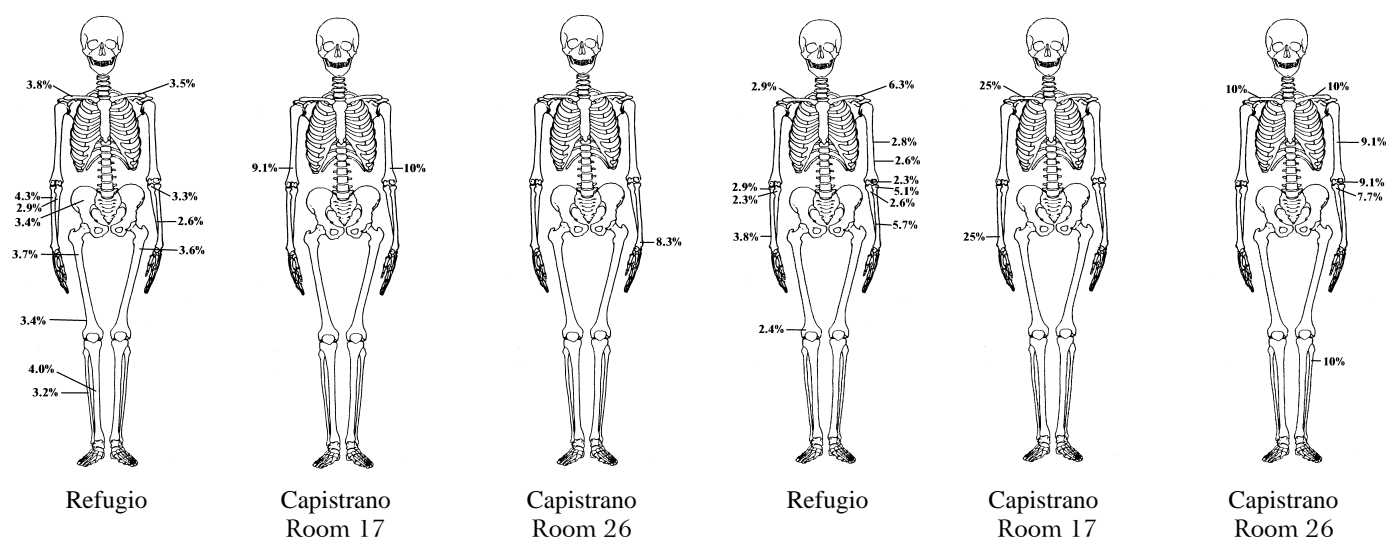


Figure F-6. Frequencies of fractures by element (Left group of 3 = male, Right group of 3 = female).

A male aged 20-24 years (41RF1-BP22-107) displays perimortem trauma in the form of cranial fractures. The nature of the fractures indicate a blunt force trauma with penetration into the braincase. Five radiating fractures are associated with the main force. Three of these proceed inferior toward the inferior temporal line on both the right and left side, and the third descends toward the right orbital border. The fourth fracture line ascends to and terminates at the intersection of the sagittal and coronal sutures, and the fifth fracture line ascends to and terminates midway between the left inferior temporal line and bregma. External beveling occurs around the initial impact area and also along the superior fracture lines. Several teeth display perimortem fractures of the crowns and roots including the maxillary right lateral incisor and the left central and lateral incisors. The fracture of the right lateral incisor exhibits peeling of the buccal surface of the crown extending up the tooth root. The left central incisor fracture also displays some buccal peeling, but it is not as extensive as the lateral. The left lateral incisor displays a similar pattern as the right lateral incisor with extensive buccal peeling of the tooth root (Plate F-23).

An example of postcranial, perimortem fractures is seen on a male, aged 25-30 years (41RF1-BP22-097). Perimortem trauma is present in the form of fractures of the left tibia and fibula. The left tibia exhibits a comminuted fracture with an accompanying butterfly fracture of the anterior crest. Radial fracture lines are present proximal-medial,

anterior-proximal, lateral-posterior, and distal-medial in relation to the fracture, and the entire middle third of the bone is affected. Eight separate fragments resulted from the fracture, of which two display radial fracture lines. Marked bone peeling is associated with the anterior portion of the fracture. The proximal fibula also displays a perimortem fracture with a slight radial fracture line anterior-lateral. Slight medial peeling is present at the distal end of the fracture. This fracture most likely occurred in conjunction with the tibial fracture. The fracture appears to have resulted from blunt trauma directed to the anterior portion of the tibia (Plate F-24).

Another example of postcranial, perimortem fractures is seen in an unmatched femur identified as, 41RF1-BP26-F01L. This element represents the proximal shaft of a left femur. The shaft is from an adult with thick cortical bone and well developed trabeculae. The shaft exhibits a perimortem fracture in the intertrochanteric region. In general, the break is comminuted with oblique fracture lines. The element consists of nine bone fragments but numerous pieces are missing postmortem. Galloway classifies this type of fracture as a “subtrochanteric fracture with butterfly segments” (1999:174-179; following the classification system of Seinsheimer [1978]). These types of fractures typically result from axial loading of the femur or from “direct lateral force applied to the upper thigh” (Galloway 1999:177). Often these types of fractures occur due to a fall or high energy impact.

Table F-18. Individuals exhibiting evidence of traumatic death

Burial	Sex	Age	Trauma
41RF1-BP04-021	Male	50-54	Scalping
41RF1-BP05-039	Male	20-24	Scalping
41RF1-BP16-083	Male	35-39	Blunt trauma
41RF1-BP17-087	Male	25-29	Scalping
41RF1-BP22-082	Male	35-39	Scalping
41RF1-BP22-097	Male	25-29	Leg trauma
41RF1-BP22-107	Male	20-24	Scalping
41RF1-BP26-119	Male	25-29	Blunt trauma
41RF1-BP26-F01L	Indeterminate	Young adult	Leg trauma

Scalping

Scalping is another type of perimortem trauma illustrating interpersonal violence observed in several individuals from the Refugio sample. Scalping is defined as the excision of a variably-sized segment of the scalp, often used as a trophy. The lithic or metal knives used in the cutting often left marks on the bones of the skull, which is how scalping is identified

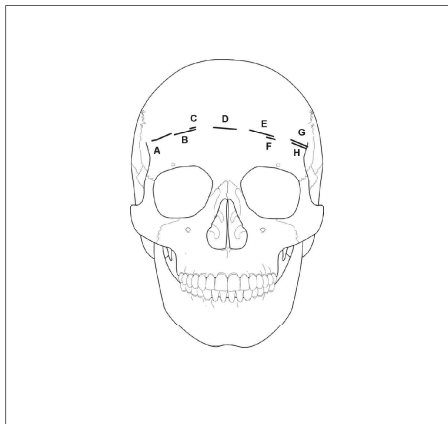


Figure F-7. Diagram of scalping on 41RF1-BP17-087.

Table F-19. Location and measurements of cutmarks on 41RF1-BP17-087

Cut	Location	Length (mm)
A	Frontal	15.1
B	Frontal	13.1
C	Frontal	2.0
D	Frontal	11.1
E	Frontal	11.9
F	Frontal	5.0
G	Frontal	10.7
H	Frontal	8.9
I	Left Parietal	23.7
J	Right Parietal	13.1
K	Right Parietal	18.5

in skeletal remains (Aufderheide and Rodriguez-Martin 1998:39). Scalping has been documented in many Native American groups from across North America from before the arrival of Europeans (Willey 1990). Five individuals from Refugio are identified as having evidence of scalping (Table F-18).

Close examination of 41RF1-BP17-087 revealed numerous perimortem cuts. This adult male has perimortem, scalping cutmarks present on the cranial vault indicating a traumatic death. A total of eleven cuts are present with eight of the cuts arranged in an arc on the frontal (Table F-19). This arc extends from the left anterior temporal line reaching close to the right anterior temporal line (Figure F-7; Plate F-25).

A male, aged 34-39 years (41RF1-BP22-082) exhibits evidence of perimortem scalping. A total of forty-nine cuts around the crania indicate scalping occurred at or near the time of death. The frontal bone exhibits twelve cuts that range in length from 4 mm to 24 mm. These cutmarks predominantly occur high up on the forehead in a horizontal direction. The left parietal has sixteen cuts proceeding from the temporal line back towards asterion. A set of cuts proceed across the sagittal suture at the mid-sagittal area, these cuts possibly resulted from a secondary cut made at the time of death possibly to release the scalp from the crania. The right parietal has seven cuts proceeding from asterion to the coronal suture. The occipital has fourteen cuts located above the nuchal region proceeding basically from left asterion to right asterion, however, direction of the cuts is not discerned (Plate F-26).

A third example of scalping observed in the Refugio series is a male, aged 20-24 years (41RF1-BP22-107). Cuts are present on the frontal, both parietals, and occipital. The frontal has two cuts along the left inferior temporal line measuring 6.4 mm and 11.8 mm, respectively. The right parietal has eight cutmarks located anterior and near the insertion for temporoparietalis and temporalis, and ranging posterior and medial. A few of these cutmarks display a rocking action and repeated strokes with a knife producing multiple grooves per cut. The left parietal has two cuts near the sagittal suture. The occipital has three cuts near the left midlambdoidal suture, starting inferior and moving superior along the suture (Figure F-8; Plate F-27).

Another case of a traumatic death seen in the Refugio series is a male, aged 20-24 years (41RF1-BP05-039). Evidence of a traumatic death is present in the form of a metal

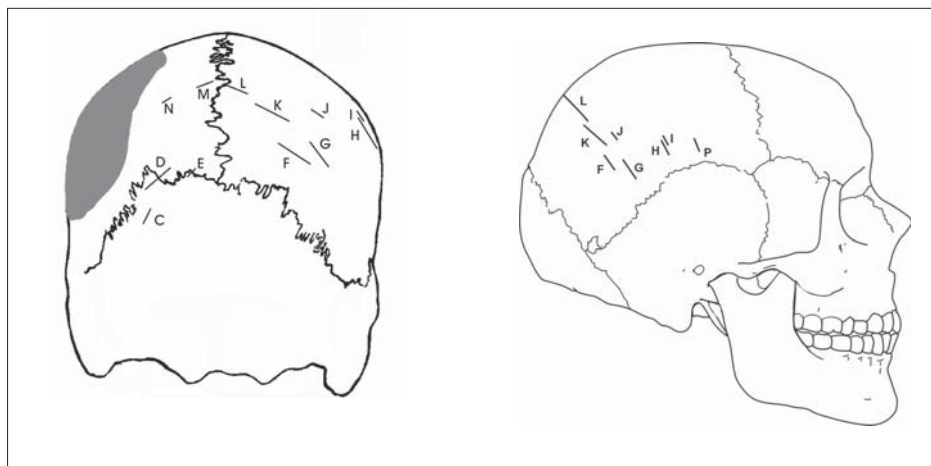


Figure F-8. Diagram of scalping on 41RF1-BP22-107.

Table F-20. Description of the cutmarks on 41RF1-BP05-039

Cutmark	Length (mm)	Cutmark	Length (mm)	Cutmark	Length (mm)
A	6.9	H	27.8	O	10.4
B	22.6	I	2.7	P	23.2
C	19.3	J	6.7	Q	10.7 (widest cut at 0.7 mm)
D	85.6 (chord) 95 (with tape)	K	11.7	R	15.4
E	12.8	L	Not a cut	S	9.8
F	36.3	M	58.4	T	7.6
G	7.7	N	2.0	U	9.7

projectile point present in the rib cage and recovered during the excavation, however, no perimortem cutmarks were found on the ribs. Evidence of a traumatic death includes the presence of multiple cutmarks on the anterior cranial vault indicating perimortem scalping. A minimum of twenty cutmarks was recorded on the frontal and left and right parietals. Examination of the fragments representing the posterior vault did not yield any cuts to this portion of the cranium, however, much of the bone is missing. The cuts are very narrow suggesting that the attacker employed a sharp metal blade. The lengths of the cutmarks range from approximately 2 mm to as long as 95 mm (Table F-20). The orientation of the cuts on the frontal bone is diagonal with the right side showing the more anterior and inferior cuts, whereas the left side displays the more superior and posterior cuts (Figure F-8; Plate F-28).

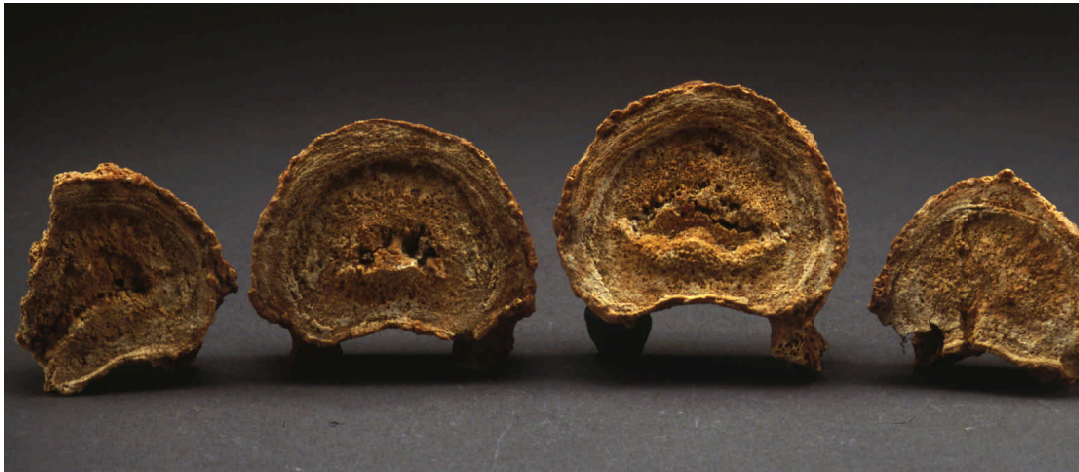
A final example of perimortem trauma is evident on the cranium of a male, aged 45-54 years (41RF1-BP04-021), in the form of cutmarks and chops by a bladed or edged weapon. A minimum of 5 blows and 16 cutmarks are present on the right frontal and right parietal. The largest of the chops measures 13.3 mm in length and 2.6 mm in width. The majority of the wounds occur on the frontal approximately 54 mm above nasion and lateral centering on the right portion of the frontal squamous. The cutmarks on the frontal range in length from 1 to 13 mm, however, the longest may actually measure longer than recorded as the posterior portion is missing postmortem. The cutmark on the right parietal is located just posterior to the coronal suture. This cut measures 13.9 mm in length. Perimortem trauma to the head may actually be more severe. This individual was recorded as a traumatic death (Plate F-29).

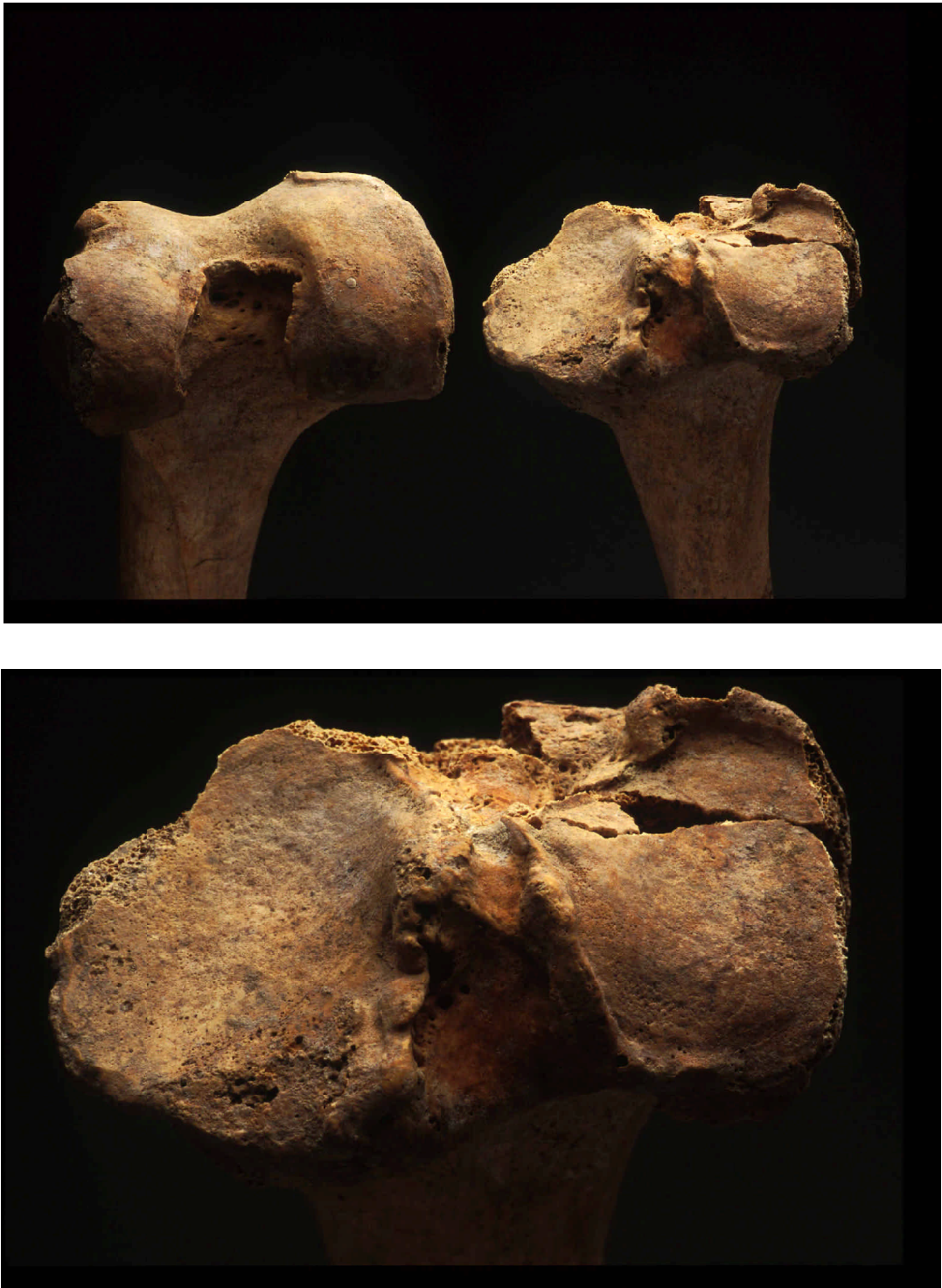

Plate F-1. 41RF1-BP26-125: osteoarthritis of distal femur and proximal tibia.



Plate F-2. 41RF1-BP22-116: lumbar vertebrae exhibiting spinal osteophytosis.



41RF1-BP26-126



41RF1-BP05-017

Plate F-3. *Examples of Schmorl's nodes on vertebrae.*



Plate F-4. *41RF1-BP12-050: Distal tibia and fibula exhibiting enthesophyte.*



Plate F-5. *41RF1-BP31-105: myositis ossificans on distal femur.*

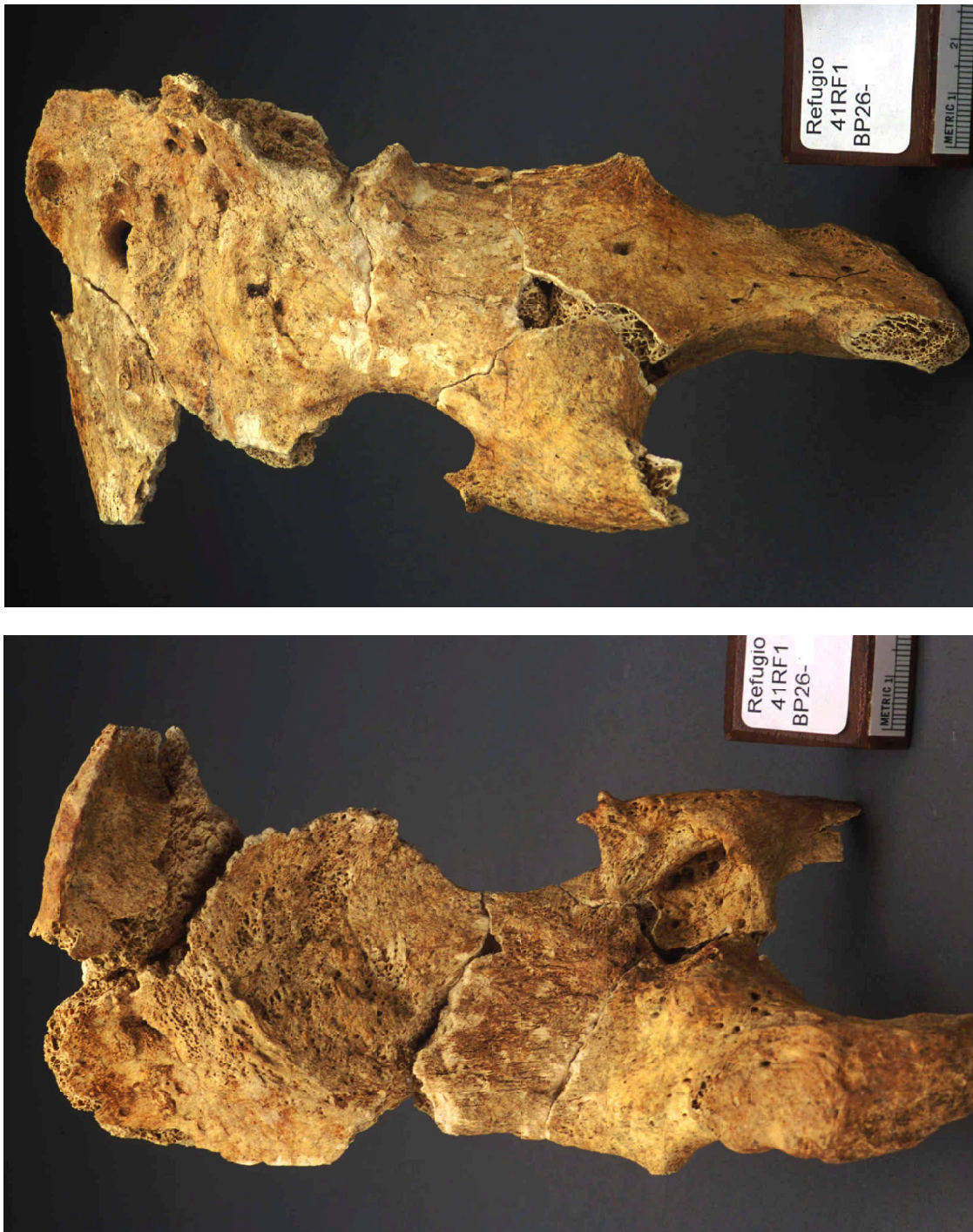


Plate F-6. 41RF1-BP26-105R: medial and lateral views of innominate displaying osteomyelitis as a result of a dislocation.

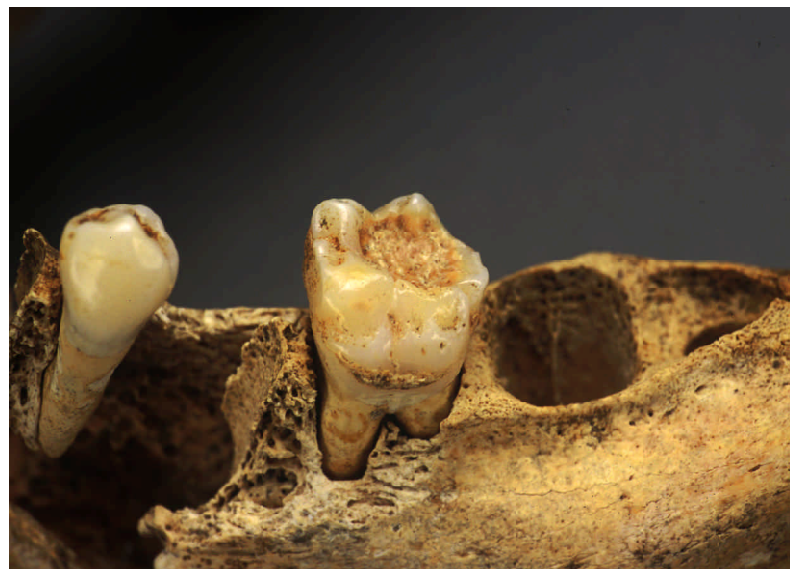
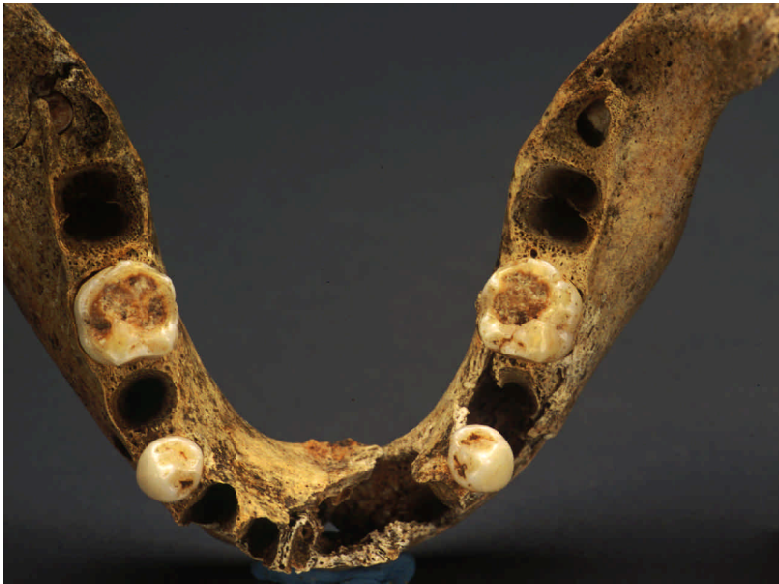
Plate F-7. 41RF1-BP05-032: Mulberry molars.

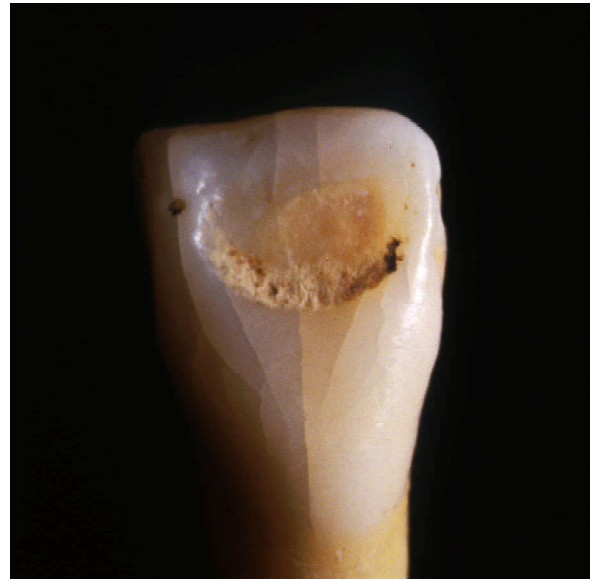
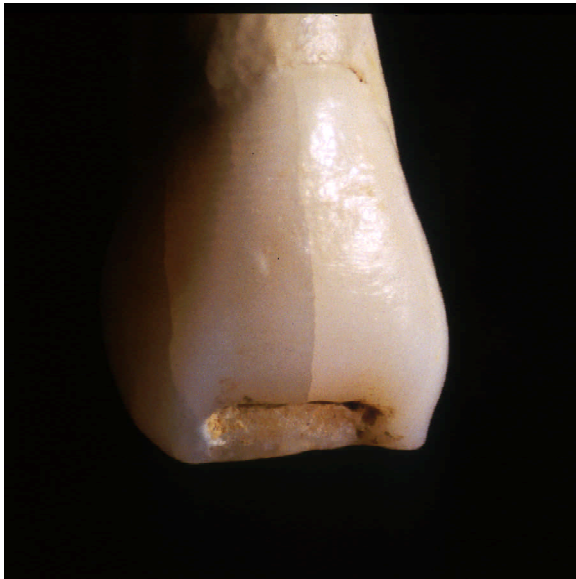
Plate F-7. *continued.* 41RF1-BP05-032: *Hutchinson's incisor and linear hypoplastic defects.*

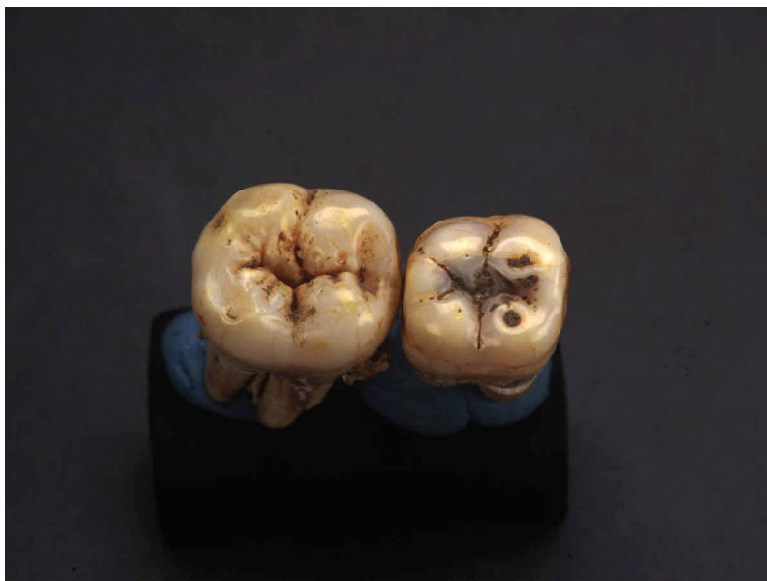
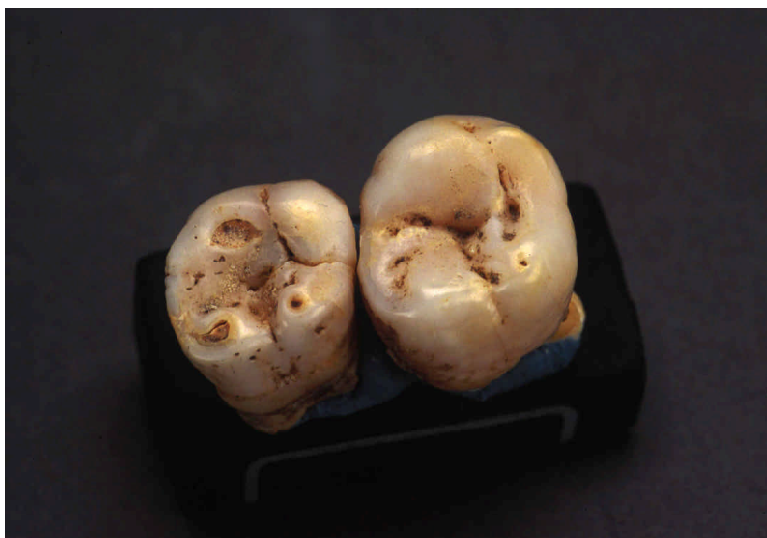
Plate F-8. 41RF1-BP13-047: Moon's molars.



Plate F-9. 41RF1-BP17-094: infant long bones exhibiting characteristics of congenital syphilis.



Plate F-10. 4IRF1-BP17-090: femora and right tibia exhibiting periosteal expansion.



Plate F-11. 41RF1-BP34-106B: medial and lateral views of left ulna with severe periostitis and osteomyelitis indicative of treponemal disease.



Plate F-12. 41RF1-BP17-078: external and internal views of rib displaying osteomyelitis.

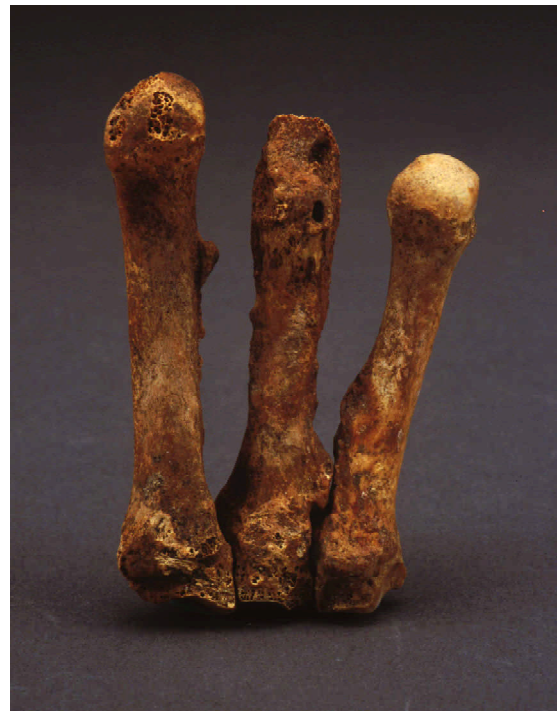
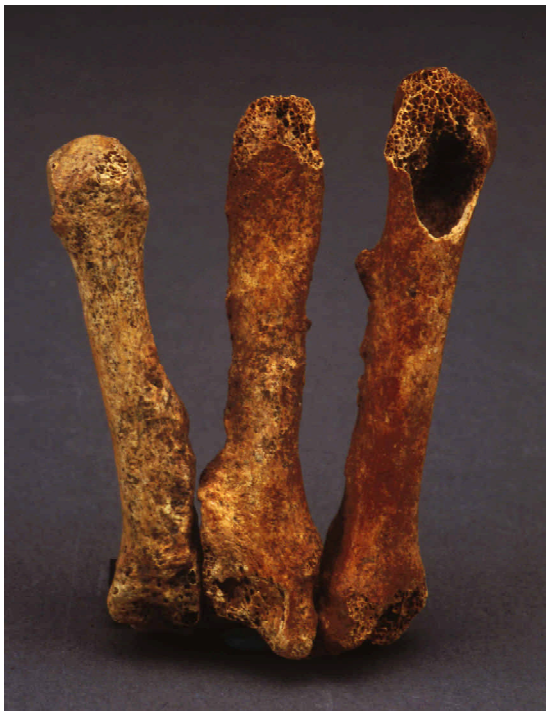
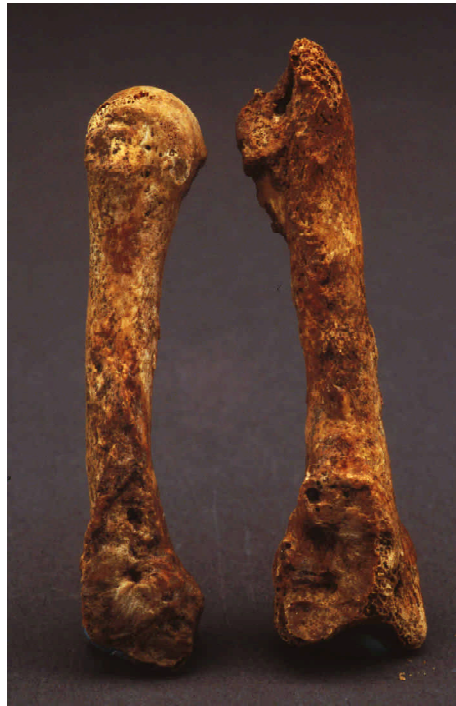Plate F-13. 41RF1-BP24-068: views of third metacarpal exhibiting osteomyelitis due to fracture.



41RF1-BP17-062



41RF1-BP22-117



41RF1-BP22-112

Plate F-14. *Examples of periostitis on a tibia, humerus, and fibulae.*

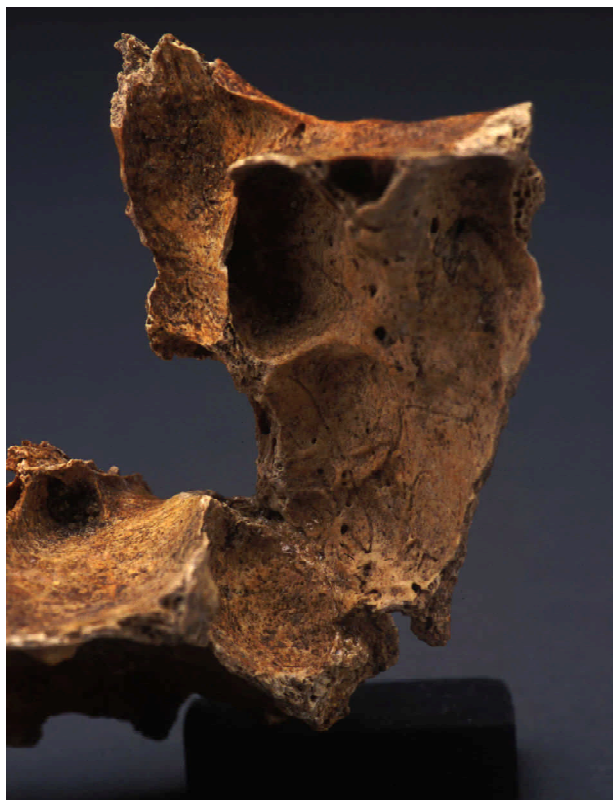


41RF1-BP09-042



41RF1-BP15-052

Plate F-15. *Examples of sinusitis.*



41RF1-BP17-090



41RF1-BP17-090

Plate F-15. *continued...*



41RF1-BP05-034



41RF1-BP16-083A



41RF1-BP22-112

Plate F-16. *Varying degrees of cribra orbitalia on three individuals.*



Plate F-17. *41RF1-BP22-112: cranium with porotic hyperostosis.*

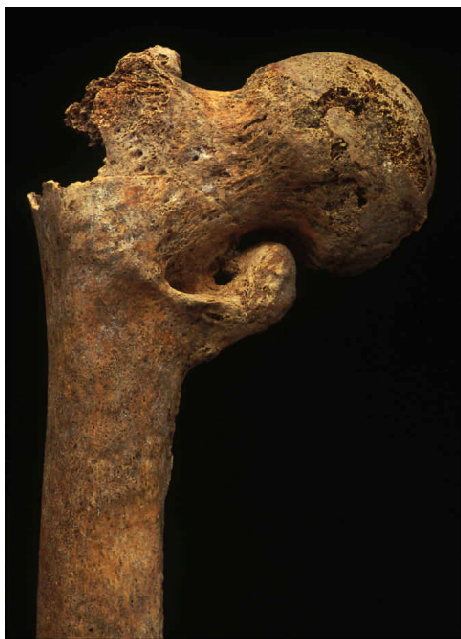
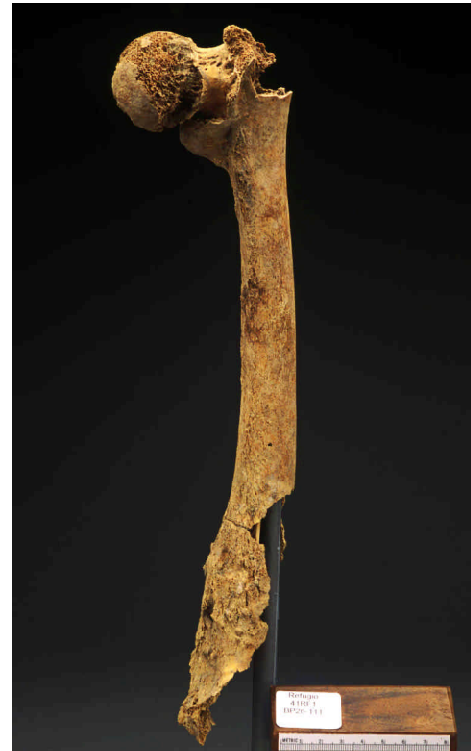
Plate F-18. 41RF1-BP26-111: right femur with healed proximal fracture due to osteoporosis and healing distal fracture with osteomyelitis.

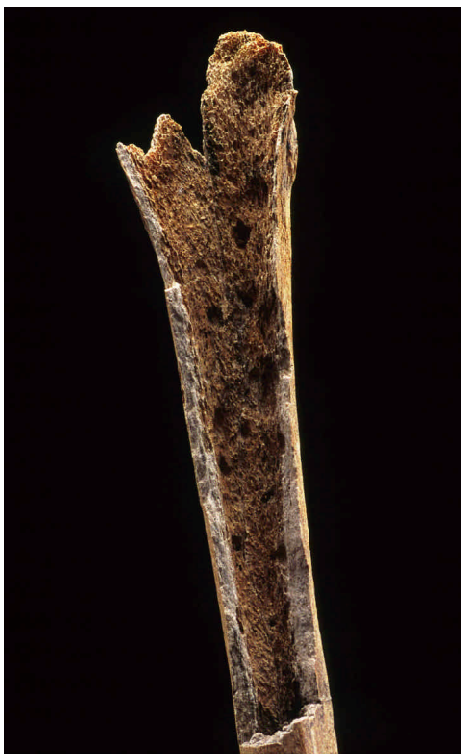
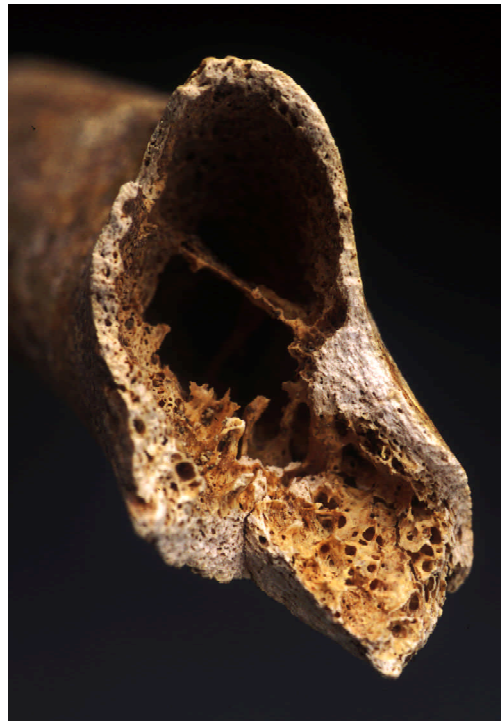
Plate F-19. 41RF1-BP20-002: views of scalloped and lytic cavitations within long bones.

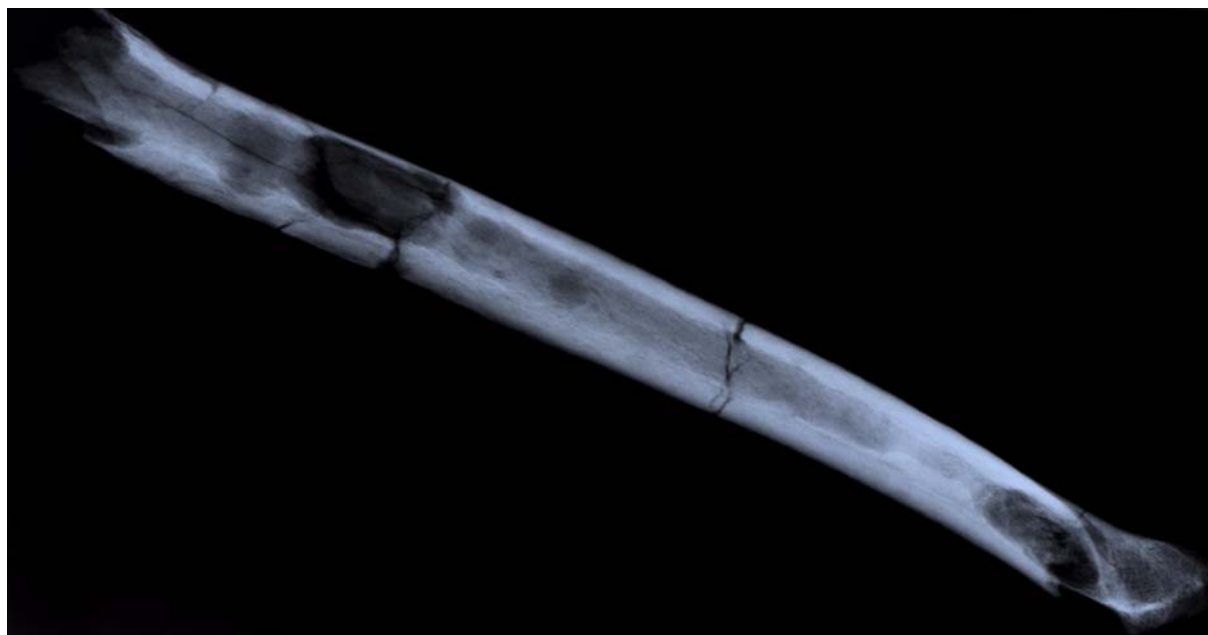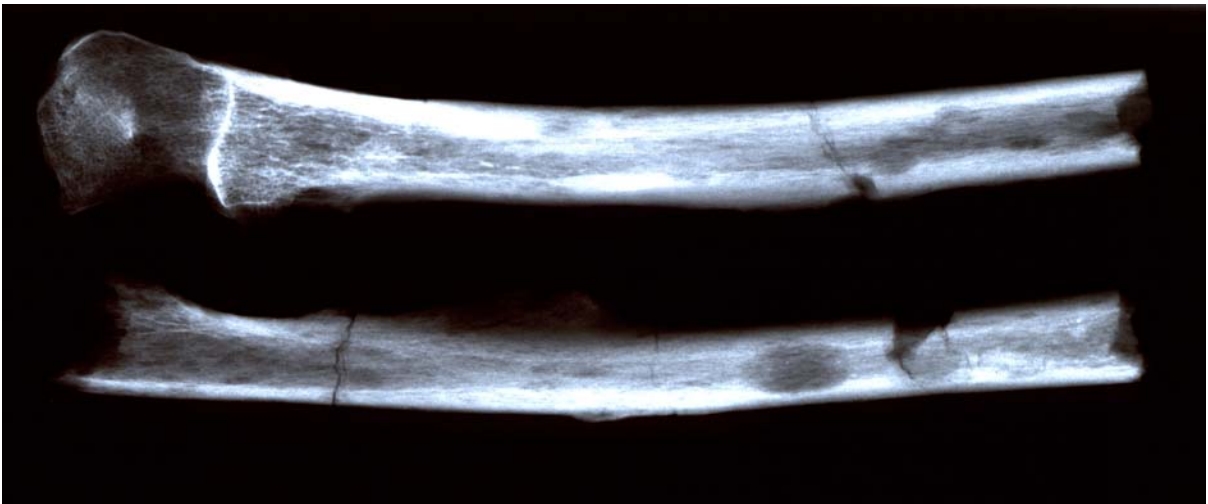

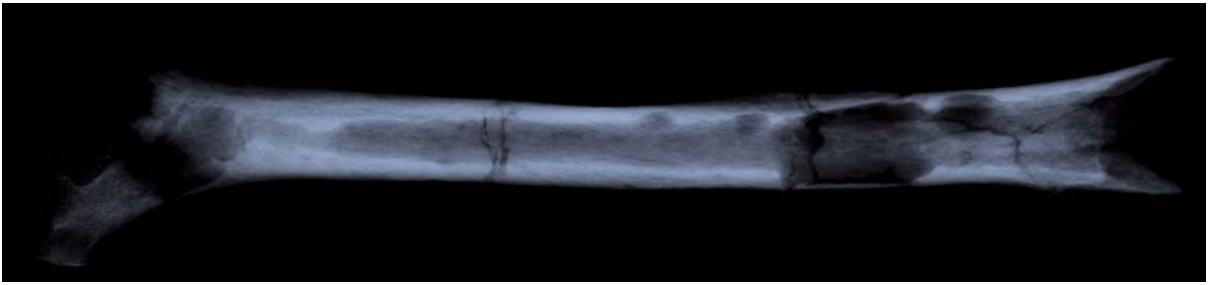
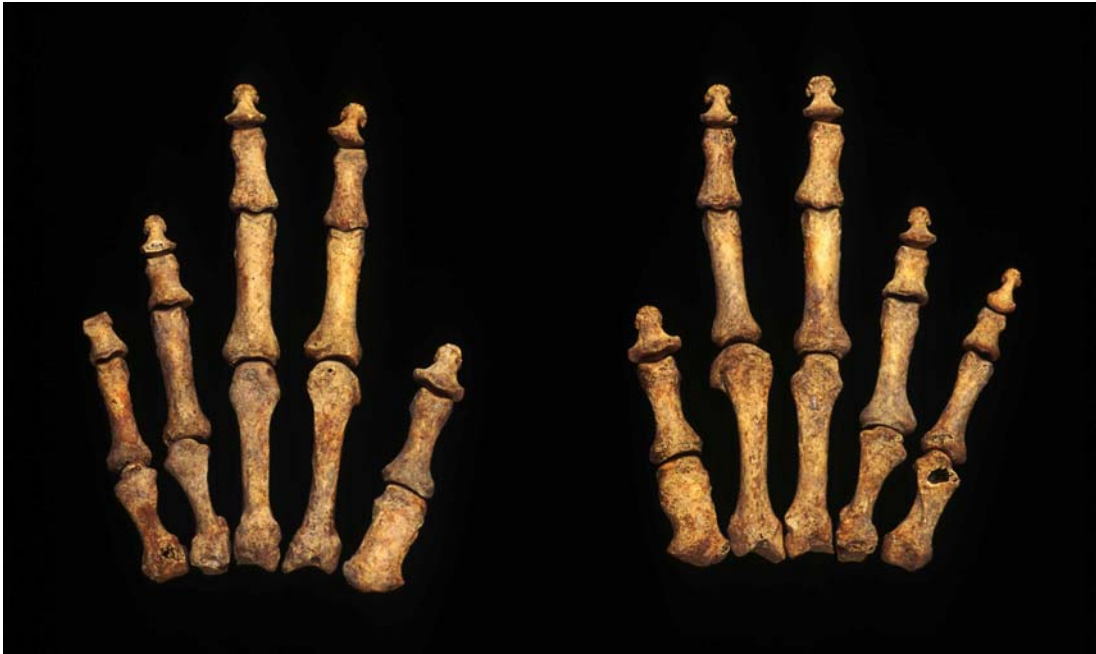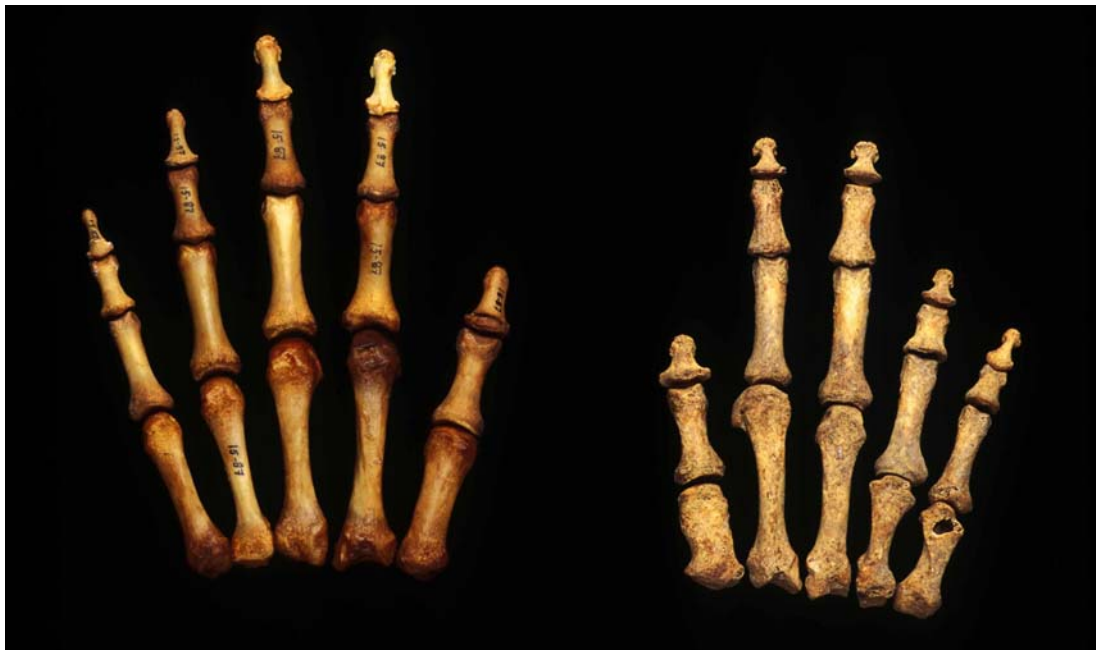Plate F-19. *continued.* 41RF1-BP20-002: X-rays of long bones of an individual exhibiting multiple myeloma.



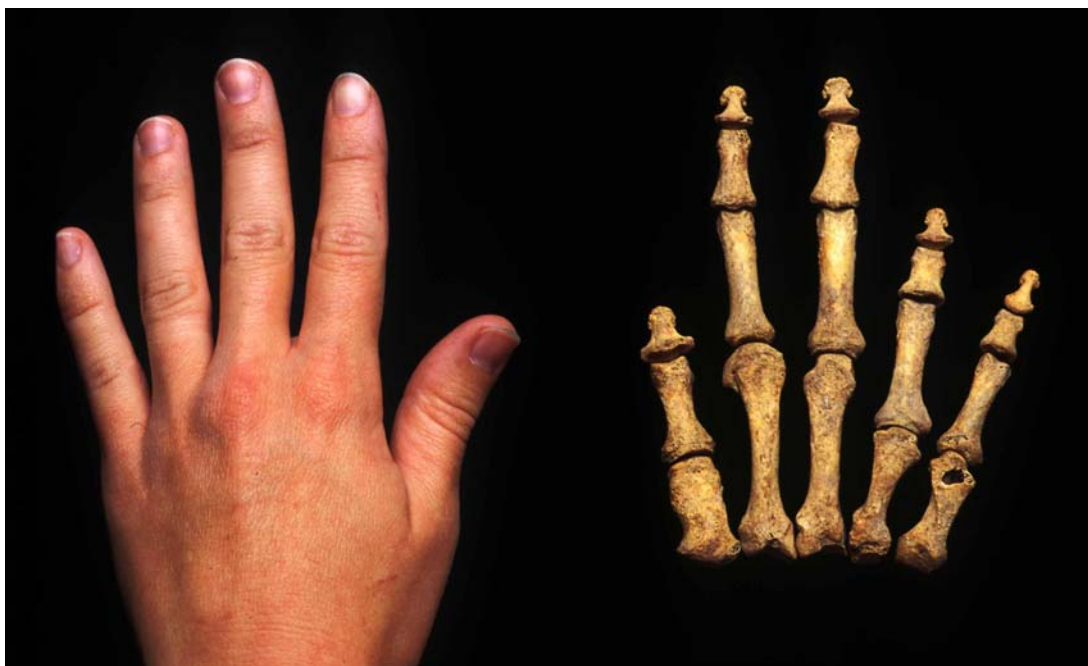Plate F-20. 41RF1-BP02-015: *bilateral osteochondritis dessicans*.



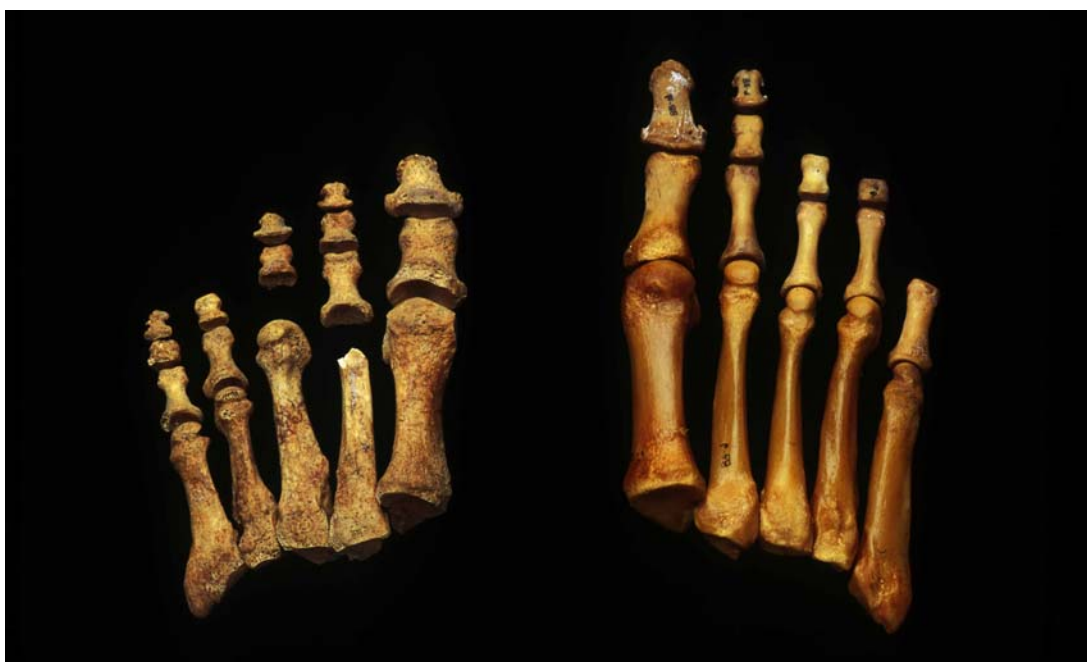41RF1-BP17-086



41RF1-BP17-086 (right) compared with an average hand (left).



41RF1-BP17-086 (right) compared with an average hand (left).



41RF1-BP17-086 (left) compared with an average foot (right).

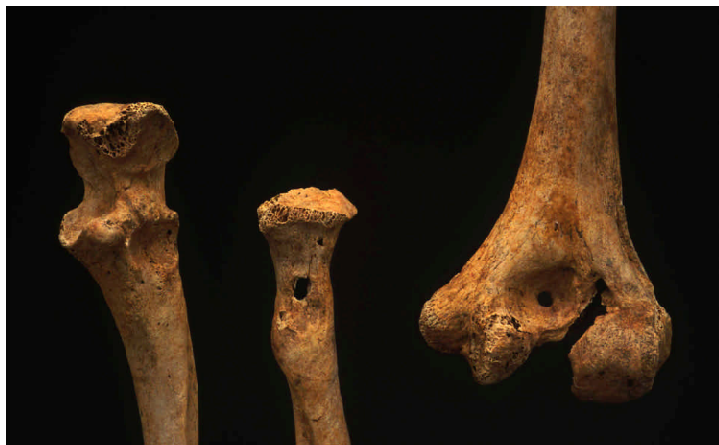Plate F-21. continued. *Brachymetacarpia* and *brachymetatarsia*.



41RF1-BP21-069



41RF1-BP02-006



41RF1-BP22-112

Plate F-22. *Examples of antemortem trauma.*

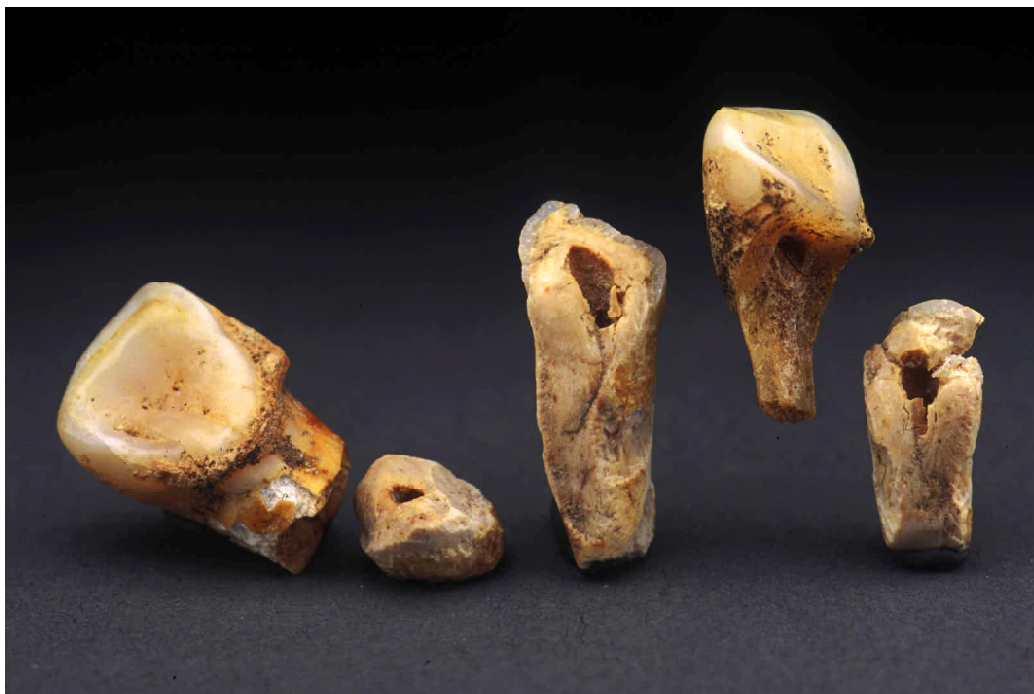

Plate F-23. 41RF1-BP22-107: examples of perimortem trauma.



Plate F-24. 41RF1-BP22-097: example of perimortem postcranial trauma.



Plate F-25. 41RF1-BP17-087: view of frontal with perimortem scalping marks.



Plate F-26. 41RF1-BP22-082: cutmarks on frontal and parietal.



Plate F-27. 41RF1-BP22-107: perimortem cutmarks on right parietal.




Plate F-28. 41RF1-BP05-039: view of frontal with perimortem cutmarks.



Plate F-29. 41RF1-BP04-021: view of perimortem cutmarks and close-up of “chop marks.”

Summary

The first general category of joint diseases provides information on the frequencies of osteoarthritis for joint surfaces, vertebral osteoarthritis, Schmorl's depressions, enthesophytosis, and joint dislocation. From these joint diseases, we can see that the Refugio population experienced relatively low stress when compared to other populations such as San Juan Capistrano. However, from the burial descriptions of functional morphology (Appendix O-1), we see that most of these individuals exhibit moderate to marked muscle attachment sites. Joint osteoarthritis is recorded more frequently for older males, specifically in the knee. Young adults as expected exhibit very low frequencies of osteoarthritis. Of the 19 individuals coded for moderate to severe arthritis, only two individuals display severe joint modification, and only one individual was coded for ankylosis (sacroiliac joint).

Schmorl's depressions among the Refugio population occur relatively infrequently. The highest rate occurs in the lumbar vertebrae of young males at approximately 11 percent. Figures F-2 and F-3 illustrate the differences between the Refugio and San Juan Capistrano series and suggest that the Refugio population were somehow protected from this type of back stress.

Enthesophytosis is more commonly associated with older age or high activity levels. Once again, the Refugio population exhibits lower rates of enthesophytosis than does the San Juan Capistrano population. Of interest, only the males display enthesophytic development below the knee. Some of the high peaks in the frequencies for the San Juan Capistrano samples may be artifactual due to small sample sizes. Overall, the males show greater frequencies in the patellae and the calcanei suggesting greater stresses from squatting and or walking/running.

The second general category of infectious or inflammatory diseases provides information on general health of the population. Osteomyelitis was identified in five individuals, four of which resulted from trauma and one from treponemal infection. Sinusitis was noted in four individuals. Periostitis was recorded in relatively low frequencies in the Refugio population. Older males display periostitis more than the other groups, and the legs are most commonly affected.

The only infectious disease that we identified in the Refugio population was treponemal. Of the five cases of treponemal infections, three were identified as congenital, and two adult

males were identified as most likely adult onset syphilis. Of interest, while it seems apparent that at least one, if not three, females suffering from treponemal infection produced infants that became infected, none of the females identified in the Refugio series exhibited evidence of treponemal infection.

The third general category presented in this chapter focuses on metabolic disorders. Suggested causes of cribra orbitalia or porotic hyperostosis have been linked to different types of anemia such as iron deficiency anemia. Seven individuals from Refugio were noted as displaying cribra orbitalia, four adults and three children. Porotic hyperostosis was identified in two individuals, one of which also was coded as having cribra. Finally, four individuals were coded as displaying evidence of osteoporosis. Three of these individuals are over fifty years of age while the third individual suffered from severe trauma and subsequent osteomyelitis.

Other pathological conditions of particular interest include carcinoma and congenital disorder. A male was identified as suffering from multiple myeloma and a female was noted as exhibiting evidence of the unusual bilateral brachymetacarpia and bilateral brachymetatarsia. Both of these are isolated cases of each condition, however, the brachymetacarpia and brachymetatarsia have been reported as being familial traits.

The final general category discussed is trauma. The occurrence of antemortem trauma in the form of healing or healed fractures to the postcranial skeleton is shown in Figure F-6. Although it appears as if the Refugio population suffered high rates of trauma, in fact the actual counts of elements fractured is very low. The figure does illustrate that the Refugio individuals suffered more trauma than those from the San Juan rooms suggesting greater risk of trauma at Refugio.

Perimortem trauma was recorded for nine individuals from the Refugio population. Five individuals suffered scalping, two suffered blunt trauma to the head, and two individuals suffered at least perimortem trauma to the leg. Most of these trauma deaths likely resulted from aggressive interaction with outside groups. The burial record indicates that 13 individuals were "killed by barbarian Indians." The high level of aggression in this population suggests that life was not without risk on the mission.

Overall, the health of the population at Refugio is relatively good. This may be reflecting more of the life of hunters and

gatherers of the Texas Coast than life on the mission. Ricklis (1996) suggests that the Karankawa that inhabited the Refugio mission utilized the mission seasonally. Other indicators of health are discussed in the following sections.

Osteological Analyses

Section G

Dental Pathology

Analysis of dental pathology provides an opportunity to examine the oral health, diet, and perhaps behavioral aspects of a population. This section discusses the dental pathology of the Refugio series and compares them to Rooms 17 and 26 of the Mission San Juan Capistrano series as well as other Texas populations. Specific conditions or disease processes that we examined include caries, dental alveolar abscesses, antemortem loss of dentition, calculus, dental wear or attrition, enamel chipping, and linear enamel hypoplasias. Methods for coding these conditions were discussed previously.

Caries occur when bacterial activity causes destruction or demineralization of the enamel (Pindborg 1970). This breakdown of the enamel allows exposure of the pulp chamber and generally results in infection. The disease process that occurs with carious lesions follows that if not treated abscessing and antemortem loss will most likely result. Sedentary populations have long depended on maize and other high carbohydrate foods for subsistence. The high carbohydrate diet is cariogenic, and these populations have been documented as having high caries frequencies (Smith 1983). Concomitant with greater caries frequencies, sedentary populations have high rates of dental attrition and antemortem tooth loss. In preparing the food, such as maize or beans, for consumption, debris from the grinding becomes integrated into the corn-based foods. As this food is eaten, the dental enamel is subjected to the abrasive contact with the hard grit. Consequently, the enamel is gradually worn down and may lead to the formation of secondary dentin. Patterns of high caries frequencies, high rates of antemortem tooth loss, and heavy dental attrition are expected in long standing mission populations, as they would be reliant on maize, beans, and beef for subsistence.

Temporal presence of the populations on the missions overlaps between the Refugio and San Juan Capistrano groups. Traditional subsistence patterns of the groups that resided at the missions were not very different. However, during the period affecting these samples, the native people occupying the Refugio mission were continuing their traditional subsistence while those at the San Juan Capistrano mission may have been more heavily reliant on mission food (Ricklis 1996). The period in which Mission Refugio was

occupied (1795-1830) falls in the middle of the occupation of the groups from the two rooms at San Juan Capistrano. The primary Native American occupants of the Refugio mission were the Karankawa. The Karankawa were traditionally hunters and gathers subsisting on fishing and hunting of deer and other small game. Maize was not a staple in the diet of these people until moving to the mission. In addition, Ricklis (1996) states that the Karankawa were maintaining their traditional mobility patterns by arriving at the Refugio mission during the traditional move from the coastal fishing territories into the coastal plain hunting regions. The Coahuiltecans were the primary groups that comprised the Native population of San Juan Capistrano. Prior to life in the missions, these populations were also hunters and gatherers. However, Humphreys (1971) states that by the late eighteenth century this population had become admixed and had experienced cultural change in adapting to mission life. Based on these subsistence differences, dental pathology of these mortuary samples is compared.

Caries, Abscesses, and Antemortem Loss in Adults

Tables G-1 through G-3 present the results of the analysis of adults for dental caries, antemortem loss, and alveolar abscesses for the Refugio series, and Rooms 26 and 17 for the San Juan Capistrano series. These data are presented by arcade (maxillary or mandibular), tooth type (incisor, canine, premolar, or molar), and age group. Similar to the bone counts, the Refugio series has a much higher number of teeth ($n = 1431$) represented in the series compared to the San Juan Capistrano samples (Rm. 26: $n = 432$, Rm. 17: $n = 281$).

The Refugio dental series exhibits overall relatively good oral health (Table G-1). The caries frequency for the adult dental population is low at 8.7 percent. Young adults have a lower caries rate (6.6 percent) than the older adults (13.0 percent). In both of the groups, caries occur more frequently in the mandibular teeth (9.7 percent) than in maxillary teeth (7.6 percent). Within the sample, the highest frequency occurs in the mandibular teeth of individuals 35+ years of

Table G-1. Refugio mission inventory and pathology in permanent dentition

ARCADE AND TEETH	Number Teeth	Number Carious	% Carious	Calculus Average	Number Sockets	Antemortem Loss	% Antemortem Loss	Alveolar Abscesses	% Alveolar Abscesses
<u>Age 15-34</u>									
Maxilla									
Incisor	107	1	0.9	2.71	83	0	0.0	4	4.8
Canine	53	0	0.0	3.02	40	0	0.0	3	7.5
Premolar	129	3	2.3	2.92	83	0	0.0	4	4.8
Molar	198	24	12.1	2.96	107	2	1.9	6	5.6
Subtotal	487	28	5.7		313	2	0.6	17	5.4
Mandible									
Incisor	100	1	1.0	3.79	103	0	0.0	1	1.0
Canine	59	2	3.4	3.53	54	0	0.0	1	1.9
Premolar	130	4	3.1	3.30	92	0	0.0	1	1.9
Molar	206	31	15.0	2.95	141	3	2.1	5	3.5
Subtotal	495	38	7.7		390	3	0.8	8	2.1
<u>Age 35+</u>									
Maxilla									
Incisor	41	3	7.3	2.63	68	17	25	12	17.6
Canine	24	2	8.3	3.33	33	5	15.2	6	18.2
Premolar	55	3	5.5	3.16	54	5	9.3	10	18.5
Molar	88	17	19.3	3.61	58	8	13.8	12	20.7
Subtotal	208	25	12.0		213	35	16.4	40	18.8
Mandible									
Incisor	51	5	9.8	3.96	72	11	15.3	6	8.3
Canine	31	2	6.5	4.07	37	2	5.4	3	8.1
Premolar	67	4	6.0	3.59	71	12	16.9	3	31.0
Molar	88	22	25.0	3.38	104	30	28.8	22	21.2
Subtotal	237	33	13.9		284	55	19.4	34	12.0
TOTAL	1427	124	8.7		1200	95	7.9	99	8.3

age (13.8 percent), and the lowest occurs in the maxillary arcade of young adults (5.5 percent). Caries frequencies by tooth type indicate that molars are more prone to lesions than any other tooth type, and this trend increases with age (Plate G-1).

Other related indicators of oral health include abscessing and antemortem tooth loss. Like the caries frequencies, abscesses and antemortem tooth loss frequencies are also relatively low in the Refugio dentition. Similar patterns are present in these pathological conditions as seen in the caries trends (Table G-1). This is an expected phenomenon as these conditions are related; carious lesions lead to abscessing which in turn results in antemortem loss of teeth (Plates G-2 and G-3).

Another indicator of oral health is the level of calculus present on the teeth. Calculus is scored on a range of 1-6 (see Section B, Preparation and Methods). The average calculus scores for the Refugio adults is presented in Table G-1. The mandibular teeth exhibit higher rates of calculus than the maxillary teeth, however, the difference is not significant. The canine in both age groups and both arcades consistently has the highest average calculus deposits. This is in contrast of Dockall's (1997) results for the Morhiss and Ernest Witte sites.

The sample from Room 26 at San Juan Capistrano exhibits a higher caries rate (13.4 percent) than does the Refugio series (Table G-2). In contrast to the Refugio sample, the young adults from this sample have higher frequencies of

Table G-2. Capistrano Room 26 inventory and pathology in permanent dentition

ARCADE AND TEETH	Number Teeth	Number Carious	% Carious	Calculus Average	Number Sockets	Antemortem Loss	% Antemortem Loss	Alveolar Abscesses	% Alveolar Abscesses
<u>Age 15-34</u>									
Maxilla									
Incisor	36	6	16.7	2.43	62	3	4.8	3	4.8
Canine	20	0	0.0	2.53	31	2	6.5	0	0.0
Premolar	49	2	4.1	2.43	64	3	4.7	5	7.8
Molar	63	14	22.2	2.70	89	3	3.4	7	7.9
Subtotal	168	22	13.1		246	11	4.5	15	6.1
Mandible									
Incisor	12	0	0.0	3.17	36	3	8.3	0	0.0
Canine	17	0	0.0	2.81	18	0	0.0	2	11.1
Premolar	34	1	2.9	2.97	36	0	0.0	0	0.0
Molar	45	20	44.4	2.52	52	6	11.5	6	11.5
Subtotal	108	21	19.4		142	9	6.3	8	5.6
<u>Age 35+</u>									
Maxilla									
Incisor	15	3	20.0	3.08	42	10	23.8	4	9.5
Canine	10	2	20.0	2.70	22	1	4.5	5	22.7
Premolar	24	3	12.5	2.65	42	10	23.8	4	9.5
Molar	29	2	6.9	2.52	54	20	37.0	4	7.4
Subtotal	78	10	12.8		160	41	25.6	17	10.6
Mandible									
Incisor	16	0	0.0	3.31	30	0	0.0	5	16.7
Canine	11	0	0.0	3.27	17	3	17.6	1	5.9
Premolar	21	1	4.8	3.15	33	8	24.2	0	0.0
Molar	30	4	13.3	2.67	46	11	23.9	7	15.2
Subtotal	78	5	6.4		126	22	17.5	13	10.3
TOTAL	432	58	13.4		674	83	12.3	53	7.9

caries (15.6 percent) than older adults (9.6 percent). The mandibular teeth have a higher caries rate (19.4 percent) than the maxillary teeth (13.1 percent) in young adults, however, this trend is reversed in older adults (6.4 percent for mandible and 12.8 percent for maxilla). Specifically, the mandibular molars of young adults have the highest caries rate at 44.4 percent, while the mandibular incisors and canines of both groups and maxillary canines of young adults have no lesions.

Examination of the rates of abscessing and antemortem loss shows similar trends as those seen in the Refugio sample (Table G-2). The older adults have poorer oral health with higher frequencies of abscesses and tooth loss. The

antemortem tooth loss in older adults reflects the higher caries rates in young adults. Calculus averages for this series are very similar to the Refugio sample (Table G-2).

The series from Room 17 at San Juan Capistrano yields the smallest sample size of these groups, yet exhibits the poorest oral health of the three samples (Table G-3). The overall caries frequency for Room 17 is relatively high at 19.6 percent. This sample is similar to the trend seen in the Refugio sample in the higher caries frequencies occurring in the older adults (22 percent) compared to the younger adults (13.1 percent). Caries occur more frequently in mandibular teeth (23.4 percent) than in maxillary teeth (16 percent).

Table G-3. Capistrano Room 17 inventory and pathology in permanent dentition

ARCADE AND TEETH	Number Teeth	Number Carious	% Carious	Calculus Average	Number Sockets	Antemortem Loss	% Antemortem Loss	Alveolar Abscesses	% Alveolar Abscesses
<u>Age 15-34</u>									
Maxilla									
Incisor	15	0	0.0	2.14	41	0	0.0	0	0.0
Canine	9	1	11.1	2.33	20	1	5.0	0	0.0
Premolar	29	1	3.5	2.17	38	0	0.0	0	0.0
Molar	33	11	33.3	2.18	48	0	0.0	0	0.0
Subtotal	86	13	15.1		147	1	0.7	0	0.0
Mandible									
Incisor	14	0	0.0	2.57	42	0	0.0	0	0.0
Canine	9	0	0.0	2.33	24	0	0.0	0	0.0
Premolar	20	2	18.2	2.21	44	1	2.3	1	2.3
Molar	31	14	45.2	1.97	51	3	5.9	2	3.9
Subtotal	74	16	21.6		161	4	2.5	3	1.9
<u>Age 35+</u>									
Maxilla									
Incisor	10	4	40.0	2.22	35	3	8.6	1	2.9
Canine	7	1	14.3	2.20	19	2	10.5	1	5.3
Premolar	20	1	5.0	2.56	39	10	25.6	1	2.6
Molar	21	4	19.0	3.0	39	17	43.6	4	10.3
Subtotal	58	10	17.2		132	32	24.2	7	5.3
Mandible									
Incisor	9	1	11.1	2.86	28	10	35.7	0	0.0
Canine	8	2	25.0	2.71	17	4	23.5	1	5.9
Premolar	15	1	6.7	2.93	36	12	33.3	2	5.6
Molar	31	12	38.7	2.21	60	29	48.3	2	3.3
Subtotal	63	16	25.4		141	55	39.0	5	3.5
TOTAL	281	55	19.6		581	92	15.8	15	5.2

The poor oral health of Room 17 individuals is also reflected in the relatively high rate of antemortem tooth loss (15.8 percent). Mandibular teeth in older adults suffer antemortem loss much more often than any other arcade in the samples at a frequency of 39 percent. Conversely, the frequency of abscessing is the lowest among the Room 17 individuals (5.2 percent) (Table G-3). Calculus scores are slightly lower than the Room 26 and Refugio samples.

Dockall (1997) reports very low caries rates for the Ernest Witte (2.7 percent) and the Morhiss (4.2 percent) sites. These populations were archaic hunters and gatherers of the west coastal plain of Texas and would have a similar subsistence base as the historic Karankawa. The occurrence of caries at the Mitchell Ridge site increases significantly from the Prehistoric period to the Historic period (Powell 1994). The

females have higher rates of caries than the males in all of these sites. Refugio also reflects this pattern. Dockall (1997) suggests that this may indicate that females had greater access to cariogenic foods as they gather them. This pattern does not hold for the San Juan Capistrano series where in Room 17 both males and females have approximately 19 percent rate of caries frequency, and in Room 26 the males have a greater rate than females (15.1 percent for males and 11.7 percent for females).

Dental abscesses also occur at a lower rate in the Ernest Witte and Morhiss sites when compared to Refugio. Dockall (1997) found that at both sites less than 6 percent of all observable alveoli displayed evidence of abscesses whereas Refugio has a slightly higher frequency at 8.3 percent. Dockall (1997) and Powell (1994) note that a temporal

decrease in abscess frequency seems to have occurred. Powell suggests that this phenomenon may be the result of the presence of older individuals in the Mitchell Ridge Prehistoric component. The Refugio sample definitely exhibits greater frequencies of abscesses in the older adults (maxillary 12.0 percent, mandibular 13.9 percent) than in the younger adults (5.7 percent and 7.7 percent). Dockall (1997) also suggests that as populations move inland, the frequency of abscessing increases. The San Juan Capistrano samples do not support this idea with abscess frequencies for Room 17 and Room 26 calculated as 5.2 percent and 7.9 percent, respectively. These samples do, however, have much higher caries rates.

Dental Pathology in Children

Table G-4 provides the inventory counts and caries frequencies for the deciduous dentition in the Refugio and San Juan Capistrano Rooms 26 and 17 samples. The information is divided into four age categories, ages birth-6 months, 1-4 years, 5-9 years, and 10-14 years, as well as by arcade and tooth type. The Refugio sample yields the largest number of deciduous teeth ($n = 155$), followed by Room 17 ($n = 42$) and Room 26 ($n = 9$). Table G-4 also provides the number of permanent teeth (numbers in parentheses) for individuals between 10 and 14 years of age. None of these teeth displayed caries, antemortem loss, calculus, or

Table G-4. Dental inventory and pathology in children (birth to 14 years)

ARCADE AND TEETH	REFUGIO MISSION			CAPISTRANO ROOM 17			CAPISTRANO ROOM 26		
	Number Teeth	Number Caries	% Caries	Number Teeth	Number Caries	% Caries	Number Teeth	Number Caries	% Caries
<u>Ages Birth-0.5</u>									
Maxilla									
Incisor	13	0	0.0	0	0	0.0	0	0	0.0
Canine	4	0	0.0	0	0	0.0	0	0	0.0
Molar	8	0	0.0	0	0	0.0	0	0	0.0
Subtotal	25	0	0.0	0	0	0.0	0	0	0.0
Mandible									
Incisor	7	0	0.0	0	0	0.0	0	0	0.0
Canine	3	0	0.0	0	0	0.0	0	0	0.0
Molar	15	0	0.0	0	0	0.0	0	0	0.0
Subtotal	25	0	0.0	0	0	0.0	0	0	0.0
<u>Ages 1-4</u>									
Maxilla									
Incisor	18	2	11.1	5	0	0.0	0	0	0.0
Canine	9	0	0.0	3	0	0.0	0	0	0.0
Molar	19	0	0.0	13	0	0.0	0	0	0.0
Subtotal	46	2	4.3	21	0	0.0	0	0	0.0
Mandible									
Incisor	16	1	6.3	3	0	0.0	0	0	0.0
Canine	7	0	0.0	3	0	0.0	0	0	0.0
Molar	16	2	12.5	10	0	0.0	0	0	0.0
Subtotal	39	3	7.7	16	0	0.0	0	0	0.0
<u>Ages 5-9</u>									
Maxilla									
Incisor	2	0	0.0	0	0	0.0	0	0	0.0
Canine	2	0	0.0	2	0	0.0	1	0	0.0
Molar	3	0	0.0	3	0	0.0	2	1	50.0
Subtotal	7	0	0.0	5	0	0.0	3	1	33.3
Mandible									
Incisor	1	0	0.0	0	0	0.0	0	0	0.0
Canine	2	0	0.0	0	0	0.0	2	0	0.0
Molar	4	0	0.0	0	0	0.0	4	0	0.0
Subtotal	7	0	0.0	0	0	0.0	6	0	0.0
<u>Ages 10-14</u>									
Maxilla									
Incisor	0 (5)	0	0	0	0	0.0	0	0	0.0
Canine	0 (2)	0	0	0	0	0.0	0	0	0.0
Molar	3 (21)	1	3.3	0	0	0.0	0	0	0.0
Subtotal	3 (28)	1	3.3	0	0	0.0	0	0	0.0
Mandible									
Incisor	0 (8)	0	0.0	0	0	0.0	0	0	0.0
Canine	0 (3)	0	0.0	0	0	0.0	0	0	0.0
Molar	2 (20)	0	0.0	0	0	0.0	0	0	0.0
Subtotal	2 (31)	0	0.0	0	0	0.0	0	0	0.0
TOTAL	154	6	3.9	42	0	0.0	9	1	11.1

abscesses. The inventory for premolars and molars is combined under the tooth type molar for these individuals. Because of the large disparity between the samples, it is difficult to adequately compare them. The Refugio deciduous sample does reflect a similar trend in caries frequencies as it does in the adult dentition. The frequency is quite low (3.9 percent), but due to the low number of teeth observed in the other series, comparison is not appropriate. The teeth from Room 17 are not similar to the adult dentition from that series in that no teeth exhibit carious activity. The Room 26 deciduous sample has only one carious tooth.

Clear differences between the three samples are present with regard to oral health. Refugio appears the healthiest with the lowest frequencies of caries and antemortem loss. Room 17 has the poorest oral health as evidenced by the highest frequencies of caries and antemortem loss. Room 26 falls in between these two groups. In order to test whether the differences between the groups are significant, Chi-square tests of significance are employed (Table G-5). The F statistics indicate that the differences are highly significant between the groups.

These results indicate two trends, one temporal and the other subsistence based. The occupation of the Refugio and San Juan missions overlap in time. Traditional subsistence patterns of the groups that comprised the missions were different in that the Karankawa apparently continued to maintain their traditional subsistence behavior. The dental pathology results indicate that this means of subsistence did not change drastically once the Karankawa lived at the Refugio mission. Historical documents indicate the Karankawa would leave the mission if promised food was not provided (Oberste 1942; Ricklis 1996). The oral health of the individuals reflects continuation of the more traditional subsistence means of hunting and gathering.

Room 26 of San Juan Capistrano is the earliest of the samples (1764-1780's) (Francis 1999; Schuetz 1980). The oral health of these individuals suggests that the population was more adapted to a maize or otherwise high carbohydrate diet than the Refugio population. However, Cargill and Hard's (1999) isotope study of 19 individuals from Room 26 indicate that Native American residency at the mission was not long enough to change the isotope signature. "Neither are the elevated $d^{15}N$ values of Mission San Juan residents consistent with historic mission records indicating that maize was an important dietary component for mission residents" (Cargill and Hard 1999:209). Room 17 represents the longest occupation period (1793-1862) and also reflects the worst of oral health. This may indicate the later population of the San Juan Capistrano mission was heavily reliant on the diet traditional to the missions including beef, mutton, corn, beans, and squash (Humphreys 1971).

Another means of examining the oral health is the DM index, which combines caries with antemortem tooth loss. Kelley et al. (1991) suggest that the DM index "provides a more comprehensive estimation of dental health..." (p. 205). For the Refugio sample, the DM index was calculated for the young adults by sex, older adults by sex, all ages by sex, and then the total sample (Table G-6). The DM index is calculated as:

$$(\text{Total number of carious teeth} + \text{total number of antemortem tooth loss}) / (\text{total number of teeth} + \text{total number of antemortem tooth loss}) \times 100.$$

High scores indicate poorer oral health. Females overall have a higher score than do males.

Table G-5. Results of significant tests for differences in caries frequencies between groups

Sample	Teeth without caries	Teeth with caries	Unaffected sockets	Antemortem loss	Unaffected sockets	Number of abscesses
Refugio	1303	124	1105	95	1101	99
Rm17	226	55	489	92	566	15
Rm26	374	58	591	83	621	53
	$X^2 = 31.275$ df=2 P < 0.001		$X^2 = 26.719$ df=2 P < 0.001		$X^2 = 21.489$ df=2 P < 0.001	

Table G-6. DM Index for Refugio adults

	Young Males	Young Females	Older Males	Older Females	Males	Females	ALL
Total Teeth	485	493	325	119	810	612	1427
Carious Teeth	22	44	43	15	65	59	124
Antemortem Loss	4	1	42	46	46	47	95
DM Index	5.316973	9.109312	23.16076	36.9697	12.96729	16.08498	14.38896

Dental Wear

Following Smith (1984), dental wear was scored for all individuals with available dentition. Figures G-1 and G-2 give the plots of the average wear for males and females from Refugio. Table G-7 gives the results of the Kruskal-Wallis tests for differences in male and female wear patterns for the maxillary dentition, and Table G-8 presents the tests for the mandibular dentition. The non-parametric Kruskal-Wallis test is utilized in this analysis because it is robust in situations of non-normally distributed data and small sample sizes.

Results of the Kruskal-Wallis tests show males and females differ systematically with respect to the posterior dentition, with males showing a higher degree of wear in these teeth. The anterior portion of the dental arcade shows no statistically significant difference between males and females.

Such a pattern of lower female wear is supported by the higher mortality of young females than young males in the skeletal sample (see Demography section). The pattern could also symbolize the female segment of the population having a generally softer diet. This possibility is not supported by

the caries frequencies however (female 10.6 percent, male 8.7 percent, $X^2 = 1.14$, $p = .285$).

In comparison to other Texas coastal hunter-gatherer samples, the Refugio sample has relatively light dental wear. Figures G-3 and G-4 give the comparison of Refugio to the Ernest Witte site and the Morhiss site. The Ernest Witte site is an inland multicomponent site which spans the Late Archaic to the Historic periods, with the majority of burials identified as Late Archaic (Dockall 1997). The Morhiss site is an Archaic period site closer in proximity to the coast than Ernest Witte. Both of these sites represent a seasonal, hunter-gatherer subsistence pattern. As seen in both of the figures, the Refugio sample has systematically lower wear than both the Ernest Witte and Morhiss samples. The difference between Refugio and Ernest Witte is more pronounced than the difference between Refugio and Morhiss. These differences could likely stem from one of two causes: 1) The Refugio sample as a whole has a lower average age-at-death than the Archaic period sites, or 2) During the Mission period, enough of a dietary shift toward a soft-food diet occurred to lessen the overall amount of dental wear. The first possibility does not seem to be

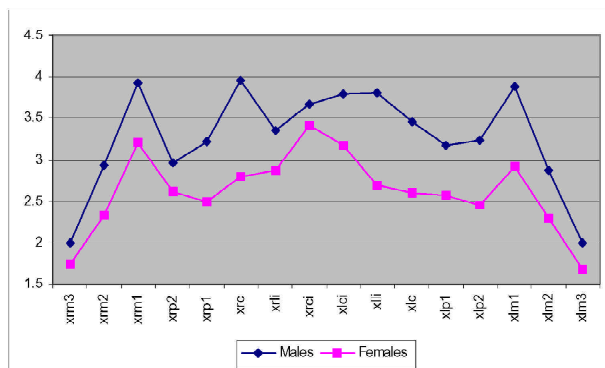


Figure G-1. Maxillary average wear scores for Refugio males and females.

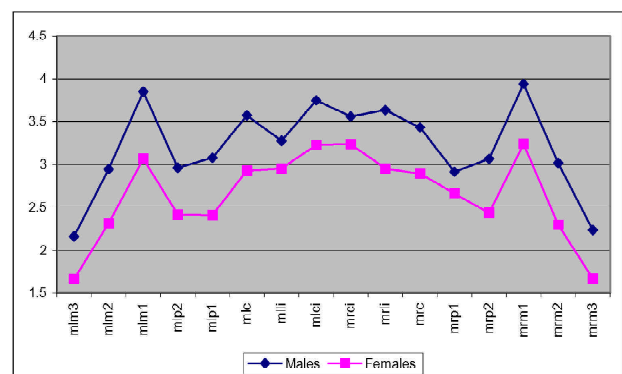


Figure G-2. Mandibular average wear scores for Refugio males and females.

Table G-7. Results of Kruskal-Wallis Tests for male-female wear scores: maxillary dentition

Tooth Type	Male Average Wear (N)	Female Average Wear (N)	X^2*	p
RM3	2.00 (18)	1.74 (19)	.05	.81
RM2	2.93 (27)	2.33 (21)	4.51	.03
RM1	3.93 (28)	3.21 (24)	4.25	.04
RP2	2.96 (26)	2.62 (21)	1.49	.22
RP1	3.22 (23)	2.50 (18)	5.88	.01
RC	3.96 (25)	2.80 (15)	5.44	.02
RLI	3.35 (20)	2.88 (16)	1.59	.21
RCI	3.67 (18)	3.41 (17)	.31	.58
LCI	3.79 (19)	3.18 (17)	2.61	.11
LLI	3.81 (16)	2.68 (19)	2.49	.11
LC	3.45 (22)	2.60 (15)	4.19	.04
LP1	3.17 (24)	2.57 (21)	3.75	.05
LP2	3.23 (26)	2.45 (22)	6.87	<.01
LM1	3.89 (27)	2.91 (23)	8.89	<.01
LM2	2.87 (30)	2.30 (20)	4.90	.02
LM3	2.00 (21)	1.69 (16)	.61	.43

*The X^2 tests are all with 1 degree of freedom.

Table G-8. Results of Kruskal-Wallis Tests for male-female wear scores: mandibular dentition

Tooth Type	Male Average Wear (N)	Female Average Wear (N)	X^2*	p
LM3	2.18 (28)	1.70 (20)	3.97	.05
LM2	2.96 (27)	2.33 (24)	6.89	<.01
LM1	3.87 (30)	3.08 (24)	9.02	<.01
LP2	3.00 (23)	2.45 (20)	2.91	.08
LP1	3.10 (29)	2.45 (22)	5.18	.02
LC	3.60 (25)	3.00 (17)	3.83	.05
LLI	3.32 (25)	3.00 (17)	.01	.89
LCI	3.79 (19)	3.29 (14)	.62	.43
RCI	3.61 (18)	3.29 (17)	.08	.78
RLI	3.67 (27)	3.00 (20)	2.43	.12
RC	3.46 (28)	2.95 (19)	2.16	.14
RP1	2.94 (31)	2.71 (24)	.67	.41
RP2	3.11 (28)	2.47 (19)	2.81	.09
RM1	3.96 (28)	3.26 (23)	6.21	.01
RM2	3.04 (26)	2.32 (22)	7.44	<.01

*The X^2 tests are all with 1 degree of freedom.

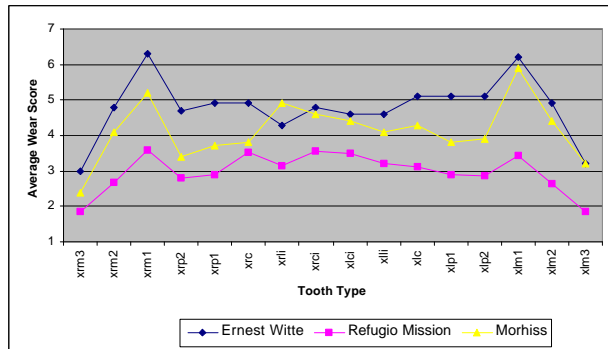


Figure G-3. Comparison of Ernest Witte, Morhiss, and Refugio maxillary dental wear.

plausible, due to the high percentage of young adults present at both the Ernest Witte and Morhiss sites (Dockall 1997). Previously, Smith (1984) found higher rates of wear among hunter-gatherer groups than among agriculturalists. Records indicate (Oberste 1942) that the Karankawa would live at the mission when food supplies were ample and leave for the coast when crop production/food availability was low. If the amount of time spent at the mission was long enough, or if the skeletal sample itself is more representative of individuals living solely at the mission then the pattern observed here makes sense. The latter would have to be the more parsimonious answer because as Ricklis (1996) points out, the Karankawa did not cease their traditional subsistence strategy, but adapted to the mission as another resource on the landscape.

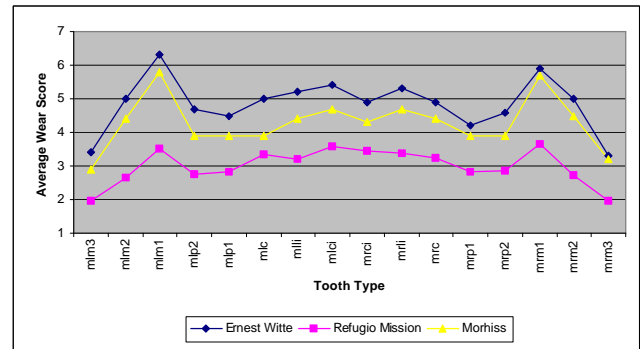


Figure G-4. Comparison of Ernest Witte, Morhiss, and Refugio mandibular dental wear.

Enamel Chipping

The presence of enamel chipping is indicative of diet and perhaps behavior. Enamel chipping is literally fracturing of the dental enamel resulting from biting or chewing on hard particles that are associated with particular foods. An example is the inclusion of small pieces of shell consumed in a high shellfish diet. During the analysis of the dentition of the Refugio series, the presence of enamel chipping was noted (Plate G-4).

Table G-9 presents the profile of adult individuals with observable dentition. Of the seventy individuals that have dentition present, 47 percent exhibit some degree of enamel chipping. Included in the table is a general description of individuals with chipped enamel. Males tend to exhibit damaged teeth more often than females (55 percent males

Table G-9. Profile of individuals with dentition

Age	Females	Females with chipped enamel	Males	Males with chipped enamel
15-34	20	9 (45%)	24	12 (50%)
35+	8	2 (25%)	20	9 (45%)
Totals	28	11 (39%)	42	23 (55%)

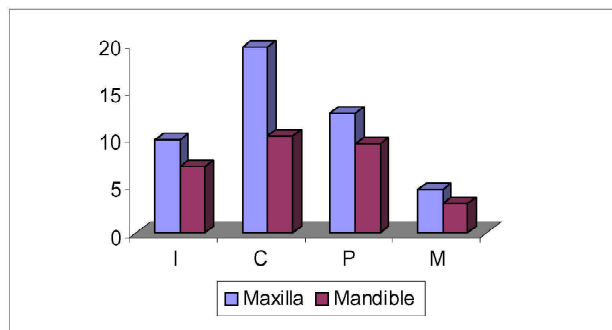


Figure G-5. Enamel chipping in adults 15-34 years.

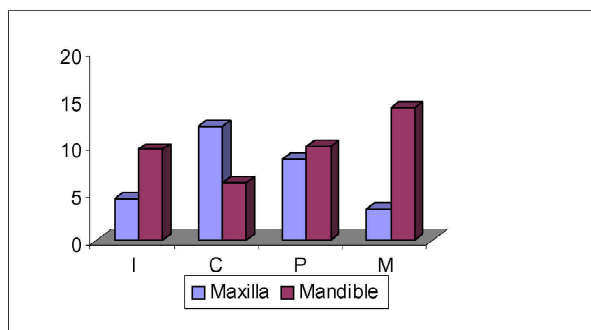


Figure G-6. Enamel chipping in adults 35+ years.

Table G-10. Inventory of teeth exhibiting enamel chipping by tooth type

ARCADE AND TEETH	Number Teeth	Number Teeth Enamel Chipping	% Chipped
Age 15-34			
Maxilla			
Incisor	103	10	9.7
Canine	51	10	19.6
Premolar	126	16	12.7
Molar	194	10	5.2
Subtotal	474	56	11.8
Mandible			
Incisor	99	7	7.0
Canine	58	6	10.3
Premolar	126	12	9.5
Molar	202	6	3.0
Subtotal	485	31	6.4
Age 35+			
Maxilla			
Incisor	45	2	4.4
Canine	26	3	11.5
Premolar	58	5	8.6
Molar	92	3	3.3
Subtotal	221	13	5.9
Mandible			
Incisor	52	5	9.6
Canine	32	2	6.3
Premolar	71	7	9.9
Molar	92	13	14.1
Subtotal	247	27	10.9
TOTAL	1427	125	8.8

and 39 percent in females). Table G-10 presents frequencies of enamel chipping by arcade and tooth type for young and older adults. Of the 1,427 teeth examined, 8.8 percent exhibited some degree of enamel chipping. Young adults exhibit enamel chipping more frequently in the maxillary teeth (11.8 percent) than in the mandibular teeth (6.4 percent). The older adults show a reverse of this with the mandibular dentition having a higher frequency of chipped teeth (10.9 percent) than the maxillary teeth (5.9 percent).

Figures G-5 and G-6 provide graphic depictions of the frequency of enamel chipping by tooth type and arcade for

each of the major age groups. Although the older adults have a lower rate of damage for the maxillary teeth than the younger adults do, a pattern is present in both age groups. The canine is the most frequently damaged tooth, while the molars are the least damaged teeth; however, the mandibular teeth of older adults show a reversal of the pattern of damage. The young adults exhibit the most frequent damage to the canine and the least affected are the molars. The pattern for the mandibular teeth in young adults follows the pattern for the maxillary teeth. However, for the mandibular teeth of older adults, the most frequently damaged tooth type is the molar and the least frequently damaged is the canine. The

Refugio population exhibits a relatively high frequency of enamel chipping. The mostly likely cause of this damage is diet. The Karankawa were coastal people that most likely exploited the shellfish that were available as a food source. The high incidence of chipping supports the claim that the Native American groups at the Refugio mission continued the traditional subsistence pattern of hunting, fishing, and gathering. Enamel chipping was noted in two individuals in the Capistrano samples. Humphreys (1971:36) notes that “some Coahuiltecan chipping was observed under the binocular dissecting microscope...” The vastly different rates of this enamel damage between the two mission samples suggests that the San Juan Capistrano populations were more likely dependent on the mission food.

Linear Enamel Hypoplasia

Developmental defects of dental enamel known as linear enamel hypoplasias have been linked to a variety of systematic metabolic stressors, localized trauma, and hereditary anomalies. The defects form when ameloblasts are disrupted during the enamel matrix formation phase of dental growth and development, forming linear bands, pits, or grooves on the surface of the enamel (Goodman and Rose 1990; Plate G-5). Linear enamel hypoplasias (LEH), therefore, provide a record of stress events on an individual

basis. The presence of hypoplasias allows researchers to say that individuals definitely experienced some non-specific stress event during their development. In addition, the more defects, which appear on individual teeth, indicate the more stress episodes the individual lived through (Storey 1997). Population level studies of hypoplasias have focused on the effects of dietary, climatic, and social conditions that affect disease patterns and human development (Larsen 1997).

The Refugio series offers an excellent opportunity to explore the patterning of enamel hypoplasia. Due to the disparity of many other classical physiological stress markers such as porotic hyperostosis and cribra orbitalia in this series, LEH are perhaps the best evidence to evaluate the physiological and environmental stress load in this population. In addition, the written accounts of epidemic disease, population pressure, and available demographic information allow for patterns of hypoplasias to be compared with direct historical records.

Age of defect formation was calculated for linear hypoplastic defects on the maxillary and mandibular incisors, canines, premolars, first and second molars. Only linear type defects were used in these calculations because the etiology is better understood compared to the other types of defects. Wright's (1997) regression formulae were used to estimate age of formation because the tooth size and developmental rate in

Table G-11. Frequency of hypoplasia by tooth type

Tooth Type	Number of Teeth	Teeth with Defect	Frequency
<i>Maxillary</i>			
I1	69	49	.710
I2	73	42	.575
C	73	54	.739
P1	84	34	.404
P2	92	29	.315
M1	105	24	.230
M2	96	23	.240
M3	73	9	.123
Total	665	264	.396
<i>Mandibular</i>			
I1	65	31	.477
I2	79	38	.481
C	81	64	.790
P1	102	35	.343
P2	93	27	.290
M1	105	25	.238
M2	103	27	.262
M3	88	12	.136
Total	716	259	.361

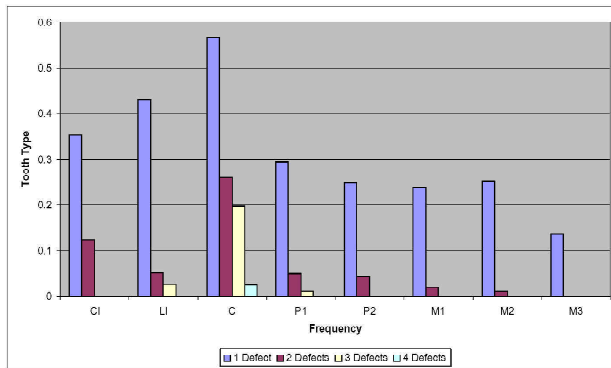


Figure G-7. Plot of hypoplasia frequency by maxillary tooth type.

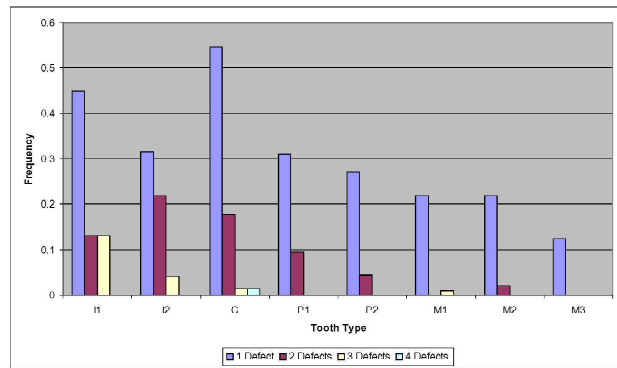


Figure G-8. Plot of hypoplasia frequency by mandibular tooth type.

the Maya sample are better suited to this sample as opposed to the European-derived formulae in Goodman and Rose (1990). Results of the dental biodistance analysis indicate the multivariate proximity of the Refugio and Maya samples, confirming the similarity of tooth sizes between the samples, while several European samples are quite easily distinguished from both the Maya and Refugio samples.

Frequencies of teeth showing at least one hypoplasia by tooth type for the maxillary and mandibular dentition are presented in Table G-11. Frequencies of multiple defects by tooth type

for the maxillary and mandibular dentition are illustrated in Figures G-7 and G-8. The frequencies of maxillary and mandibular central ($X^2 = 7.57$, $p = .006$, $df = 1$) and lateral incisor LEHs ($X^2 = 7.98$, $p = .005$, $df = 1$) differ significantly. While all other LEH frequencies are consistent between the maxilla and mandible.

This pattern is more dramatic than results given by other researchers (El-Najjar et. al 1978; Goodman and Rose 1990), who cite only a slight differential in the frequencies of defects in a cross-cultural comparison. Black (1979) and

Table G-12. Frequency of hypoplasia by sex and tooth type

Tooth Type	Females	Males	X^2	p
<i>Maxillary</i>	Affected/N (%)			
I1	23/32 (71.8)	23/34 (67.7)	.14	.708
I2	15/36 (41.6)	17/34 (50.0)	.49	.484
C	22/29 (75.9)	33/38 (86.8)	1.34	.245
P1	15/35 (42.8)	14/45 (31.1)	1.12	.278
P2	13/36 (36.1)	11/49 (22.5)	1.91	.167
M1	11/46 (23.9)	11/48 (22.9)	.01	.909
M2	12/43 (27.9)	8/50 (16.0)	1.94	.163
<i>Mandibular</i>				
I1	13/28 (46.4)	13/29 (44.8)	.01	.903
I2	19/36 (52.8)	15/38 (39.5)	1.32	.251
C	27/35 (81.8)	30/46 (65.2)	2.63	.104
P1	22/44 (50.0)	22/55 (40.0)	.99	.319
P2	20/39 (51.3)	6/49 (12.2)	15.89	<.0001
M1	18/46 (39.1)	3/51 (5.9)	15.76	<.0001
M2	16/45 (35.5)	10/53 (18.9)	3.48	.062

Goodman and Armelagos (1985), however, found significant differences in the frequencies of defects between tooth types, most noticeably the maxillary and mandibular central incisor. This pattern fits the previous notions of differential susceptibility of the anterior dentition, especially the maxillary teeth as noted by Goodman and Rose (1990).

One interesting pattern that is present in this series is the differential patterning of hypoplasias between adult males and females. Females (46 percent) display a significantly ($X^2 = 24.78$, $p < .0001$, $df = 1$) higher frequency of hypoplasias across all tooth types than males (33 percent). There is a marginally significant difference in the mandibular canine (males 65 percent, females 82 percent, $X^2 = 2.64$,

$p = .1$, $df = 1$) and mandibular second molar (males 18.9, females 35.5, $X^2 = 3.48$, $p = .062$, $df = 1$), a marked difference in the mandibular second premolar (males 12 percent, females 51 percent, $X^2 = 15.9$, $p < .0001$, $df = 1$) and mandibular first molar (males 6 percent, females 39 percent, $X^2 = 15.8$, $p < .0001$, $df = 1$). The female frequencies are consistently higher in the mandibular dentition, while not always so in the maxillary dentition. Table G-12 lists frequencies by tooth type and X^2 tests of significance.

Šlaus (2000) found similar patterns in a Late Medieval sample from Croatia, but observations were limited to the anterior dentition. A similar pattern exists in many archaeological samples from North America, as well as

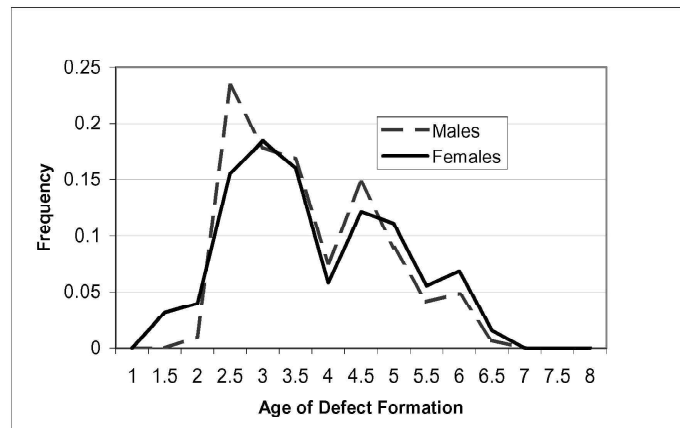


Figure G-9. Age distribution of hypoplasia formation for all teeth.

Table G-13. Mean age of defect formation by sex and tooth type

Tooth Type	Female			Male			t	p
Maxillary	Age mean	(s.d)	N	Age mean	(s.d)	N		
I1	3.24	(.348)	16	2.93	(.350)	17	-2.54	.016
I2	3.72	(.282)	12	3.50	(.305)	14	-1.82	.081
C	4.92	(.317)	13	4.57	(.546)	16	-2.11	.043
P1	5.03	(.245)	10	5.07	(.371)	10	-1.59	.129
P2	5.28	(.267)	9	4.93	(.359)	8	-2.25	.039
M1	2.67	(.242)	7	2.70	(.251)	8	.28	.783
M2	6.18	(.438)	8	6.04	(.574)	6	-.53	.605
Mandibular	Age mean	(s.d)	N	Age mean	(s.d)	N		
I1	3.04	(.371)	8	2.93	(.274)	9	-.68	.509
I2	3.06	(.313)	11	2.89	(.224)	10	-1.52	.145
C	3.65	(.312)	16	3.34	(.354)	22	-2.80	.008
P1	4.95	(.542)	12	4.71	(.602)	9	-.96	.351
P2	5.71	(.742)	11	6.02	(.255)	7	1.27 ^a	.225
M1	2.82	(.243)	11	2.85	(.193)	3	.23	.820
M2	6.16	(.285)	10	6.25	(.131)	8	0.88 ^a	.397

^aSatterthwaite's approximation used to adjust for unequal variances.

historic period samples, with females exhibiting higher frequencies of hypoplasias in many cases (Guatelli-Steinberg and Lukacs 1999).

One possible explanation for the lower male frequencies in the mandibular molars lies in the greater amount of wear on those teeth compared to females (right side, $t = 2.64$, $p = .01$; left side, $t = 3.20$, $p = .002$), these factors, however, are not present in the lower premolars.

Utilizing the regression formulae provided by Wright (1997), ages of defect formation were calculated for linear defects on the maxillary and mandibular incisors, canines, premolars, and first and second molars. Figure G-9 presents the distribution of the age of formation for the first defect for adult males and females.

This tri-modal distribution represents the different timing of defects between tooth types. Table G-13 lists the mean age of formation for the first defect for each tooth type, results of the t-tests and associated p-values for the comparison of males to females. In order to maintain the protocol of Wright, her minimum scorable age limit was strictly followed (see Wright 1997:Table 1). Any defects that fell below the minimum scorable age were not included in this portion of the analysis.

Females display significantly older ages of development for several maxillary teeth, and the mandibular canine. This pattern indicates that on teeth that tend to be more susceptible to defect formation, (maxillary incisors, maxillary and mandibular canines [Goodman and Rose 1990]) females are generally being affected by nutritional or environmental stressors later in childhood. For the teeth that show significant differences between sexes, females, on average, are developing hypoplasias 3.7 months later than males. Timing between defects, however, shows no significant difference between sexes ($t = -0.64$, $p = .263$, $df = 133$), with females averaging 5.9 months between defect formation and males averaging 5.5 months. This pattern coincides well with the mortality distribution at Refugio, with a six-month differential in the low and high points of mortality in the parish burial record (Oberste 1942), and could reflect a seasonal susceptibility of children to environmental stress.

The trend observed in older age of hypoplasia formation in females coincides with the higher frequency of defects in females, and could indicate differential susceptibility between the sexes. Guatelli-Steinberg and Lukacs (1999) cite cultural factors such as preference for male children in

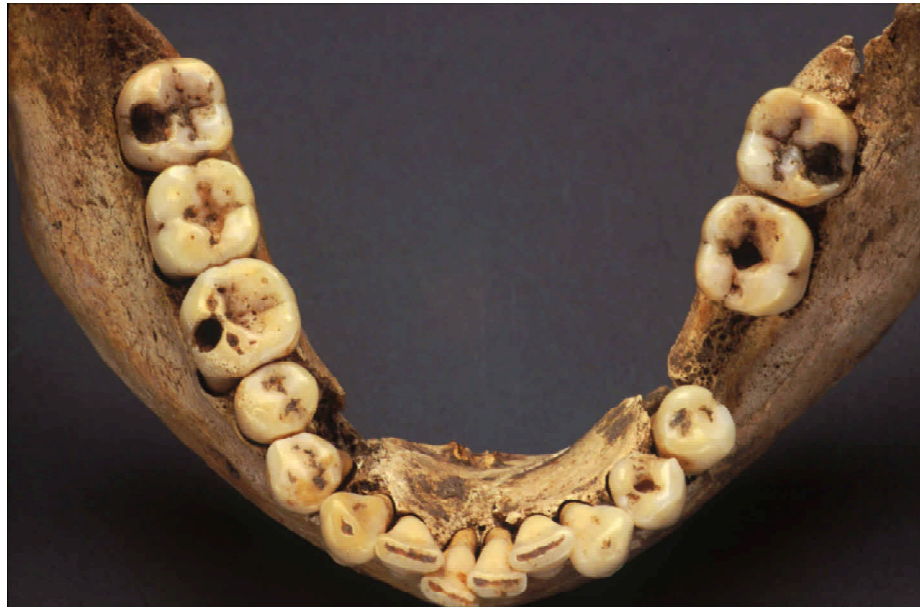nutritionally stressed populations. This would put females in a position of higher stress levels during times of increased environmental stress. The population at Refugio was repeatedly placed in situations, including but not limited to, smallpox outbreaks, inter-personal violence, and poor crop production (Oberste 1942).

Summary

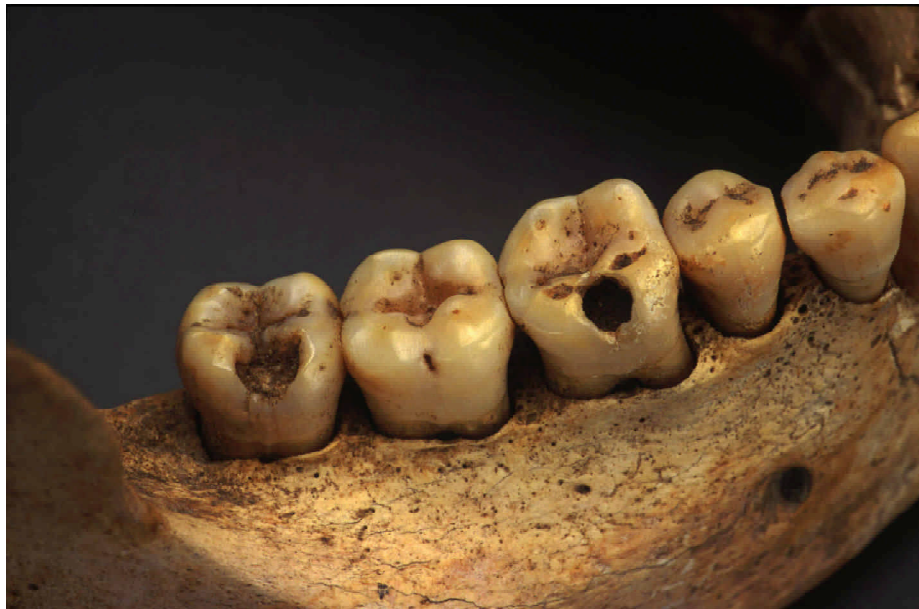Analysis of dental pathology provides an opportunity to examine the oral health, diet, and perhaps behavioral aspects of a population. The oral health of the Refugio population is relatively good. When looking at the disease processes of the oral structure including caries, abscesses, and antemortem tooth loss, frequencies of these are low especially when compared to the San Juan Capistrano samples. A slight temporal trend is evidenced in the increase in caries frequency as the later sample, Room 17, exhibits the highest caries frequency.

Other dental indicators such as wear and enamel chipping provide evidence for diet and perhaps behavior. Dental attrition was discussed for the Refugio sample. The most distinct pattern was that the males exhibit greater wear in the anterior teeth than do females, while there is no sex difference in the posterior dentition. When compared to the Archaic hunter and gathers from the Morhiss and Ernest Witte sites, the Refugio population exhibits less attrition. This may reflect more strenuous food preparation or processing during the historic period. Enamel chipping, however, occurs at a rather high frequency with 47 percent of individuals with teeth exhibiting some evidence of chipping. This most likely reflects utilization of the shellfish found in the coastal environment. Unfortunately, comparative samples from the Texas region were not available for this analysis.

The final dental indicator of health examined was linear enamel hypoplasia (LEH). Linear enamel hypoplasias have been linked to a variety of systematic metabolic stressors, localized trauma, and hereditary anomalies. Two patterns were discerned from the Refugio sample. The males generally have lower frequencies of LEH than females, and the females were older at the time of development of the defects. These patterns may reflect preferential resources for male children during periods of low resources. The patterns of age at development seem to coincide with seasonal mortality. However, as previously mentioned, actual causes of LEH are not known.

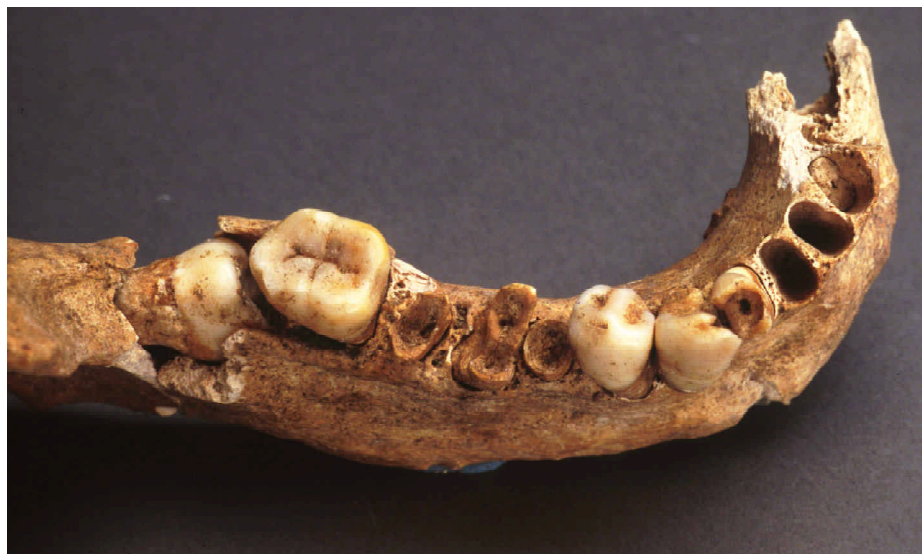

41RF1-BP15-052

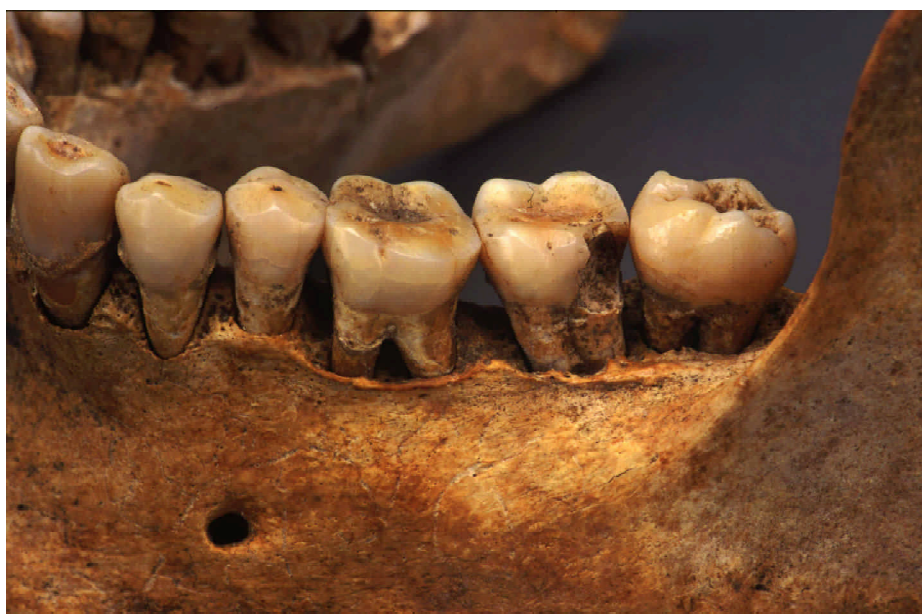

41RF1-BP15-052

Plate G-1. *Examples of carious lesions.*



41RF1-BP22-082

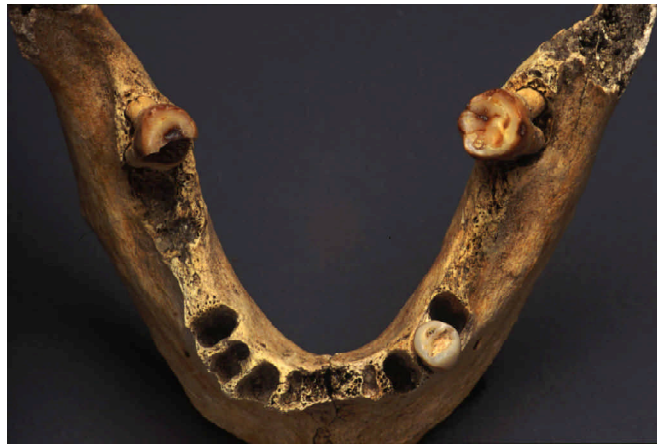

41RF1-BP26-125

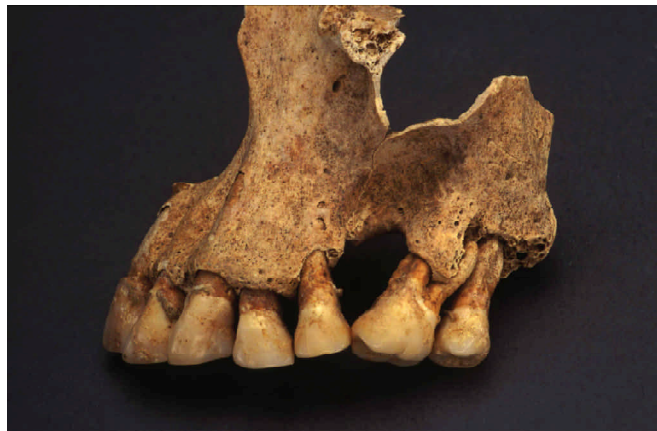Plate G-1. *continued.*



41RF1-BP21-069

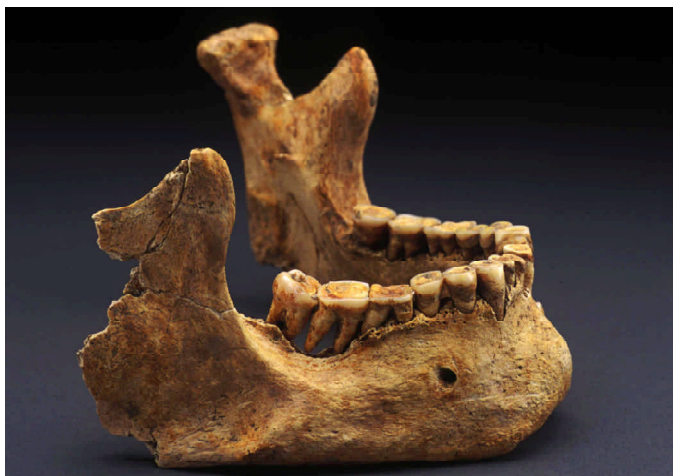

41RF1-BP04-021

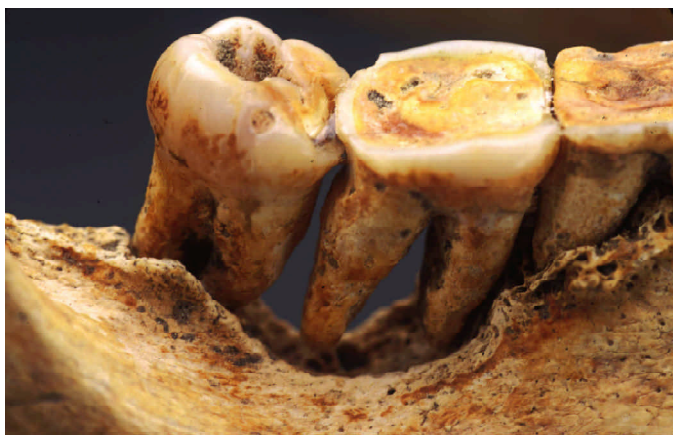

41RF1-BP26-125

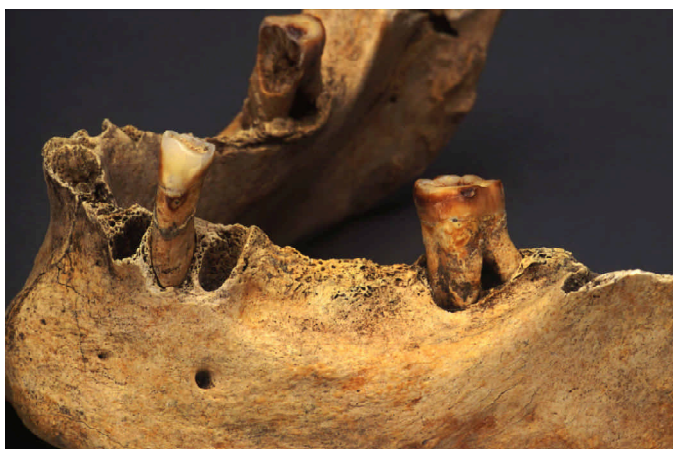Plate G-2. *Examples of antemortem tooth loss.*



41RF1-BP22-077

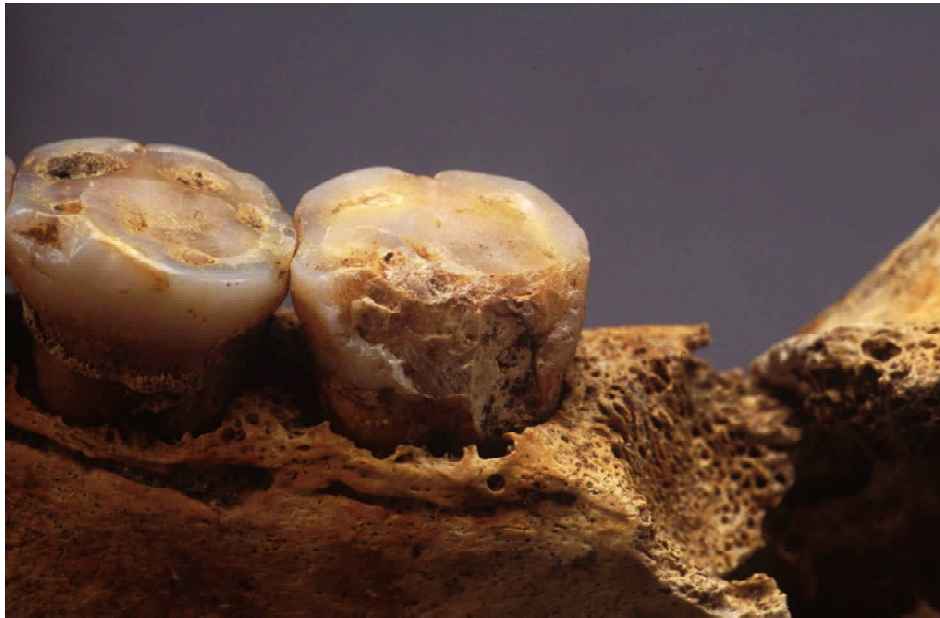

41RF1-BP22-077



41RF1-BP04-021

Plate G-3. Examples of abscesses.



41RF1-BP16-083

Plate G-4. Example of enamel chipping.



41RF1-BP11-054

Plate G-5. Linear enamel hypoplastic defects on maxillary incisors.

Osteological Analyses

Section H

Dental Metrics and Morphology

Dental measurements have been employed by many researchers to gain insight into a number of evolutionary and population distance analyses. The genetic basis of the dentition has been established for many groups using standard quantitative genetic methods of heritability estimation (see Kieser 1990). This genetic basis allows dental measurement to act as a tool for population structure analyses (O'Rourke and Crawford 1980) as well as studies of group migration (Sciulli 1979) and cultural change.

Dental metric analyses are employed in the Refugio skeletal series to answer a variety of questions. Dental metrics are used to aid in sex determination of individuals of unidentifiable sex (sub-adults and highly fragmentary individuals). The dentition is also employed to help surmise the ancestry of individuals that, due to extraneous circumstances, are otherwise unidentifiable. Along the same lines, the dentition is employed in a bio-distance analysis of the Refugio population relative to a variety of comparative samples of European, Native American, and Hispanic samples available from published literature.

Methods

All available dental remains were measured according to the protocols established in Buikstra and Ubelaker (1994) and Keiser (1990). The following three crown dimensions were collected from each tooth:

1. Maximum mesio-distal diameter (crown length);
2. Maximum buccal-lingual diameter (crown width); and
3. Maximum crown height taken from the mid-point of the cemento-enamel junction (CEJ).

While Buikstra and Ubelaker (1994) suggest taking measures on only the left element of the dental arcade, both sides were recorded, when available. All measurements were taken in millimeters with needlepoint digital calipers accurate to .01 mm. Teeth with severe attrition or ante/post-mortem breakage were not measured. Likewise, when the CEJ was not clear due to extreme calculus development or breakage, crown heights were not recorded. Molar crown heights were recorded from the CEJ to the occlusal surface of the mesio-buccal cusp, or if the mesio-buccal cusp was

damaged or unclear, the height was recorded from the distal-buccal cusp.

For all individuals with permanent dentition present, dental morphological characteristics were scored for the crowns and roots following the protocol set forth in Turner et al. (1991). The following list of morphological features were observed:

1. Winging (UI1)
2. Shoveling (UI1, UI2, UC, LI)
3. Double shoveling (UI1, UI2, UC, UP1)
4. Labial convexity (UI1)
5. Peg-shaped incisor (UI2)
6. Interruption groove (UI1, UI2)
7. Tuberculum dentale (UI1, UI2, UC)
8. Mesial ridge (UC)
9. Distal accessory ridge (UC, LC)
10. Mesial and distal accessory cusps (UP1, P2)
11. Uto-Aztec Premolar (UP1)
12. Metacone (UM1, UM2, UM3)
13. Hypocone M1, UM2, UM3)
14. Metaconule (UM1, UM2, UM3)
15. Carabelli's trait (UM1, UM2, UM3)
16. Parastyle (UM1, UM2, UM3)
17. Enamel extensions (upper and lower premolars and molars)
18. Premolar root number (UP1, UP2)
19. Upper molar root number
20. Peg-shaped molar (UM3)
21. Odontome (Upper and lower premolars)
22. Congenital absence (UI1, UI2, LI1, LI2, UP2, LP2, UM3, LM3)
23. Lingual cusp variation (LP1, LP2)
24. Anterior fovea (LM1)
25. Lower molar groove pattern (LM1, LM2, LM3)
26. Lower molar cusp number (LM1, LM2, LM3)
27. Deflecting wrinkle (LM1, LM2, LM3)
28. Distal trigonid crest (LM1, LM2, LM3)
29. Protostylid (LM1, LM2, LM3)
30. Cusp 5 form (LM1, LM2, LM3)
31. Cusp 6 form (LM1, LM2, LM3)
32. Cusp 7 form (LM1, LM2, LM3)
33. Canine root number (LC)
34. Tome's root (LP1)
34. Lower molar root number (LM1, LM2, LM3)

Descriptions of these traits can be found in Turner et al. (1991), and Scott and Turner (1997). In many cases, attrition had obscured the traits of interest. In such cases, the traits were scored as missing data.

Results

Due to attrition factors, mesio-distal and crown height diameters were excluded from subsequent analysis. Table H-1 presents the summary statistics for the adult buccal-lingual crown diameters and tests for sexual dimorphism.

There exists clear sexual dimorphism in all teeth except the mandibular incisors. The most dimorphic teeth are the maxillary first premolar, first molar and the mandibular canine. This pattern of dimorphism is consistent with other studies of sexual dimorphism in modern humans (Hillson 1996).

Several individuals with permanent dentition were identified as indeterminate sex during the skeletal analysis. Due to the often highly fragmentary nature of these individuals, post-cranial metric data were unavailable. Discriminant functions were developed to aid in the identification of sex for these

indeterminate individuals. Table H-2 lists the burial numbers, posterior probabilities, and discriminant function details.

The remaining sample was likewise subjected to a sex discriminant function. The best combination of variables is the maxillary canine and second premolar. The discriminant function based on these two variables produced a jackknifed classification rate of 83.2 percent (21/23, 91.3 percent males; 12/16, 75 percent females correctly classified). These results are better than those of Jacobi's (1994) (63.6 percent correct) who used a similar function, and comparable to the results of Owsley (1982) (91.5 percent correct) who used a more biased resubstitution method of classification.

Biodistance Analysis

In order to understand the Refugio population as a whole, the sample was compared to other populations from North America and Europe. The goal of this analysis is to assess the biological proximity of the Refugio sample as a whole to other Native American samples, as well as Hispanic and European samples. Table H-3 lists the pooled-sex buccal-lingual means, sample sizes and sources for the samples used in the multivariate analysis. Mahalanobis squared

Table H-1. Summary statistics and tests of sexual dimorphism

Tooth	Male Mean (N)	Male s^2	Female Mean (N)	Female s^2	T	p
<i>Maxillary</i>						
I1	7.39 (22)	.09	7.13 (19)	.25	2.29	.03
I2	6.71(22)	.19	6.23 (22)	.51	2.22*	.03
C	8.91 (24)	.11	8.13 (16)	.69	3.59*	.002
P1	9.84 (27)	.26	9.39 (21)	.48	2.60	.013
P2	9.65 (29)	.21	9.08 (23)	.41	3.68	.0006
M1	11.93 (29)	.23	11.38(25)	.46	3.48	.001
M2	11.91 (31)	.39	11.39 (22)	.91	2.22*	.033
M3	11.34 (22)	.92	10.71 (22)	.79	2.29	.027
<i>Mandibular</i>						
I1	5.84 (21)	.07	5.68 (13)	.15	1.45	.158
I2	6.28 (27)	.11	6.25 (22)	.22	.27	.785
C	8.07 (27)	.18	7.59 (20)	.25	3.53	.001
P1	8.16 (34)	.22	7.81 (24)	.25	2.70	.009
P2	8.27 (29)	.20	7.91 (23)	.29	2.58	.013
M1	11.18 (31)	.28	10.68 (26)	.49	3.03	.004
M2	10.84 (30)	.29	10.27 (24)	.64	3.01*	.004
M3	10.74 (27)	.72	10.26 (26)	.72	2.04	.002

*Satterthwaite's (1946) approximation used to adjust for unequal variances.

Table H-2. Discriminant function results for indeterminate sex individuals

Feature	Burial	Predicted Sex	Posterior Probability :Male	Posterior Probability :Female	Teeth in Function	Percentage Correctly Classified
05	034	Male	.6248	.3652	Max M1	75% Male, 52% Female
14	051	Female	.3868	.6132	Max I1, P1, M1	64% Male, 56% Female
16	083B	Male	.7907	.2093	Man P2	76% Male, 61% Female
17	074	Male	.9394	.0606	Max C	87% Male, 63% Female
17	071	Male	.7276	.2724	Man M1, Max M1	74% Male, 58% Female
34	108A	Female	.0849	.9151	Max C	87% Male, 63% Female
34	108	Male	.7070	.2930	Max M1	75% Male, 52% Female
38	136	Female	.7331	.2669	Man P2	76% Male, 61% Female

distances were derived using a program developed by Richard Jantz and Corey Sparks for the above samples using the traditional formula:

$$D^2 = (x_i - x_j) \Sigma^{-1} (x_i - x_j)'$$

Where x_i and x_j represent the i^{th} and j^{th} group means, and Σ is a pooled variance-covariance matrix. The variance-covariance matrix is derived from a sample of 322 African-American and Native American individuals from the Standardized Osteological Database (S.O.D; Rose 1999),

50 individuals from the Averbuch site (unpublished data), a Mississippian period village cemetery from Tennessee, and 49 individuals from Refugio. This large and diverse sample was used in order to provide an unbiased estimate of the baseline variability for these tooth dimensions. Table H-4 gives the resulting Mahalanobis D^2 values for the comparative samples.

A principal coordinates analysis (PCA) was performed on the above distance matrix. PCA takes half of each distance, then subtracts the row and column means from each element, then adds on the grand mean to each distance.

Table H-3. Comparative samples used in biodistance analysis

Group (abrev.) (N)	I1 bl	I2 bl	C bl	P1 bl	P2 bl	M1 bl	Source
Pecos Pueblo (PP) (85)	7.3	6.46	8.36	9.89	9.18	11.54	Nelson (1938)
Indian Knoll (IK) (50)	7.23	6.58	8.51	9.86	9.43	11.68	Perzigian (1976)
Ohio Valley Adena (OVA) (26)	6.97	6.26	8.45	9.57	9.27	11.73	Sciulli (1979)
Ohio Valley Glacial Kame (OVG) (18)	7.12	6.41	8.56	9.56	9.42	11.99	Sciulli (1979)
Ohio Valley Hopewell (OVH) (19)	6.98	6.29	8.39	9.43	9.27	11.74	Sciulli (1979)
Refugio Mission (RF) (48)	7.26	6.53	8.63	9.66	9.41	11.75	Present Study
Tipu Maya (TM) (163)	7.14	6.31	8.49	9.34	9.16	11.64	Jacobi (1996)
Mexico-Cuanalan (MC) (39)	7.1	6.4	8.06	9.33	9.32	11.2	O'Rourke and Crawford (1980)
Mexico-Salttillo (MS) (43)	7.07	6.19	8.03	8.95	8.96	11.01	O'Rourke and Crawford (1980)
Mexico-San Pablo (MSP) (30)	7.24	6.31	8.12	9.14	9.18	11.27	O'Rourke and Crawford (1980)
Mexico-Tlaxcala (MT) (21)	7.14	6.32	8.27	9.05	9.11	11.19	O'Rourke and Crawford (1980)
German (GR) (27)	7.13	6.46	8.23	8.75	9	11.3	Hanihara (1998)
Russian (RU) (47)	7.44	6.8	8.65	9.13	9.36	11.36	Hanihara (1998)
Czechoslovakian (CZ) (22)	7.12	6.29	8.42	8.83	8.85	11.34	Hanihara (1998)

Table H-4. Mahalanobis D² values for the comparative data set

	PP	IK	OVA	OVG	OVH	RF	TM	MC	MS	MSP	MT	GR	RU
IK	0.520												
OVA	1.988	0.916											
OVG	2.820	1.381	0.347										
OVH	2.418	1.170	0.120	0.173									
RF	1.279	0.397	0.585	0.624	0.563								
TM	2.148	1.312	0.633	0.613	0.409	0.375							
MC	1.908	1.358	2.222	2.648	1.945	1.283	1.522						
MS	3.262	3.034	3.220	3.614	2.721	2.187	1.512	0.752					
MSP	2.732	2.418	2.862	2.844	2.313	1.602	1.214	0.562	0.252				
MT	3.229	2.575	2.642	2.780	2.134	1.527	0.994	0.763	0.170	0.264			
GR	5.444	4.350	3.944	3.425	2.968	2.707	1.727	1.989	0.922	0.952	0.608		
RU	5.254	4.130	5.126	4.610	4.341	2.754	2.641	2.134	1.605	1.397	0.976	0.957	
CZ	4.831	4.030	3.120	2.896	2.434	2.261	1.068	2.510	1.017	1.230	0.636	0.457	1.543

The eigenvalues and eigenvectors are then extracted from the double-centered matrix, and the values of the eigenvectors corresponding to positive eigenvalues can be thought of as points in a Cartesian plane. Each group is then projected as a coordinate in this plane, enabling group distances to be observed in multivariate space. Figure H-1 presents the results of the principal coordinates analysis.

It is clear from Figure H-1 that there is a tooth size difference between the Native American samples and the European samples. The Refugio sample is closest in proximity to other Native American samples, indicating a relatively high proportion of Native Americans in the sample. As discussed previously (Section G), the Refugio sample falls closer to the Tipu Maya sample than the European sample, indicating

more closely related tooth sizes, and thus the choice of regression formulae for age of hypoplasia formation estimates.

In addition to the principal coordinates analysis, a canonical variates analysis (CVA) was performed using the group means listed in Table H-3, the covariance matrix described above, and the individual group sample sizes. This type of analysis is similar to the PCA, but it uses the sample sizes of each group as a weighting factor. In addition, it produces multivariate distances for a set of unclassified individuals using the canonical scores for the group centroids. These distances can be used to aid in identification of these unidentified individuals. Using this method, a series of 27 individuals with complete maxillary buccal-lingual data from Refugio were entered into the function to assess individual proximity to the test groups from Table H-3. Figure H-2 presents the results of the CVA.

As expected, the majority of the individuals from Refugio have their minimum distance to the Native American groups. Several individuals show distances closer to the Mexican and European groups. This indicates several individuals of either Hispanic or possibly European ancestry were buried in the mission cemetery. One other possibility is that these individuals represent cases of possible admixture between local Native Americans and Hispanics living at the Refugio mission.

In order to answer questions of individual ancestry and admixture, the dental discrete traits were used when available. These data were analyzed using a

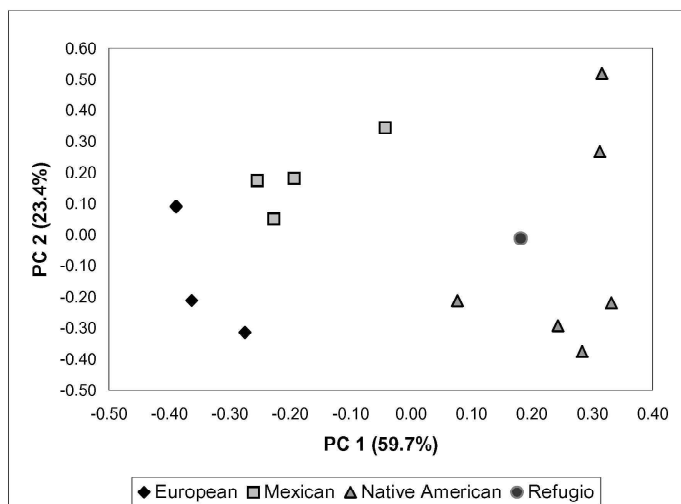


Figure H-1. Plot of group distances using principal coordinates.

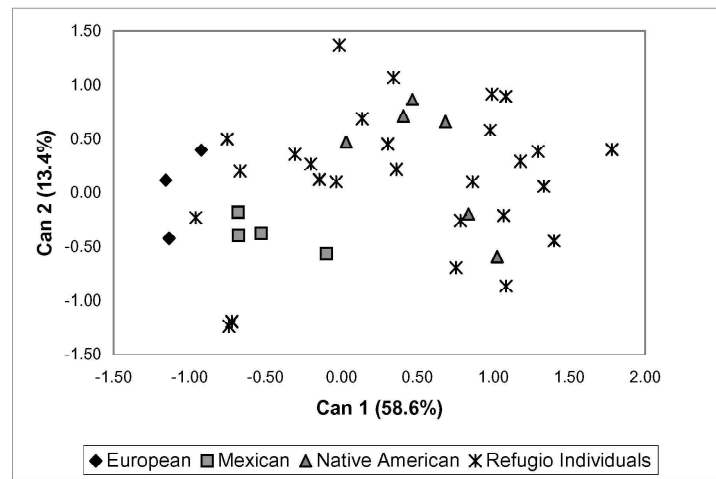


Figure H-2. Canonical plot of group means.

Bayesian framework. Bayes's theorem is a useful method for calculating posterior probabilities of an event given a prior event has happened, and is traditionally expressed as:

$$P(A_i|B) = \frac{P(A_i \cap B)}{\sum_{i=1}^n (P(A_1 \cap B) + P(A_2 \cap B) + \dots + P(A_n \cap B))}$$

where A_n is the n^{th} hypothesis in question. Using this method, the question was posed: What is the probability of an individual being Native American given that the n^{th} set of discrete dental traits is present? Traits were chosen based upon their distinct patterning in Native American populations compared to European populations. The traits employed in the analysis are listed in Table H-5.

For each individual with any of these traits scorable ($n=77$), posterior probabilities were calculated using Bayes's

theorem. More explicitly, the posterior probability $P(N|T_s=0)$ is calculated by:

$$T_s = 0 \text{ or } 1$$

$$P(N|T_s=0) = \frac{P(0|N) \cdot P(N)}{P(0|N) \cdot P(N) + P(0|E) \cdot P(E)}$$

$$\text{Assume: } P(E) = P(N) = .5$$

$$P(N|T_s=0) = \frac{P(T_s=0|N)}{P(T_s=0|N) + P(T_s=0|E)}$$

where $P(N|T_s=0)$ represents the probability of being Native American given that trait state 0 is present. The trait state is just the joint probability of getting the observed suite of traits, or $T_s=0 + P(t_1 * t_2 * \dots * t_n)$ assuming independence of the traits. For all individuals the prior $P(N)=P(E)=.5$, in other words, an uninformative prior for ancestry is used as to let

Table H-5. Traits used in Bayesian analysis and ancestral population frequencies*

Trait	Frequency	
	Native American	European
UI shovel	.919	.027
UM1 Carabelli's cusp	.056	.273
UM1 enamel extension	.437	.038
2 rooted UP1	.143	.407
4 cusp LM2	.086	.711
Cusp 6 LM1	.551	.083

*Data from Scott and Turner 1997

the individual trait states be the main factor in determining the posterior probability. The results of this method should be the most unbiased estimator of the individual's ancestry; also, individuals of possibly admixed ancestry might be identified. For classification purposes, the rule: If $P(N) > P(E)$ then classify as Native American, else classify as European is utilized. For cases where $P(N)$ was close to .5, individuals are considered as admixed. Table H-6 lists the results of the Bayesian analysis for all individuals with the traits in question. Figure H-3 gives the distribution of posterior probabilities of Native American ancestry for the Refugio sample. Figure H-4 presents the spatial distribution of the classified individuals from Refugio. No pattern or discrete clusters of affiliated individuals are evident indicating an even distribution of all groups across the cemetery area.

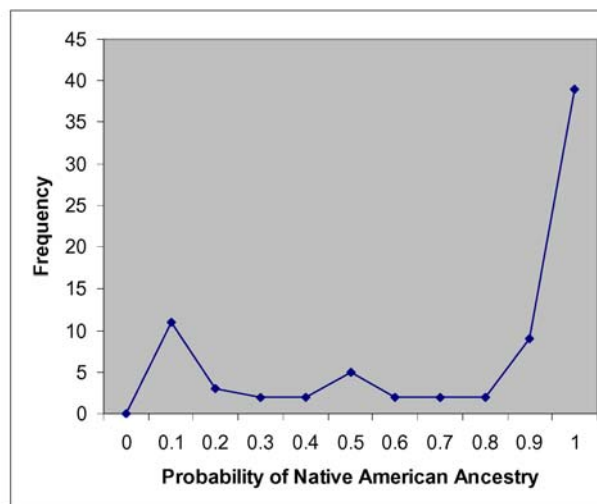


Figure H-3. Distribution of posterior probabilities of Native American ancestry.

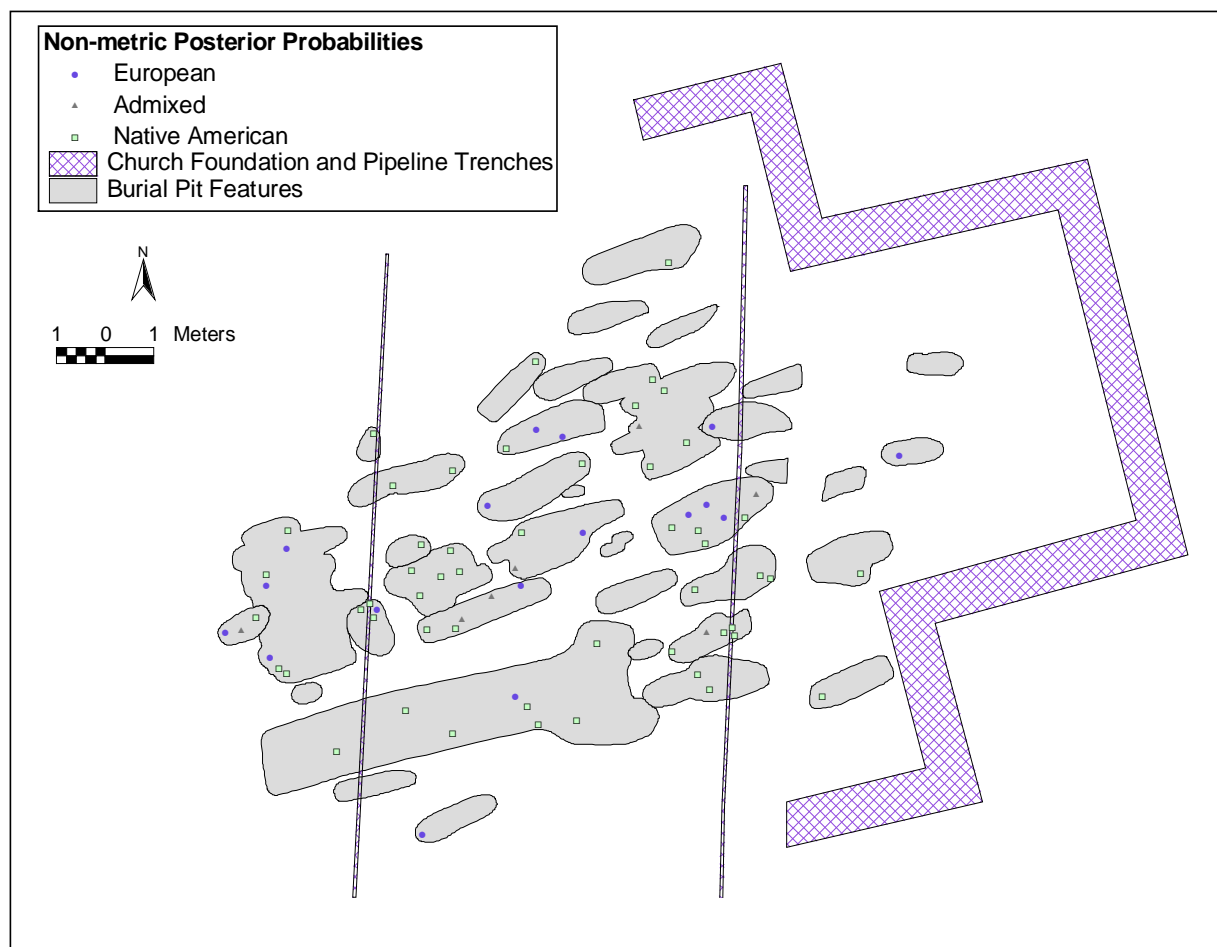


Figure H-4. Distribution of burials by non-metric posterior probabilities. Classifications follow definitions in text.

Table H-6. Posterior probabilities and ancestry estimates calculated from dental discrete traits

Feature	Burial	Sex	Skeletal Ancestry Estimate	P (Native)	P (European)	N Traits Present	Bayesian Ancestry Estimate
5	28	M	Indeterminate	-	-	0	-
21	81	F	Indeterminate	-	-	0	-
22	083B	M	Indeterminate	-	-	0	-
5	21	F	Indeterminate	0.449	0.551	1	Admixed*
5	24	I	Indeterminate	0.449	0.551	1	Admixed*
12	45	M	Native American	0.564	0.436	3	Admixed
16	67	F	Indeterminate	0.57	0.43	6	Admixed
16	66	M	Indeterminate	0.449	0.551	1	Admixed*
17	80	M	Indeterminate	0.435	0.565	3	Admixed
22	083A	M	Native American	0.448	0.552	3	Admixed
4	9	M	Native American	0.944	0.056	2	Native American
4	13	M	Native American	0.857	0.143	5	Native American
4	17	M	Native American	0.909	0.091	5	Native American
4	8	F	Native American	0.999	0.001	5	Native American
4	18	F	Native American	0.857	0.143	1	Native American*
4	6	M	Indeterminate	0.998	0.002	4	Native American
5	30	M	Native American	0.999	0.001	6	Native American
5	23	F	Native American	0.999	0.001	5	Native American
5	25	F	Native American	0.961	0.039	4	Native American
9	37	F	Indeterminate	0.999	0.001	5	Native American
11	40	F	Indeterminate	0.857	0.143	1	Native American*
11	42	M	Indeterminate	0.924	0.076	4	Native American
12	44	F	Indeterminate	0.857	0.143	5	Native American
13	048A	M	Indeterminate	0.842	0.158	1	Native American*
13	46	F	Native American	0.986	0.014	6	Native American
13	47	F	Indeterminate	0.991	0.009	6	Native American
14	51	I	Native American	0.994	0.006	2	Native American
14	52	M	Indeterminate	0.925	0.075	4	Native American
16	63	F	Native American	0.998	0.002	4	Native American
16	68	I	Native American	0.998	0.002	5	Native American
16	62	F	Indeterminate	0.947	0.053	3	Native American

Table H-6. continued...

Feature	Burial	Sex	Skeletal Ancestry Estimate	P (Native)	P (European)	N Traits Present	Bayesian Ancestry Estimate
17	76	F	Native American	0.881	0.119	4	Native American
17	74	M	Indeterminate	0.996	0.004	3	Native American
17	77	M	Indeterminate	0.885	0.115	2	Native American
17	75	I	Indeterminate	0.999	0.001	4	Native American
21	82	F	Hispanic	0.999	0.001	4	Native American
22	085A	M	Indeterminate	0.991	0.009	4	Native American
22	88	M	Indeterminate	0.989	0.011	2	Native American
22	86	M	Native American	0.993	0.007	5	Native American
22	1	F	Native American	0.996	0.004	5	Native American
22	87	F	Indeterminate	0.999	0.001	4	Native American
22	85	M	Indeterminate	0.95	0.05	5	Native American
22	83	F	Indeterminate	0.996	0.004	3	Native American
23	91	M	Native American	0.925	0.075	4	Native American
24	93	F	Native American	0.991	0.009	4	Native American
24	102	M	Indeterminate	0.914	0.086	1	Native American*
24	92	M	Indeterminate	0.885	0.115	2	Native American
26	106	M	Indeterminate	0.985	0.015	3	Native American
26	108A	M	Indeterminate	0.919	0.081	1	Native American*
26	109	M	Native American	0.999	0.001	6	Native American
26	112	M	Native American	0.999	0.001	5	Native American
26	113	M	Indeterminate	0.925	0.075	4	Native American
26	106A	F	Indeterminate	0.95	0.05	5	Native American
34	129	M	Hispanic	0.999	0.001	5	Native American
34	134	I	Hispanic	0.812	0.188	2	Native American
34	130	M	Indeterminate	0.999	0.001	4	Native American
34	133	I	Indeterminate	0.902	0.098	2	Native American
36	M01C	M	Native American	0.914	0.086	1	Native American*

Table H-6. continued...

Feature	Burial	Sex	Skeletal Ancestry Estimate	P (Native)	P (European)	N Traits Present	Bayesian Ancestry Estimate
8	36	F	Native American	0.773	0.227	3	Native American
15	56	F	Native American	0.655	0.345	6	Native American
22	90	M	Native American	0.791	0.209	3	Native American
30	125	F	Indeterminate	0.639	0.361	2	Native American
24	97	M	Indeterminate	0.334	0.666	4	European
30	118	M	Hispanic	0.156	0.844	2	European
15	57	M	Indeterminate	0.161	0.839	5	European
15	54	M	Indeterminate	0.254	0.746	4	European
24	100A	M	Indeterminate	0.302	0.698	3	European
31	126	F	Native American	0.217	0.783	5	European
5	34	I	Indeterminate	0.044	0.956	2	European
5	20	M	Indeterminate	0.041	0.959	4	European
5	32	M	Indeterminate	0.036	0.964	3	European
11	39	M	Indeterminate	0.063	0.937	4	European
13	50	M	Indeterminate	0.031	0.969	4	European
14	53	M	Indeterminate	0.041	0.959	4	European
16	72	M	Indeterminate	0.093	0.907	4	European
25	105	I	Indeterminate	0.071	0.929	2	European
26	108	F	Indeterminate	0.056	0.944	1	European*
30	119	F	Indeterminate	0.036	0.964	6	European
35	136	M	Indeterminate	0.056	0.944	1	European*
38	X01L	I	Indeterminate	0.143	0.857	1	European*

*Classification questionable due to only one trait present.

The results of this analysis conclude that the constituency of the Refugio sample is mostly of Native American ancestry due to the large peak in the distribution between .9 and 1. There is also a second small mode from .1 to 0, possibly indicating a sizeable segment of the sample being European, or Hispanic. The third mode of the distribution around .5 could be interpreted as admixed individuals of European and Native American ancestry. This corresponds well with the results of the canonical variates analysis, which shows the majority of the Refugio sample having minimum D² distance to Native American group centroids, and smaller subsets of the sample being closer to Hispanic and European group centroids.

Osteological Analyses

Section 1

Metric Analysis of Postcranial Remains

This section deals with the various inferences that can be made from metric analysis of postcranial remains. Among those possible for metrics obtained from the Refugio sample are estimates of ancestry, robusticity, height, weight, and growth status. The fragmentary nature of the Refugio remains necessitated some modifications in the usual analytical strategies. When individuals and bones are complete, various multivariate procedures may be used which allow assessment of general size and shape variation. Complete individuals are virtually non-existent and individual bones are frequently fragmented. We have therefore resorted to several individual analyses employing variables allowing assessment of particular morphological regions. Investigating morphology of different morphological systems independently of one another is not ideal, but maximizes sample size.

Comparative data from other mission samples examined using the same protocols as those employed in the present analysis are available. These include Mission San Juan Capistrano and the Church component of Pecos Pueblo. We have also included the Historic component associated with Glaze 6 at Pecos, as it provides some control over the mission influence. Samples for these mission samples are uniformly small. When a broader perspective is called for, other Native American or world samples have also been included for comparison.

We have devoted considerable attention to stature estimation, especially methodological issues that have influenced stature estimates on previous Texas samples. This is necessary because the historical record has emphasized the great height of the Karankawa, which in turn has influenced skeletal interpretations.

Platymeria and Ancestry

Limb bones are generally considered poor indicators of ancestry, although with relatively complete remains, Blacks and Whites may be reliably distinguished (Ousley and Jantz 1997). The one indicator in the postcranial skeleton, which seems to distinguish Native Americans from Whites, is the flatness of the subtrochanteric portion of the femoral shaft. This idea has been most extensively developed by Gill (1995). The principal feature is medio-lateral expansion and anterior-posterior shortening of the subtrochanteric part of the femur shaft, producing a condition known as platymeria. Gill has shown that this feature effectively discriminates Northern Plains Indians from Whites. Unfortunately, little is known of the determinants of the feature, i.e., whether functional or not, or of its distribution in time and space. The marked platymeria of Northern Plains groups in contrast to other world populations is clearly evident in Cole's (1994) analysis.

Table I-1 shows the platymeria summary statistics for the Refugio sample and comparative samples. A consistent picture emerges, which can be summarized as follows: 1) Samples consisting of unmixed Native Americans exhibit platymeria and are relatively homogeneous. The historic Pecos component associated with Glaze 6 is the most extreme in this regard; 2) Recent Whites do not exhibit platymeria and are relatively homogeneous; 3) Recent Hispanics are only slightly more platymeric than Whites; 4) The three mission samples, presumably containing mixtures of Native Americans, Europeans and individuals of mixed ancestry, have mean values intermediate between Whites and Native Americans and tend to be more variable. Although in all three mission samples males exhibit a higher

Table I-1. Index of platymeria for Refugio and various other populations

Group	Males			Females			Source
	n	x	s.d.	n	x	s.d.	
Refugio	23	0.814	0.062	26	0.788	0.073	Present study
Capistrano	15	0.858	0.112	12	0.811	0.089	Unpublished data
Pecos Church	14	0.813	0.086	17	0.731	0.071	Unpublished data
Pecos Glaze 6	15	0.707	0.048	10	0.718	0.059	Hooton's data
Plains Woodland	28	0.76	0.07	25	0.74	0.06	Cole 1994
Plains Coalescent	239	0.73	0.06	193	0.72	0.06	Cole 1994
Recent Hispanics	29	0.861	0.078	5	0.876	0.069	Forensic data
Recent Whites	168	0.909	0.089	116	0.891	0.073	Forensic data

mean (less platymeric) than females, and are less variable, only in Pecos Church is this difference significant. That may indicate that the number of non-Native males exceeds the number of non-Native females. No other sex difference is significant, although there is a general tendency for females to be slightly more platymeric than males.

The striking difference between Native Americans and Whites raises the question of whether femur subtrochanteric morphology could be used to identify ancestry in the Refugio sample. We have attempted to explore the relationship of platymeria to ancestry in Refugio in two ways: 1) Examine the relationship between platymeria and other aspects of bone morphology. Karankawa are thought of as large and robust people. We would therefore expect that the more platymeric (presumably Native) femora should be larger and more robust than less platymeric femora (presumably non-Native). 2) Use the limited precontact data as a model for Karankawa platymeria. This requires the assumption that Karankawa platymeria is the same as precontact coastal populations.

Table I-2 gives the correlation matrix of femur length, ancestry, and platymeria. For purposes of numerical processing, individuals judged Native were scored 1, non-Native 0. Femur lengths were centered on sex specific means to eliminate sex difference in length. Platymeria has a non-significant positive correlation with femur length and a significant negative correlation with ancestry. The negative correlation means that individuals judged Native have more platymeric subtrochanteric femora. We can reject the hypothesis that platymeria is correlated with femur length.

Table I-3 shows the correlation of platymeria, femur mid-shaft size (robusticity), and ancestry. It too shows no significant correlation of platymeria with femur mid-shaft size. Platymeria is negatively correlated with ancestry, but mid-shaft size is not correlated with ancestry.

There are two ways to interpret the absence of correlation between platymeria and other aspects of femur morphology. Either Native and non-Native individuals do not differ in femur length or mid-shaft size, or platymeria is not a reliable indicator of ancestry. It is likely that Natives and non-Natives do not differ in bone length (see section on stature estimation), but our experience with these remains provides a strong indication that Karankawa bones are more robust than those of Europeans or Hispanics. That in turn suggests that platymeria is not a reliable indicator of ancestry in Refugio. The moderate correlation between platymeria and

Table I-2. Correlation of platymeria with femur length and ancestry (n=31)

Variable	Platymeria	Femur Length	Ancestry
Platymeria	1.000		
Femur Length	0.0386	1.0000	
Ancestry	-0.4268*	0.2068	1.000

*P < 0.05

Table I-3. Correlation of platymeria with femur midshaft size and ancestry (n=46)

Variable	Platymeria	Mid-shaft size	Ancestry
Platymeria	1.000		
Mid-shaft size	0.1402	1.0000	
Ancestry	-0.2927*	0.0974	1.000

*P < 0.05

ancestry is to some extent circular, since platymeria was one of the criteria used to assess ancestry.

Differences between Whites and Native Americans are sufficient to discriminate in test cases where ancestry is known *a priori* (Gill 1995). The principal problem with applying this to Refugio is that we do not know the degree to which the Native Americans at Refugio, principally Karankawa, expressed platymeria. Some indication of this can be obtained from the limited precontact Texas coast material. Table I-4 gives the index of platymeria for Palm Harbor (Comuzzie et al. 1984) and Oso (Woodbury and Woodbury 1935). Sexes were pooled because the femora in Palm Harbor were unsexed and the sex differences are minimal in any case. The two prehistoric sites have platymeric indices greater than the recent Native Americans in Table I-1. The two prehistoric sites are slightly more platymeric than Refugio, but the three sites are not significantly heterogeneous. There is, however, significant heterogeneity among the two prehistoric Texas coast samples and Pecos Glaze 6 sample ($F_{2,39} = 3.931$, $P < 0.05$). The other recent Native Americans, with much larger sample sizes, would also differ significantly from the Texas coast samples, although they were not directly tested.

The limited evidence supports the idea that the prehistoric Texas Coast populations were less platymeric than recent Native Americans. If we make the reasonable assumption that they reflect the morphology of the Karankawa, then we can conclude that they are not characterized by the extreme platymeria of other recent Native Americans. That in turn suggests that platymeria is not an especially effective discriminator of non-Native elements in the population.

Table I-4. Index of platymeria summary statistics for Refugio and precontact sites

Group	N	Mean	s.d.	Min	Max
Refugio	56	0.8020	0.0681	0.6364	0.9310
Oso	10	0.7693	0.0825	0.6774	0.9231
Palm Harbor	7	0.7536	0.0475	0.6571	0.8000

$$F_{2,70} = 2.2302, P > 0.05$$

Limb Proportions and Stature Estimation

Stature and Limb Proportions of Living Texas Indians

A relatively new resource for evaluating biological variation in late nineteenth-century Native Americans is Boas' data base (Jantz 1995; Jantz et al. 1992). These anthropometric data were collected in the late nineteenth century, mainly in 1892. They provide a baseline of variation against which to compare late historic skeletal samples, at least for certain parameters. Relatively few Texas samples were measured, since many, like the Karankawa, were extinct prior to 1892. The Boas database contains samples of Apache, Comanche, Caddo, and Tonkawa. The last group was a western neighbor of the Karankawa. According to Gatschet (1891; cited in Ricklis 1996), Tonkawas were living among the Karankawas in the early nineteenth century.

Table I-5 presents the summary statistics for stature, sitting height, subischial height, and sitting height-stature index. In both sexes Tonkawa are tallest, but in neither sex is

variation among groups significant for stature. However, the components of stature and the sitting height-stature index are variable. In males sitting height exhibits significant variation. Tonkawa and Apache have the greatest sitting heights and both also have relatively longer trunks, as seen in the sitting height-stature index. The index, however, does not exhibit significant variation. In females both subischial height and sitting height-stature index vary significantly among groups. Both Tonkawa and Comanche have short trunks and long legs, giving them lower sitting height-stature ratios than Apache and Caddo.

The trunk length-leg length relationships on a broader scale are illustrated in Figure I-1. The "Old Americans" (American Whites) from Hrdlicka (1970) and American Blacks (Herskovits 1969) have mainly late nineteenth century birth dates, predating the secular increase in stature they have experienced in the past 100 years. The Japanese are data from Hattori et. al (1991), Zuni and Taos are Southwestern groups taken from Boas' data and the Totonac are Mexican Gulf Coast group measured by Starr at the turn of the century (Faulhaber 1970). Faulhaber (1970) has reviewed the anthropometry of Mexican Indians. The mean sitting height-stature ratio for 62 Mexican groups is 52.6, (sd=0.78),

Table I-5. Stature, Sitting Height (SH), Subischial Height (SI), and Sitting Height-Stature Ratio (SSR) for Texas populations measured in 1892 (all measurements in mm)

Group	N	Stature		SH		SI		SSR	
		X	s.d.	X	s.d.	X	s.d.	X	s.d.
Apache M	116	1692.55	59.07	884.47	30.61	808.08	42.67	52.28	1.35
Caddo M	18	1679.22	66.01	867.78	29.62	811.44	45.70	51.70	1.20
Comanche M	76	1676.50	62.81	871.21	35.47	805.29	41.65	51.98	1.38
Tonkawa M	13	1697.93	58.82	884.54	32.97	813.39	47.20	52.12	1.67
Male F ratios		1.302		3.400**		0.206		1.339	
Apache F	37	1552.49	51.86	816.62	32.23	735.87	40.85	52.62	1.71
Caddo F	10	1530.90	59.66	810.40	35.27	720.50	44.10	52.95	1.76
Comanche F	33	1563.06	45.38	806.82	40.27	756.24	35.47	51.61	1.94
Tonkawa F	18	1564.94	54.98	809.28	37.31	755.67	38.74	51.72	1.63
Female F ratios		1.253		0.452		3.345**		2.887*	

Male degrees of freedom = 3 and 219; Female degrees of freedom = 3 and 94

*P < 0.05; **P < 0.025

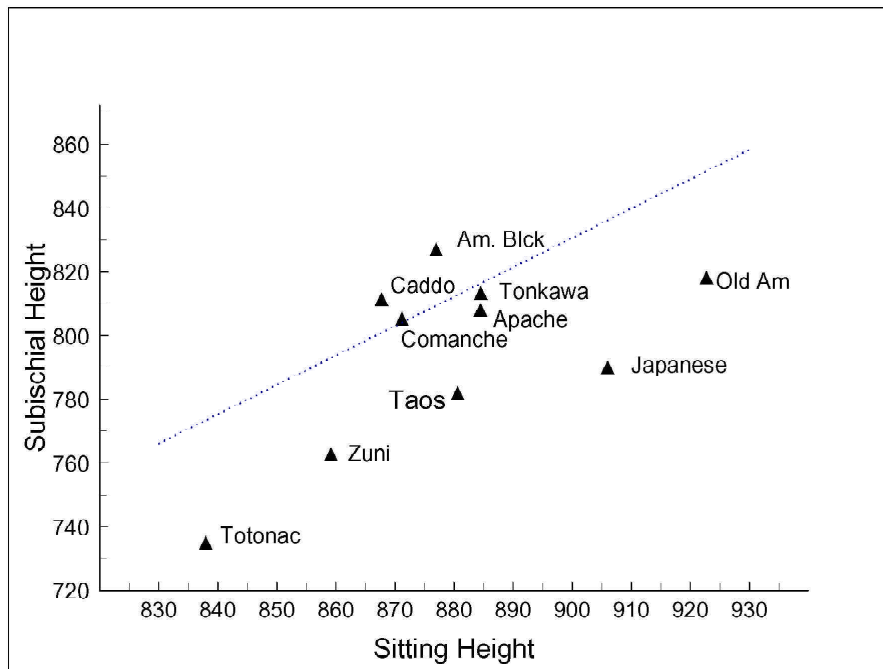


Figure I-1. Bivariate plot showing relationship of sitting height to subischial height (leg length) in four nineteenth-century Texas samples compared to various world groups.

a mid-range index. One would have to characterize Mexican populations as variable, those above the mean relatively long legged, and those below the mean relatively short legged. The line represents a sitting height-stature ratio of 52 percent; points above the line are populations with sitting height-stature ratios greater than 52 percent; below the line populations with ratios less than 52 percent. The value of 52 percent is arbitrary but can generally be taken as a rough separation of relatively long legged-short trunked populations from those with relatively long trunks and short legs. American Whites, Japanese, Southwest and Mexican Indians are included in the latter group. American Blacks have the relatively longest legs and shortest trunks, but the Texas Indians fall much closer to American Blacks than to American Whites, Japanese, or Southwest and Mexican

Indians. This proportional variation has some clear implications for stature estimation, which will be addressed later on.

The diagonal line of Figure I-1 denotes a sitting height to stature ratio of 52 percent, a rough separator of relatively long-legged populations (above the line) from relatively short-legged populations (below the line).

A noteworthy feature of the sitting height-stature ratios seen in the Texas Indian data presented in Table I-5 is the apparent absence of sex dimorphism. The relatively longer legs of males seen in populations of European ancestry are well known (Tanner 1978). The sex difference is due to the longer prepubertal growth period of males and the positive allometry of the leg length. In Hrdlicka's Old

Americans, for example, the sitting height-stature ratio is 53.02, $sd=1.32$ and 54.21, $sd=1.45$ for males and females respectively. This difference is highly significant ($t=7.38$, $p<0.001$), reflecting the relatively longer trunk and hence shorter legs of females. By contrast in the Texas samples only the Caddo sex difference is significant ($t=2.23$, $p<0.05$), and in Comanche and Tonkawa males actually have relatively shorter legs than females.

Long Bone Lengths and Proportions

Table I-6 presents the summary statistics for the maximum lengths of six long bones for the total sample. There are 80 individuals with at least one bone length, but the maximum

Table I-6. Summary statistics of long bone lengths of Refugio sample

Bone	Males					Females				
	n	Mean	s.d.	Min	Max	n	Mean	s.d.	Min	Max
Humerus	15	325.267	18.398	302	364	9	295.778	17.683	267	315
Radius	33	252.242	14.062	223	278	20	229.950	15.408	192	248
Ulna	27	266.852	14.352	236	296	16	249.188	15.241	209	263
Femur	21	450.238	23.596	420	503	12	421.333	25.791	358	454
Tibia	20	386.095	23.841	351	437	16	346.313	20.975	295	377
Fibula	14	374.643	25.569	339	430	10	337.400	26.949	285	370

sample size for an individual bone is 27 (ulna) for males and 17 (radius) for females. We have not attempted to estimate fragmentary bone lengths using Steele's (1970) technique, although some tibiae were estimated from fibula lengths and some radii from ulna lengths. Table I-6 incorporates these estimated values, which has enhanced the radius and tibia sample sizes.

Because of the fragmentary state of the remains, there are few individuals complete for all length measurements. Although the lengths of the individual bones can be examined, it is normally of greater interest to examine interrelationships among elements. We have attempted this in two ways: 1) Examine selected bivariate relationships; and 2) Use the mean bone lengths in multivariate analyses with covariance matrices estimated from other more complete groups.

Femur-Tibia and Humerus-Radius Relationships

Table I-7 gives the femur and tibia lengths for individuals where both dimensions were available, and the crural index (tibia/femur) x 100. Sample sizes decline markedly, but both femur and tibia exhibit significant variation among the four samples in males. The female samples are homogeneous. The patterning of variation among groups is the same in both sexes, Refugio bones are the longest, Capistrano next, and Pecos the shortest. Little difference is seen between the Church and non-Church samples at Pecos. Some distal elongation is suggested by the higher crural index in males, but the variation is not significant.

Table I-8 gives the humerus and radius lengths and the brachial index (radius/humerus) x 100 for those individuals

Table I-7. Femur length, tibia length, and Crural Index for mission samples

Group	n	Femur Length		Tibia Length		Crural Index	
		x	s.d.	x	s.d.	x	s.d.
Refugio M	15	453.27	24.15	382.20	17.10	84.38	2.23
Capistrano M	8	447.00	23.59	370.00	21.44	82.78	2.27
Pecos Church M	10	434.50	18.39	359.20	11.56	82.72	2.61
Pecos Glaze 6 M	14	427.93	21.52	355.71	19.94	83.12	1.59
Male F ratios	3, 43	3.63*		6.21*			1.65
Refugio F	7	414.71	32.59	343.71	27.49	82.88	1.49
Capistrano F	10	412.80	27.73	340.10	25.56	82.37	1.90
Pecos Church F	9	397.56	17.56	333.33	16.28	83.86	2.64
Pecos Glaze 6 F	9	397.89	23.12	328.56	19.25	82.59	1.95
Female F ratios	3, 31	1.14		0.76			0.94

*P < 0.05; **P < 0.01

Table I-8. Humerus length, radius length, and Brachial Index for mission samples

Group	N	Humerus	s.d.	Radius	s.d.	Brachial	s.d.
Refugio M	12	322.00	16.32	251.50	15.77	78.13	3.52
Capistrano M	10	323.60	8.88	255.8	9.89	79.05	2.77
Pecos Church M	11	309.36	11.30	240.27	10.34	77.66	1.49
Pecos Glaze 6 M	13	308.85	17.23	237.92	16.36	77.01	2.35
Male F ratios	3, 42 df	3.55*		4.49*		1.18	
Refugio F	7	294.57	20.23	222.86	19.90	75.64	4.13
Capistrano F	8	292.38	18.93	227.13	16.90	77.73	3.80
Pecos Church F	7	287.57	17.06	218.57	12.43	76.06	2.78
Pecos Glaze 6 F	7	284.86	14.87	214.71	16.18	75.33	3.08
Female F ratios	3, 25 df	0.43		0.82		0.72	

* $p < 0.05$

possessing both bones. The males exhibit significant variation among bone lengths. It is primarily due to the difference between Pecos and the two Texas missions. Capistrano is the most distally elongated but the variation among groups is not significant.

Four Bone Relationships

The fragmentary nature of the skeletal remains means there will be few individuals with measurements of both upper and lower limbs. To assess this we use larger reference samples to obtain estimates of the covariance matrices required to get Mahalanobis distances and canonical variates. Then mean values for the Refugio (as given in Table I-6), Capistrano, and Pecos samples are used with the reference samples to obtain relationships. We also included Mitchell Ridge bone lengths from Table 9.34 in Powell (1994), and the Late Prehistoric Ohio sample from Sciulli and Giesen (1993). The reference samples employed are Arikara from the Larson site, Terry Whites and Terry Blacks. This approach also has the advantage of placing the Refugio sample into a broader context of variation.

Relationships among groups are shown by means of bivariate canonical plots in Figure I-2. Relationships presented by the two sexes are similar in broad outline, but differ in some details. In males the first axis isolates Terry Whites on the

left edge of the plot. Mitchell Ridge is the extreme group on the right (positive) side of the plot, but Terry Blacks and most Native Americans occupy positive positions on this axis. Capistrano and Pecos Church have the lowest scores, but are still well above Terry Whites. Variation on axis one is primarily an expression of distal segment (radius and tibia) elongation. Hence, the Native American samples used in this analysis, have to various degrees, long radii and tibiae. They are more similar to American Blacks than to American Whites, Refugio, and Mitchell Ridge in particular.

Terry Blacks (positive) and Pecos Church (negative) occupy extreme positions on axis two. This axis is mainly an expression of general size with slightly greater emphasis on the proximal limb segments. Their high positive score expresses the greater length of American Black bones. Pecos, both the Church and Glaze 6 components, are the smallest of the Native American samples, Refugio the largest (except for Arikara in females), and Capistrano is intermediate.

In females, Mitchell Ridge and Arikara are the extreme positive values, again contrasted with Terry Whites. In this instance, the first axis emphasizes relative radius length. The second female axis also places Mitchell Ridge in an extreme position, opposing it to Pecos, Capistrano, and Ohio. This axis is to a considerable extent a reflection of size, but the distal elements are more emphasized than the proximal ones.

The two axes account for about 95 percent of the among group variation, and so present an accurate picture of relationships. Taxonomically, the Native American samples cluster loosely in the right lower quadrant of the space. The slight displacement of the Mission samples toward American Whites might be an expression of the small numbers of Whites and Hispanics contained in these samples. The slight displacement toward American Whites is also seen for Pecos Glaze 6, which presumably has no non-Native elements. We can conclude that the relationships expressed by bone lengths are primarily a reflection of Native American features present in this sample.

Stature Estimation of the Refugio Sample

One of the first questions to emerge from bioarchaeological analyses is that of stature estimations. Since stature is commonly used to describe physical features of contemporary people, it provides a way to translate skeletal dimensions into easily understood terms. It also provides a means to relate skeletal variation back to the historical and ethnohistorical record. The principal problem in stature estimation of archaeological samples is lack of appropriate estimation criteria.

Stature estimations are normally based on regression equations derived samples where stature can be measured from cadavers (Genoves 1967) or is known in life (Trotter and Gleser 1952, 1958). It is well known that the stature formulae should not be extrapolated to groups with dissimilar heights or limb proportions (Meadows and Jantz 1995). Formulae are often used (e.g., Comuzzie 1987) under the assumption that Mexican Indians are likely to be more proportionately similar to North Amerindians than American Whites. Trotter and Gleser (1958) formulae for “Mongoloids” are also employed under the assumption that Native North Americans, as an East Asian derived population, would be proportionately similar. However, Sciulli et al. (1990) found that East Asian derived formulae systematically overestimated stature of prehistoric Ohio Indians by 3-8 cm. Sciulli et al. (1990) present formulae for prehistoric Ohio populations by developing regressions to predict stature estimated from the Fully method, which reconstructs stature anatomically from all elements which contribute to stature. What emerges is that their Ohio Native American sample have relatively long legs, in contrast to East Asian derived populations, which have relatively short legs.

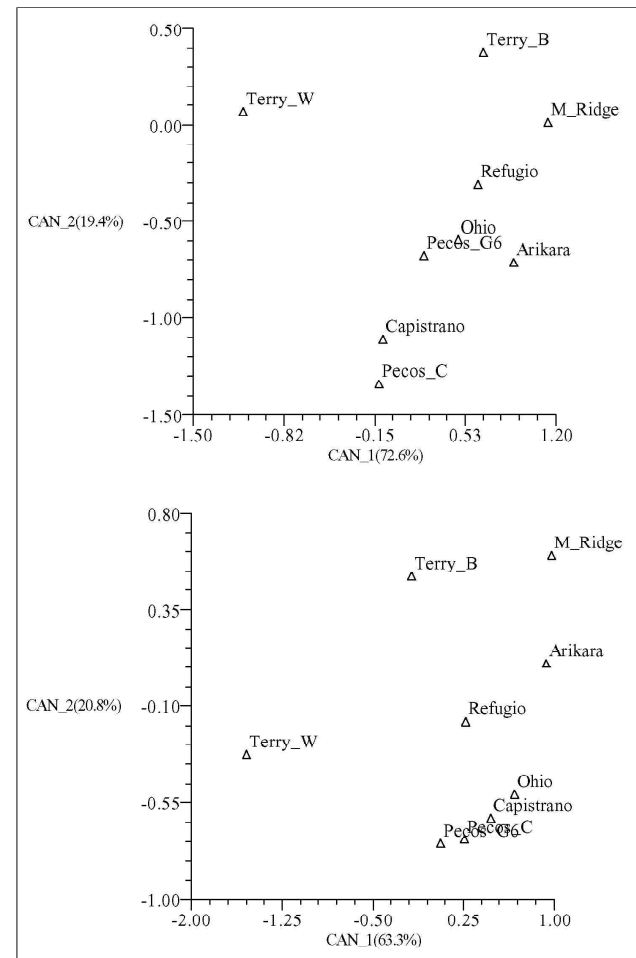


Figure I-2. Canonical plot of long bone lengths showing position of Refugio in relation to American Blacks, Whites, and various Native American groups. (top = males, bottom = females)

Table I-9 presents height and leg length to stature ratios of samples upon which stature formulae have been based and which have been used to estimate Native American statures. The relatively long legs of American Blacks and the relatively short legs of “Mongoloids” are apparent, features that also emerged in the living samples (see Figure I-1). Genoves’ Mesoamerican sample have legs only slightly longer than Asians or Whites. What is most surprising is that Ohio Indians have the longest legs relative to stature, proportions that would be termed “tropical” if observed in African populations. The Ohio sample is not without problems. It is a small sample covering a large time range, from Archaic to Mississippian. It may also be that stature is underestimated via the Fully method; more testing of its performance is required.

The foregoing results concerning stature and limb proportions suggest that formulae commonly used to reconstruct stature of Texas Coast Native populations are likely to yield misleading results. The limb length-trunk height relationships cannot be known in the Refugio sample, likely consisting mainly of Karankawa. It is unlikely that Karankawa lower limbs were any shorter relative to stature than the Tonkawa. The inference that they may have been as long or longer comes from the distal elongation and similarity to American Blacks in limb proportions. That in turn suggests we might get better stature estimates from American Black formulae than the more commonly used Trotter and Gleser "Mongoloids" or Genoves' Mesoamericans, both relatively short-legged populations.

Some idea of the range in stature estimates can be obtained by estimating stature-using formulae from groups exhibiting a range of limb-trunk proportions. Table I-10 presents the mean estimates and their standard deviations using different formulae. The range in estimates is high, in males 6 cm for the femur and 8 cm for the tibia; in females both bones give a range of about 6 cm. The high estimates result from

formulae based on relatively short-legged populations, Mongoloids, Mexicans, and American Whites. The shortest estimates result from formulae based on the relatively long legged samples, Ohio Indians and American Blacks. Genoves' Mesoamerican sample actually yields estimates rather similar to those obtained by the American Black sample. We can reject the highest estimates as likely over estimates. It seems unlikely that the Karankawa would have had the relatively short legs assumed by the samples upon which the formulae were derived. That leaves us with stature estimates based on Ohio Indians or American Blacks. The extreme proportions of the Ohio Indians may be cause for concern, although it is difficult to point to a specific problem. The Ohio Indians have bone lengths rather similar to the Refugio sample so we are estimating well within the range of the regression. The American Black sample, on the other hand, has bones rather longer than Refugio, so we are estimating farther away from the mean where the regression is less reliable. Probably the best we can do at present is argue that Refugio mean stature is 164-166 cm (roughly 5'5") for males and 153-155 cm (roughly 5'2") for females.

Table I-9. Stature and lower limb bone/stature ratios

Sample	Stature	Fem+Tib/Stature	Source
Terry White males	1703.92	48.7	Trotter and Gleser 1952
Terry White females	1606.82	48.5	Trotter and Gleser 1952
Terry Black males	1727.29	50.5	Trotter and Gleser 1952
Terry Black females	1608.92	50.5	Trotter and Gleser 1952
Mongoloid males	1685.00	48.2	Trotter and Gleser 1958
Mexican males	1689.00	49.2	Trotter and Gleser 1958
Mesoam. males	1614.9	48.9	Genoves 1967
Mesoam. females	1498.0	48.2	Genoves 1967
Ohio Indian males	1658.0	50.6	Sciulli et al. 1993
Ohio Indian females	1554.0	50.1	Sciulli et al. 1993

Table I-10. Stature estimates of Refugio using formulae derived from various samples

Formula	Femur				Tibia			
	x	s.d.	Min	Max	x	s.d.	Min	Max
Males	n=21				n=20			
Mongoloids	169.37	5.07	162.87	180.72	173.41	5.65	165.34	185.89
Mexicans	168.53	5.76	161.15	181.40	171.42	5.58	163.46	183.75
Mesoamericans	165.63	5.33	158.80	177.56	166.66	4.63	160.05	176.90
Ohio Indians	163.08	6.10	155.41	177.19	165.98	6.55	156.81	180.92
Terry Whites	167.53	6.08	159.74	181.13	172.26	6.58	162.86	186.81
Terry Blacks	165.21	5.63	157.99	177.81	167.08	6.15	158.29	180.67
Females	n=12				n=16			
Mesoamericans	156.37	6.68	139.96	164.83	155.48	5.71	141.52	163.83
Ohio Indians	152.68	6.02	137.88	160.31	153.78	5.63	140.01	162.03
Terry Whites	158.03	6.21	142.77	165.90	158.60	5.92	144.12	167.25
Terry Blacks	155.52	5.82	141.23	162.88	154.48	5.11	141.97	161.96

Functional Morphology and Robusticity

There is a substantial body of literature relating long bone morphology and robusticity to activity and subsistence (Bridges 1995; Cole 1994; Ruff 1987, 1994). Ruff in particular has argued that understanding how bone responds to functional demands enables one to infer the kinds of activities in which earlier populations were engaging, including subsistence activities, sexual division of labor, long distance movement, and type of terrain (Larsen 1997; Ruff 2000).

We do not have cross sectional data available to estimate engineering properties recommended by Ruff, but external dimensions of the bone shafts can yield insights into biomechanical properties and robusticity of long bones. We use a measure of midshaft shape and two measures of robusticity for the femur, one measure of tibia shape at the level of the nutrient foramen, one measure of robusticity for the tibia, and one measure of robusticity for the humerus. These are defined as follows:

$$\begin{aligned} \text{Femur Midshaft shape} &= a\text{-}p/m\text{-}l \\ \text{Femur Robusticity} &= \bar{O}((a\text{-}p) \times (m\text{-}l)) / \text{femur length} \\ \text{Tibia shape at nutrient foramen} &= a\text{-}p/m\text{-}l \\ \text{Tibia robusticity at nutrient foramen} &= \\ &\bar{O}((a\text{-}p) \times (m\text{-}l)) / \text{tibia length} \\ \text{Humerus robusticity} &= \text{circumference/humerus length} \end{aligned}$$

where a-p = anterior-posterior diameter and m-l = medial-lateral diameter.

Table I-11 shows the femur midshaft shape and tibia nutrient foramen shape indices for Refugio, Capistrano, Pecos Church, and several comparative samples from the Northern

and Southern Plains. Refugio femora are rounder in cross section than most other groups. Males have the lowest midshaft shape index of all comparative groups, and females are third, after Pecos Church and Le Beau Phase. Considering only those we feel are Native makes little difference. Males become slightly more round and females slightly less. Sexual dimorphism is less than most other groups. The three mission samples are not significantly different ($F=0.195$, $df=2,53$, $P>0.05$; $F=0.984$, $df=2,48$, $P>0.05$ males and females respectively).

Tibiae cross sectional shape at the nutrient foramen exhibit considerable variation. In general Refugio tibiae are less a-p elongated than other groups. The male mission samples differ significantly ($F=4.94$, $df=2,51$, $P<0.025$), but the females do not ($F=2.85$; $df=2,42$, $P>0.05$). In males, the source of the significant differences is the greater a-p elongation of Capistrano and Pecos Church. The same pattern is seen in females.

Tables I-12 and I-13 present femur and humerus robusticity indices as well as the dimensions from which the indices were computed. Refugio femora are robust. Only Glaze 6 females at Pecos exceed them. Capistrano and Refugio humeri are about equally robust and both exceed Pecos Church. Pecos Glaze 6 was unavailable for this comparison because it lacks humerus circumference data.

Robusticity of upper and lower limbs might suggest the extent to which activities involve upper or lower limbs. Refugio femora are generally the most robust, but Capistrano humeri are more robust. This would fit with the idea that the Refugio population engaged in more walking and running, while the more settled Capistrano population placed more stress on the upper limbs. The differences are not great, so the conclusion must be viewed cautiously.

Table I-11. Femur and tibia cross sectional shape indices

Group	Femur Midshaft (a-p/m-l)						Tibia Nutrient Foramen (a-p/m-l)					
	Males			Females			Males			Females		
	n	x	s.d.	n	x	s.d.	n	x	s.d.	n	x	s.d.
Refugio all	27	1.072	0.147	24	1.063	0.098	27	1.402	0.154	20	1.455	0.161
Refugio Native	14	1.041	0.182	18	1.064	0.105	15	1.423	0.138	13	1.449	0.17
Pecos Church	14	1.100	0.136	14	1.037	0.127	11	1.551	0.112	8	1.621	0.380
Capistrano	15	1.088	0.131	13	1.099	0.131	16	1.519	0.177	17	1.424	0.093
Pecos Glaze 6	14	1.081	0.122	10	1.083	0.099	13	1.725	0.191	10	1.559	0.126
Le Beau Phase	96	1.118	0.084	84	1.057	0.085	96	1.604	0.180	84	1.428	0.138
Washita River	3	1.384	0.255	10	1.145	0.102	3	1.626	0.148	10	1.529	0.071

Table I-12. Femur length, a-p and m-l diameters, and index of robusticity

Group	N	Femur length		a-p diameter		m-l diameter		Robusticity	
		X	s.d.	X	s.d.	X	s.d.	X	s.d.
Refugio M (all)	20	449.8	24.12	30.45	2.86	29.05	2.42	6.60	0.31
Refugio M (NA)	11	454.64	25.57	30.09	2.39	30.00	2.79	6.61	0.39
Capistrano M	13	455.15	22.74	30.54	2.47	28.23	1.88	6.45	0.36
Pecos Church M	14	432.07	20.59	28.00	2.45	25.64	2.17	6.19	0.31
Pecos Glaze 6 M	14	423.78	20.21	27.43	3.08	25.46	1.97	6.22	0.35
Male F ratios	3, 57	6.37**		5.24**		11.34**		5.78**	
Refugio F (all)	11	421.09	27.04	26.46	2.95	24.91	2.34	6.09	0.36
Refugio F (NA)	10	423.10	27.62	26.50	3.10	24.70	2.36	6.04	0.33
Capistrano F	9	412.11	28.25	26.33	3.08	23.67	1.94	6.07	0.55
Pecos Church F	17	401.23	20.55	23.41	2.53	22.82	2.48	5.75	0.45
Pecos Glaze 6 F	9	397.89	23.12	25.67	1.52	23.61	1.62	6.19	0.34
Female F ratios	3, 42	2.11		4.21*		2.00		2.67*	

*P < 0.05; **P < 0.01

Table I-13. Summary statistics for humerus robusticity

Group	N	Humerus Length		Shaft Circum.		Robusticity Index	
		Mean	s.d.	Mean	s.d.	Mean	s.d.
Refugio Males	15	325.267	18.398	66.200	4.858	20.369	1.302
Pecos C Males	12	311.500	13.070	58.00	1.859	18.648	0.0950
Capistrano Males	14	322.143	12.563	65.643	4.378	20.398	1.459
Male F ratios	2, 38 df	2.95		16.50		9.43	
Refugio Females	9	295.778	17.683	57.444	4.391	19.444	1.397
Pecos C Females	10	288.000	14.252	52.800	3.490	18.343	1.029
Capistrano Females	15	292.067	22.211	57.200	4.127	19.642	1.454
Female F ratios	2, 31 df	0.40		4.40*		3.06*	

*P < 0.05

Multivariate Analysis of Femur Shaft Dimensions

The foregoing univariate analyses of shaft dimensions have shown that there is significant variation among the mission samples. Multivariate consideration will provide a better summary of intergroup variation. The subtrochanteric dimensions have so far been considered in relation to ancestry estimation. Here we consider the anterior-posterior and medio-lateral dimensions of both the subtrochanteric and midshaft regions together. Sexes were analyzed together so sex differences will be a component of intergroup variation.

Figure I-3 shows the first two canonical variate scores, together accounting for almost 94 percent of the total variation among groups. The first axis mainly reflects size; all variables are positively correlated with the axis. Since the analysis is based on shaft dimensions, size variation is a reflection of robusticity, although not standardized by length

as in the univariate analyses. In general, males are larger than females so have higher scores on axis 1. Refugio and Capistrano males have the largest and most robust femur shafts. The Pecos samples, whether Church or aboriginal component, have the smallest shaft dimensions. Some idea of Refugio robusticity can be gained from the observation that Refugio females have a first axis score that is similar to Pecos males.

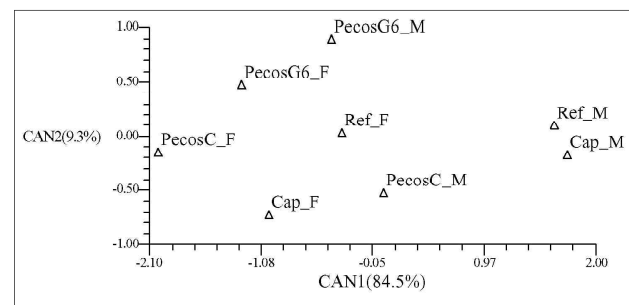


Figure I-3. Canonical analysis of a-p and m-l dimensions of subtrochanteric and midshaft dimensions of femora.

The second axis reflects platymeria. The strong platymeria of the Pecos Glaze 6 sample is evident. Whether the more moderate platymeria of the mission samples reflects the non-Native components they likely contain is not possible to say, but is suggested by the lower scores of the Pecos Church component.

The distance between points of males and females of the same group can be taken as a reflection of sexual dimorphism within the group. By that measure Capistrano is the most dimorphic and Pecos Glaze 6 the least. There is no evidence that Refugio is excessively dimorphic. Univariate analysis of sex dimorphism (not shown) is not significant, so it is not likely any of the sex differences seen on the plot are significant.

Body Weight and Physique

Estimation of body weight is more difficult than estimating height and consequently has received less attention. Weight is more plastic than height and calibration samples where weight is known in life and bone dimensions are measurable are uncommon. However, some idea of weight is required in order to develop an appreciation of overall body size of the Refugio sample. Ruff et al. (1991) have shown that joint surface size allows reasonable estimation of weight. We use Ruff et al.'s (1991) regression equation to estimate weight from the femur head diameter. These equations are not without problems. Ruff et al.'s calibration sample was made up of 80 outpatients from the Johns Hopkins Hospital. The increase in body weight of Americans over the past 100

years is well known. Some of the increase in weight could be attributed to secular increase in height, but increasing adiposity causes the majority. Ruff et al. (1991) suggest decreasing the estimate by 10 percent when estimating weight of pre-industrial populations who would have been leaner.

Table I-14 presents the summary statistics of femur head diameters for the Refugio sample and comparative mission samples and other coastal Texas samples. Also included is the body weight estimate using equations produced by Ruff et al. (1991). The Refugio femur head diameters are greater than any other mission sample, although only marginally larger than the Capistrano sample. Femur head diameter is one of the few variables that shows a significant difference between individuals identified as Native and those identified as non-Native (Native: mean = 48.045, sd=1.939; non-Native: mean = 46.471, sd=2.741; $t=2.10$, $p<0.05$). Females show no difference between Native and non-Native.

Although larger than other mission samples, Refugio femur head diameters are exceeded by Plains Woodland and recent American Whites. Refugio also exceeds the other Texas Coast series from Oso. Mitchell Ridge femur head diameters are presented only as pooled sex values, and the femora from the Palm Harbor site are unsexed. At Palm Harbor, the maximum value of the four femora with measurable head diameters is 46, making it unlikely that femur head size would approach Refugio. At Mitchell Ridge the pooled sex values do not suggest that the femur heads would equal or exceed those at Refugio.

Table I-14. Femur head diameters and estimated weights for Refugio and various comparative samples

Group	Males				Females			
	n	Mean	s.d.	Estimated weight	n	Mean	s.d.	Estimated weight
Refugio (total)	39	47.359	2.422	67.4	26	41.539	2.642	59.2
Refugio (Native)	22	48.045	1.939	69.1	20	41.450	2.665	58.9
Capistrano	15	46.667	2.320	65.7	13	41.000	1.871	57.9
Pecos Church	14	44.429	2.344	60.2	16	39.563	2.366	54.8
Pecos Glaze 6	15	43.567	2.259	58.1	10	39.200	1.398	54.0
Oso	6	44.667	2.805		3	42.667	2.309	
Plains Woodland*	22	48.8	2.7	71.0	21	42.5	2.4	61.2
Plains Coalescent*	238	47.0	2.1	66.5	191	42.4	2.1	60.0
American Whites	95	48.379	2.446	77.7	61	42.246	2.292	67.4

*From Cole (1994)

Refugio estimated body weights are high compared to other samples in Table I-14, exceeded only by Plains Woodland and American Whites, and in females, Plains Coalescent as well. There is no way to evaluate the accuracy of these estimates, except to note that they agree with Ruff et al.'s (1991) estimates for Pecos derived from other methods (59 and 54 kg for males and females respectively), and reasonably well with American national values (76.4 and 64.5 kg for males and females respectively) in the Hanes data (Johnston and Schell 1979).

Body weight in relation to height, expressed as kg/m² or body mass index (BMI) is commonly used as a measure of nutritional status in recent populations. It is an imperfect measure because it is influenced by a number of other factors such as body shape and composition (Norgan 1994; Norgan and Jones 1995) Applying it to the Refugio sample, where both height and weight are estimates may be over extending, but will serve the purpose of casting Refugio body size and shape into more commonly understood measures.

Table I-15 presents Refugio weight, height (from Table I-10) and BMI and comparative data on various recent living Native American samples taken from Johnston and Schell (1979). Recent samples are the only ones where weight has been measured directly, but comparison must be done cautiously because Native Americans have been particularly susceptible to weight gain as they assume Western diets. Weights of the Refugio sample are generally less than those of the taller tribes of northern North America. The estimated weights exhibit about the same degree of sex dimorphism as that seen in other groups. Comparing height and weight via BMI, the Refugio sample is similar to the Navaho, or in the case of males, to the Eskimo. Refugio heights, weights, and BMI exceed the Mesoamerican samples by a

considerable margin. Mesoamerican values are less likely to have been influenced by recent weight gain than the North American values. Considering that the Karankawa, by our reconstructions, are a relatively long legged population, the BMI is high.

Weight or BMI estimates can not be used in their usual sense of indicating energy stores. Weight estimated from femur head diameter would reflect an ideal, but emaciation resulting from undernutrition would not be reflected in femur head diameter. If the population was not emaciated, then the BMI is probably a reasonable reconstruction of physique. Their relatively high BMI must reflect high bone mass and presumably muscle mass as well.

Growth of Children

Growth status of children assessed by stature provides an indication of their health and well being. In archaeological samples long bone lengths can take the place of stature but there are several problems in using archaeological samples in this way: 1) chronological age is unknown and must be estimated from dental age; 2) the data are necessarily cross sectional; 3) the age distribution is the age at death distribution; 4) sex is usually unknown; and 5) the sample represents those who died prematurely and may therefore reflect suboptimal growth. Saunders (1993) has reviewed the last problem and concluded that the bias is likely to be small in relation to other effects.

Archaeological samples normally have high infant mortality rates (Jantz and Owsley 1994). We have shown that bone lengths of perinatal infants expressed as gestational age provides another avenue for examining health status of archaeological populations (Owsley and Jantz 1985).

Table I-15. Estimated heights, weights, and BMI for Refugio sample compared to measured values in various recent North American and Mesoamerican samples

Group	Males				Females			
	n	Height (cm)	Weight (kg)	BMI	n	Height (cm)	Weight (kg)	BMI
Refugio	39	165.0	67.4	24.8	26	154.0	59.1	24.9
Blackfoot	98	174.8	75.8	24.8	133	161.1	69.5	26.8
Ahousat	36	170.4	79.6	27.4	45	158.3	65.6	26.2
Navaho	272	169.5	65.0	22.6	245	156.0	58.1	23.9
Eskimo	43	166.3	67.2	24.3	37	155.8	66.3	27.3
Seminole	94	169.5	76.5	26.6	143	157.2	69.1	28.0
Sioux	224	174.4	75.9	24.97	195	161.6	70.7	27.1
Otomie	101	157.0	52.6	21.3	100	144.5	46.9	22.5
Nahua	100	154.8	49.5	20.7	100	143.5	44.4	21.6
Mayan	104	155.4	54.2	22.4	94	141.8	47.5	23.6

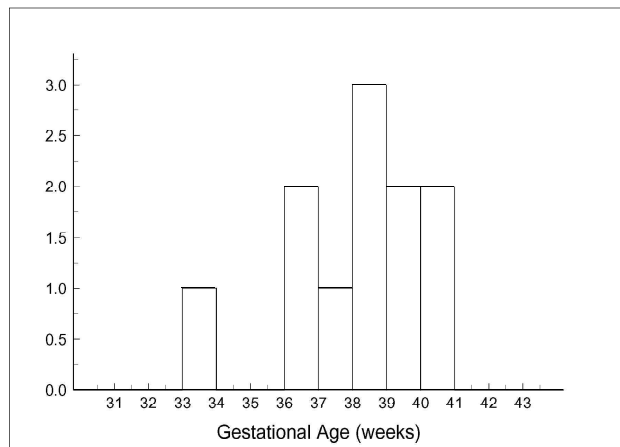


Figure I-4. Histogram showing gestational age of perinatal infants from the Refugio sample.

Long bone lengths of Refugio children are few in number. Lengths were available from 62 long bones representing 20 individuals. The femur, available for 13 children under 18, is the most common bone. Dental ages using Moorrees et al. (1963a, 1963b) criteria were available for nine individuals, six of which possessed a femur.

Figure I-4 presents a histogram of gestational ages estimated from regression equations presented in Scheuer et al. (1980). The mode of the distribution falls on the 38-39 week interval. This corresponds well to the precontact and early postcontact Arikara (Owsley and Jantz 1985). There is a minor mode containing of two individuals in the 36-37 week interval, which could be termed slightly premature or small for date infants, but they are well within the range of normal variation. The only clearly premature infant is 33 weeks. This is the case of congenital trepanomatosi described earlier. It must represent a premature birth, a spontaneous abortion, or death of the mother. It demonstrates how the disease environment can affect fetal development.

A dental age estimate was available from six individuals possessing a measurable femur. Figure I-5 presents these six femora plotted against dental age. Figure I-5 also includes the mean femur lengths from the Denver growth study as a control. Although numbers are small, there is no evidence that Refugio children are consistently small. Rather, it suggests that Refugio children were growing in a manner comparable to well nourished White children. The major caveat is that age of Refugio children is dental, while chronological age is known for the Denver children. It has

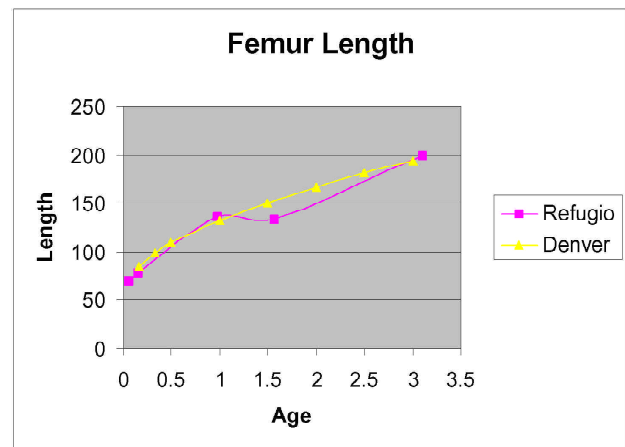


Figure I-5. Femora lengths for children from the Refugio sample plotted against dental age. Mean femora lengths from the Denver growth study are included as a control.

been shown that dental development in Native American children is precocious compared to White children (Jantz and Owsley 1994; Lovejoy et al. 1990; Owsley and Jantz 1983). If Refugio children are also precocious, then bone length for age is an underestimate. Conversely, if Refugio children are retarded relative to White children, then growth curve is an overestimate.

Discussion

In spite of relatively fragmentary and incomplete skeletons, we can develop a fairly reliable picture of Karankawa physical characteristics as revealed by the Refugio mission sample. A major point concerns the failure of the osteological evidence to support the ethnohistorical record concerning the tall stature of the Karankawa. Several examples will suffice to illustrate:

“the average height of the men being fully six feet”
(J. H. Kuykendall in 1857, cited in Wilkinson 1977).

“...they might have been giants for they were the most magnificent men in size and strength, seldom below six feet in height” (John H. Jenkins in 1884, cited in Wilkinson 1977).

“They were the most savage looking human beings I ever saw. Many of the bucks were six feet in height with bows and arrows in proportion”
(Noah Southwick, cited in Newcomb 1961).

These ideas have been perpetuated in the recent scientific literature. Ricklis (1996:9) reviews the ethnohistorical record, concluding that their physical stature "...set them apart from neighboring Indian groups" and that "...men not infrequently attained statures approaching or reaching six feet." The direct analyses of related skeletal series have also commented upon the stature (Comuzzie et al. 1984; Wilkinson 1977; Woodbury and Woodbury 1935). One suspects that interpretations of the skeletal data have been influenced by the sometimes florid ethnohistoric accounts of great size and ferocity rather than using skeletal data to independently evaluate Karankawa body size.

We consider it likely that earlier estimates of stature are too high because they are based on formulae derived from groups with relatively short legs. Trotter and Gleser (1958) "Mongoloid" formulae are the worst offenders in this regard, consistently producing high estimates. Ricklis (1996:10) singles out the largest estimate of the tallest individual (183.4 cm; 72.2 in.) in the Palm Harbor series as supporting evidence. The Genoves estimate of the same individual is over a centimeter less, and it too is probably too high. Furthermore, the length of the femur itself is an estimate from a fragment with a 25 mm error of estimate. Wilkinson's (1977) estimate of 5'9" as an average stature for remains from the Shell Point site is based on Trotter and Gleser (1958), presumably the "Mongoloid" formulae, but that is not stated explicitly. By our reasoning, the estimate could be 2-3 inches too large, which would bring it into line with our estimates for the present Refugio sample. Woodbury and Woodbury's (1935) estimates are based on Pearson's formulae derived from English skeletons, which would also overestimate height if applied to relatively long-legged population.

Anthropometric features are typically patterned geographically. It would be unusual for a single tribe to significantly exceed its neighbors in a feature such as stature, unless there were marked ecological differences as well. Viewed from the perspective of average stature in nineteenth-century Native Americans as revealed by Boas' data, the Karankawa are about average. If we take heights to be about 167 cm and 155 cm for males and females respectively, they fall at about the 60th percentile in Boas' 200 or so tribes, i.e., slightly above average. Even if one accepts the various stature estimates we have argued are too great, none approaches six feet for males. Early European observers were themselves not likely to be especially tall, and the robusticity coupled with body decoration and myths of cannibalism likely contributed to this exaggeration in stature.

An account in 1528 from shipwrecked Spaniards summarizes the basis of height exaggeration as well as anything "Our fright was such that, whether tall or little, it made them appear giants to us" (cited in Wilkinson 1977).

Karankawa limb proportions are somewhat "tropical" in exhibiting elongation of distal segments. Although Doran's (1975) survey showed the similarity of Texas Indians generally to American Blacks in the brachial and crural index, this has not been factored into decisions about what formulae to use in stature estimation. Whether Karankawa limb proportions can be considered climate adaptations, as has been argued for limb proportions of Old World tropical peoples (Holliday 1997, 1999) is debatable. Although mild, the south Texas climate could not be considered tropical. Holliday (1999) has shown that elongation of distal segments is present in Upper Paleolithic and Mesolithic Europeans, even though they inhabited Europe for thousands of years during the last glacial period. That could mean that limb proportions are evolutionarily conservative, as Holliday (1999) maintains, or that other factors, perhaps biomechanical in nature, are responsible for some of the variation.

The only sense in which the Karankawa, as represented in the Refugio sample, can be considered large is in their robusticity. The metric features bear out what is clearly apparent to anyone who has examined the bones, that they are robust bones with large joint surfaces. In contrast to the historical record, however, they are not excessively large compared to Capistrano. Our comparative framework is not large, limited in most instances to the mission samples, so generalizations are probably unwise. Nevertheless, our data seem to show that the south Texas Indians, as seen at the Refugio and Capistrano missions, were not strongly differentiated. They differ markedly from the Pueblo populations seen at the Pecos mission. Doran's (1975) data on long bone lengths supports this idea. He found that Coastal and Central Texas bone lengths were considerably greater than those of the Trans-Pecos region. Direct stature data from four Texas tribes (Tonkawa, Apache, Caddo, and Comanche) collected by Boas also do not suggest strong differentiation.

The perception of Karankawa as robust receives more support from our analysis, although they are by no means unique in this regard. The Capistrano population was about equally robust and both exceed Pecos. Cole's (1994) Plains samples, except for Woodland, are generally less robust than Karankawa. Collier (1989) presented data for seven populations encompassing a wide range of subsistence and

activity patterns (Australian Aborigines, Whaling Eskimos, Riverine Eskimos, Arikara, Terry Whites, and Romano-Britians). The Refugio sample is in the high range of this diverse sample, consistently exceeded only by Whaling Eskimo.

The Refugio data do not support Ruff's (1987) hypothesis that femur anterior-posterior expansion at midshaft reflects activity. They might be taken to support Ruff's recent modification of that hypothesis that anterior-posterior expansion is more tightly associated with rugged terrain. That idea is in conflict with the extreme anterior-posterior expansion of Southern Plains femora (Ruff 1994).

Body weight of the Refugio sample, estimated to the best of our ability, falls well within the range of recent Native Americas. Body Mass Index suggests a strongly built physique. Maintaining high body weight is metabolically expensive and in turn suggests efficient foraging (Sorensen and Leonard 2001). The limited growth data also show the children to have been adequately nourished.

For whatever reasons, the historical record has distorted the perception of the Karankawa, making them into fearsome giants markedly different from their neighbors. Fearsome they may have been, but they projected that perception of themselves with modest height and robusticity not much different from other tribes in the region. This should make the value of objective examination of the skeletal remains evident. Otherwise, we should continue to think of the Karankawa in terms dictated by the distorted historical record.

Osteological Analyses

Section J

Metric Analysis of Cranial Morphology

Crania from Refugio are so fragmentary that few of the usual cranial morphometric analyses can be carried out. We have adopted two approaches to attempt to glean some information from the limited fragmentary cranial remains. The first focuses on midfacial size and robusticity. One measurement that quantifies facial robusticity is cheek height (WMH in Howells' 1973 definitions). In both Howells' (1973) and Key's (1983) factor analyses, cheek height is the major contributor to a midfacial size factor. Cheek height can be measured if the malar inferior to the orbit is intact. The measurement is commonly available even in the most fragmentary crania.

The second approach consists of assessing similarity of the few crania on which some measurements can be obtained to world samples. This allows characterization of individual crania in terms of world cranial variation. It should answer the question of whether crania from Refugio are typical of other Native Americans in our sample, or whether they exhibit differences. This approach has been described and utilized in Jantz and Owsley (2001).

Midfacial Robusticity

Figure J-1 presents the Refugio mean in relation to world variation for cheek height. World variation is very clearly patterned. In general, low values are seen in African and Southwest Pacific populations, increasing through Europe, East Asia and America, and ending with Polynesia and Buriat of Siberia with the largest values. Clearly Refugio ranks toward the upper end of the range. In males it is the fifth highest mean, in females the seventh. Populations with large values are mainly Pacific Rim groups. In both sexes Refugio exceeds all Native American samples except Sioux.

Table J-1 compares Refugio to Mitchell Ridge, Capistrano, and Pecos Church and Glaze 6. Raw data for Mitchell Ridge were kindly made available by Joe Powell. The sample includes the prehistoric, protohistoric, and historic components. The majority of Pecos crania are from the Church. There were insufficient numbers from Glaze 6 to constitute a separate sample. Variation among the four groups is significant in males but not quite in females. There is a clear pattern, Refugio and Mitchell Ridge are large, and

Capistrano and Pecos are smaller. The subsample of Refugio consisting only of those we considered Native American is slightly larger in both sexes.

Similarity to World Samples

Similarity to world samples of individual crania with a sufficient number of variables to be meaningful is presented in Table J-2. The table gives the Mahalanobis distance of each specimen to the five most similar groups. The number five is arbitrary, but should provide an indication of the part of the world to which a skull is most similar. We offer some comments on the morphometric affinities of each skull.

Comments:

BP22-82 – (25 measurements). This is the most complete cranium in the sample. It was identified as Hispanic on the basis of morphology (see Appendix IIA, Burial Descriptions). The principal length and breadth dimensions of the vault, as well as face dimensions are available. It affiliates fairly strongly with Native Americans. Metrically the skull is wide, especially at the base, the face is high, the frontal flat and the vault low. Apart from Arikara, the other groups to which it is similar are more generalized Native Americans, Asians, or Europeans.

BP21-076 – (12 measurements). Measurements present consist of midline length and facial dimensions. Breadths are generally lacking. Visual assessment of the skull and skeleton suggest Native American ancestry. The vault is quite short—this and its facial robusticity mainly align it with Native Americans.

BP24-085 – (9 measurements). Measurements present consist of vault breadths, and midface and frontal dimensions. Affinities are mainly Polynesian and East Asian. The face is robust with low, wide orbits.

BP22-129 – (8 measurements). Measurements consist of vault breadth, and midface and frontal dimensions. Regional affinities are inconsistent but distance to Eskimo is substantially smaller than any other group. The similarity to Eskimo results from a narrow nose, narrow vault, and long, curved frontal.

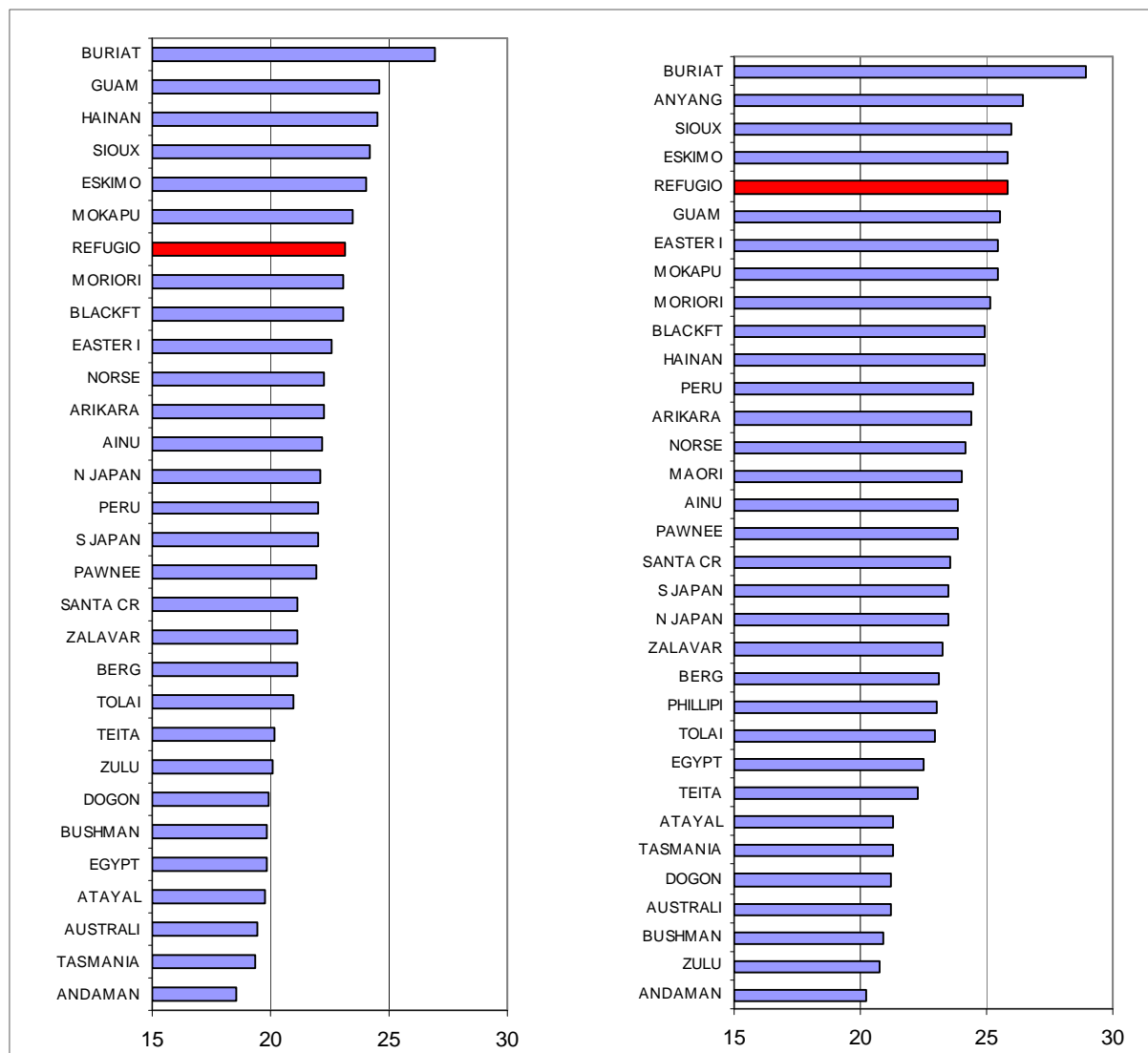


Figure J-1. Comparison of cheek height of Refugio to world populations as a measure of robusticity (females on left, males on right).

Discussion

We know relatively little about the cranial morphology of the Karankawa and the Refugio sample sheds little additional light on the problem. Generalizations have proved difficult due to small and fragmentary samples (Steele et al. 1999). However, Karankawa are considered to be the recent manifestation of relatively homogeneous coastal populations with considerable historical depth in the region. These coastal populations have been characterized by extreme dolichocrany, cranio-facial robusticity, and high sexual dimorphism, features thought to set them apart from inland populations such as Coahuiltecans (Steele et al. 1999).

Our analysis of midfacial size supports the robusticity hypothesis, placing the Refugio sample in the upper ranges of worldwide variation and larger than most Native Americans for which data are available. It should be stressed that robusticity is a complex, multidimensional feature. The single dimension used here, cheek height, quantifies only midfacial size. Populations of the Southwest Pacific are generally considered robust because of large cranial superstructures such as brow ridges and large teeth (Lahr 1996), but in the midfacial region they are gracile. Cranial superstructures may respond to masticatory stress, but that

Table J-1. Cheek height summary statistics for Refugio, Mitchell Ridge, Capistrano, and Pecos

Group	Males			Females		
	N	Mean	s.d.	N	Mean	s.d.
Refugio	12	25.833	2.125	7	23.143	3.237
Refugio (N.A.)	7	26.143	2.268	6	23.667	3.204
Mitchell Ridge	6	26.833	2.483	6	23.667	2.041
Capistrano	11	23.182	2.183	13	21.154	2.340
Pecos Church + Glaze 6	24	24.125	2.894	18	21.445	1.723

Males: $F=3.853$; $df=3,49$; $p < 0.025$ Females: $F=2.70$; $df=3,40$; $p > 0.05$

Table J-2. Mahalanobis distance of Refugio crania from world population samples

Burial	N	Groups Closest Mahalanobis D ²				
	Measurements					
BP22-082	25	Arikara 24.41	Philippine 28.08	Peru 28.88	Zalavar 28.91	Santa Cruz 29.77
BP21-076	12	Om/Ponc 5.11	Berg 8.96	Pawnee 9.03	Arikara 11.64	Blackft 11.79
BP24-085	9	Moriori 8.8.38	Guam 9.332	Buriat 10.802	Arikara 11.435	Anyang 11.657
BP22-129	8	Eskimo 21.230	E. Island 36.198	Teita 36.998	Australia 37.146	Guam 37.167

seems an unlikely explanation for midfacial size. Rather, the Refugio sample, presumably predominately Karankawa, falls into the general pattern of Asian and Pacific populations with heavy faces. We consider this likely to be primarily a genetic phenomenon, since it cross cuts numerous adaptive patterns and environments.

Karankawa crania have also been considered robust in the more general sense (Wilkinson 1977). Our data are not adequate to address this question further, except to say that our general impression is one of considerable robusticity. The postcranial analysis showed the Refugio sample to be robust, but not markedly greater than Capistrano. By contrast Refugio is more robust than Capistrano, at least as far as midfacial size is concerned.

Another component of Refugio cranial morphology that has become ingrained in the literature is that they are unusually sexually dimorphic (Comuzzie 1987; Comuzzie et al. 1984; Wilkinson 1977). From the sex means of midfacial size in Table J-1 we can see that Mitchell Ridge is the most dimorphic, followed by Refugio and then closely by Pecos. Only Capistrano shows lower dimorphism. Some context

can be provided by the world database. A comparison of Refugio sex dimorphism to 30 world samples shows it exceeds all but two (Egypt and Easter Island). Mitchell Ridge actually exceeds all samples. Hence there is some quantitative support for the idea that Karankawa are highly dimorphic by world standards. However, the Pecos sample is about as dimorphic as Refugio, and several Native American groups in the world sample approach Refugio in dimorphism. By Native American standards they are not markedly dimorphic. Resolution of the issue will require additional work.

Unfortunately, our data are not able to shed any light on the more general aspects of Karankawa cranial morphology. Of the four crania with measurements, two (one of which is likely not Native) do not exhibit dolichocranic morphology. Another has no vault measurements. Only one has the narrow vault often associated with Karankawa.

Osteological Analyses

Section κ

Dietary Variation, Ethnicity, and Mobility

Lynnette Norr's analysis of stable isotopes of Carbon and Nitrogen provides insight into the overall dietary pattern of those buried in the cemetery at the Refugio mission (Appendix II-E). Norr was unable to identify significant variation among our ethnic assignments, age, or sex, except that Europeans are slightly enriched in ^{13}C . In this section we undertake some additional analyses designed to address some broad questions about the composition and behavior of the mission population. As will be demonstrated below, the Refugio sample exhibits a highly variable isotopic pattern. The variation indicates that there were likely two or more patterns of dietary behavior being followed by mission residents. There are two issues we will attempt to address: 1) Do subgroups exist, and if so, to what extent do they correspond to our original ethnic assessments; 2) Does the dietary information allow statements about permanency of residence at the mission.

Dietary Subgroups

Gaussian Mixture

In order to estimate group structure, a Gaussian mixture model was fit to the data. The model has the multivariate normal form:

$$\phi_k(X | \mu_k, \Sigma_k) = (2\pi)^{-\frac{p}{2}} |\Sigma_k|^{-\frac{1}{2}} \exp\left\{-\frac{1}{2}(x_i - \mu_k)^T \Sigma_k^{-1} (x_i - \mu_k)\right\}$$

Where x represents the data, and k is an integer subscript specifying the k^{th} cluster (Fraley and Raftery 1999). Clusters are ellipsoidal, centered at means μ , the covariance matrices, Σ , define the geometric attributes of the distributions. Each covariance matrix is parameterized by the eigenvalue decomposition in the form:

$$\Sigma_k = \lambda_k D_k A_k D_k^T$$

Where D_k is the orthogonal matrix of eigenvalues, A_k is the diagonal matrix whose elements are proportional to the eigenvalues of Σ_k , and λ_k is a scalar. The orientation of the covariance matrix is determined by D_k , while A_k determines the shape of the density contours, λ_k specifies the volume of the corresponding ellipsoid, which is proportional to

$\lambda_k^d |A_k|$, where d is the data dimension (Fraley and Raftery 1998, 1999). The method is applied by use of the E-M algorithm, which estimates the parameters of each distribution by the method of maximum likelihood. The likelihood function for the mixture model is given by:

$$\prod_{i=1}^n \sum_{k=1}^G \tau_k \phi_k(x_i | \mu_k, \Sigma_k)$$

The E-M steps through the parameterization by first iterating the 'E' step, which forms the z matrix, where z_{ik} is an estimate of the conditional probability that observation i belongs to group k , given the current parameter values. The 'M' step then computes the maximum likelihood parameter, given the matrix z (Fraley and Raftery 1999). Thus, the likelihood is iterated until convergence is reached, or no significant change occurs in the likelihood. The final estimates of the algorithm represent the best estimates of the k^{th} cluster's mean vector, μ , and covariance matrix, Σ . The final estimate of the z matrix, also gives the conditional probability of the i^{th} observation being in the k^{th} cluster. As will be seen, this method is very useful in the present situation, where the number of clusters is unknown, but at least two are suspected.

In order to test for the best solution to the data, a parametric bootstrap of the likelihood ratio test was performed. This test is based on sampling with replacement many times a 2-cluster log-likelihood and a 1-cluster log-likelihood, and obtaining their ratio. This type of test is preferred over a likelihood ratio Chi-square because unless infinite sample sizes are assumed, the traditional Chi-square test is invalid. The critical value is obtained by comparing the observed likelihood ratio to the distribution formed from the bootstrap. Five hundred bootstrap simulations were performed for a 2-cluster versus 1-cluster solution. The null hypothesis being tested is that there is a single Gaussian distribution present in the data versus more than 1 distribution.

Cluster Solutions

Figures K-1 and K-2 show the histograms of the bootstrapped likelihood ratio tests for the 2-cluster versus 1-cluster and 3-cluster versus 1-cluster. Both 2- and 3-cluster solutions are highly significant, allowing rejection of the null hypothesis that one population may explain isotope

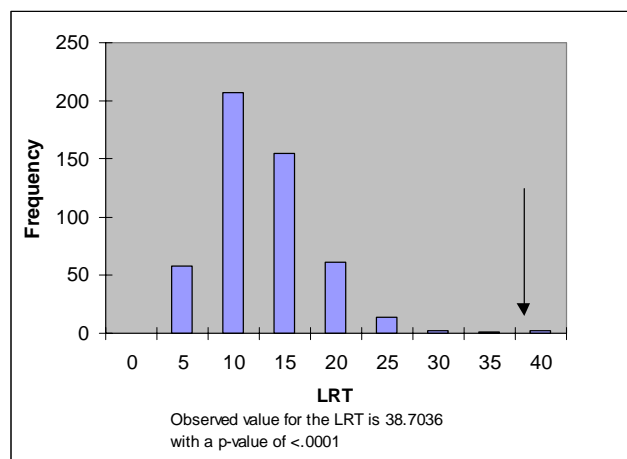


Figure K-1. Bootstrapped likelihood ratio test for a 2-cluster versus a 1-cluster finite mixture model.

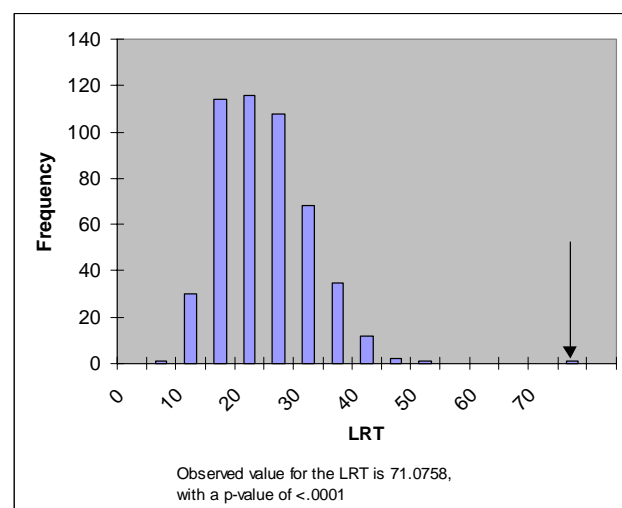


Figure K-2. Bootstrapped likelihood ratio test for a 3-cluster versus a 1-cluster finite mixture model.

variation. The 3-cluster solution fits better than the 2-cluster solution, so we conclude that there are three dietary subgroups present at Refugio.

Table K-1 gives the means and standard deviations of ^{15}N and collagen ^{13}C for the total sample and the three clusters identified. It is evident that the total sample is much more variable than the individual clusters, particularly for ^{13}C . ^{13}C exhibits much more variation among clusters than does ^{15}N . Figure K-3 plots the isotope values. Cluster 1 is the far left group, characterized by low values of ^{13}C . Cluster 2 is

Table K-1. Collagen ^{15}N and ^{13}C values for clusters identified by Gaussian mixture

Group	n	^{15}N	s.d.	^{13}C	s.d.
Total sample	54	11.930	0.924	-10.911	2.238
Cluster 1	4	11.750	0.627	-16.225	0.795
Cluster 2	31	11.582	0.775	-9.323	0.832
Cluster 3	19	12.554	0.762	-12.447	0.661

F ratio ^{15}N = 9.707; df = 2,51; $p < 0.001$

F ratio ^{13}C = 197.188; df = 2,51; $p < 0.001$

the far right group, greatly enriched in ^{13}C . Cluster 3 is the central group intermediate in ^{13}C and somewhat enriched in ^{15}N . This plot is comparable to Norr's Figure II-E-4 (Appendix II-E) where these clusters are to some extent identifiable visually. Figure II-E-4 in Appendix II-E shows that the clusters we have identified are somewhat heterogeneous regarding ethnic assignments. Figure K-4 shows the distribution of the individuals within each cluster and their relation to the burial features in the site. That raises the question of whether the ethnic groups are randomly distributed among the clusters.

Figure K-5 shows the plot of Carbon apatite versus collagen. This comparison is useful in determining the overall makeup of the diet because the apatite value can be interpreted as the percentage of C_4 plants in the diet (Ericson et al.

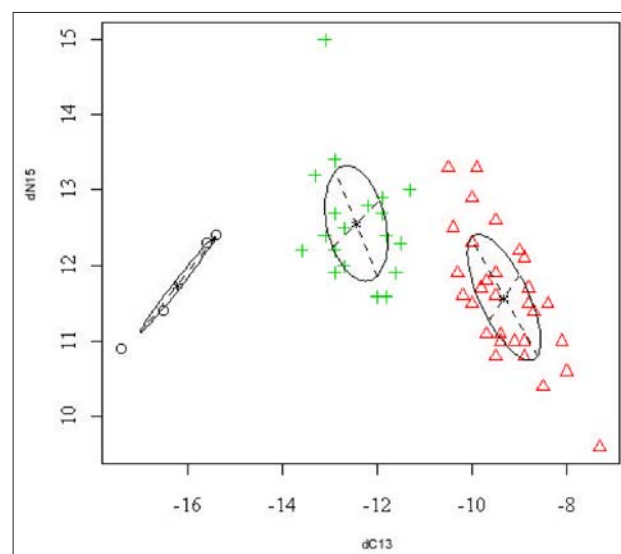


Figure K-3. Plot of 3-cluster solution with clusters surrounded by their one standard deviation ellipses.

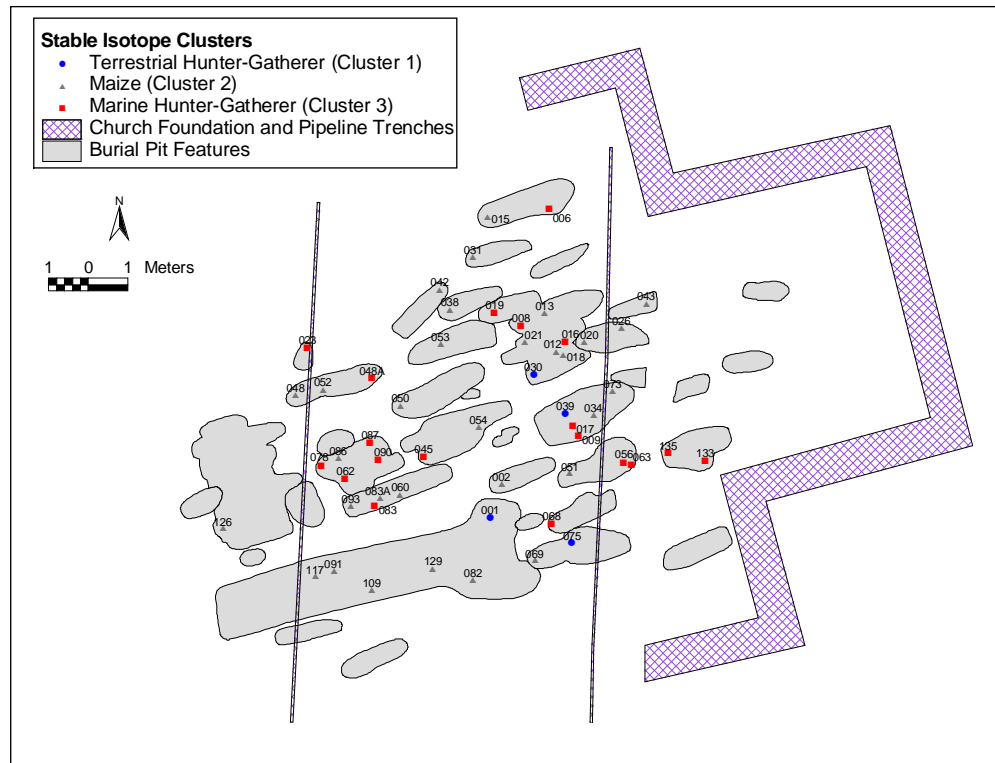


Figure K-4. Individual burials assigned to stable isotope clusters by feature.

1989:#5342). It is evident that the Refugio sample is mostly within the bounds of the mixed, predominantly maize group (#6) and the CAM plant/ C_3 meat group (#9). This indicates a diet reliant on maize and C_3 meats for the majority of the sample.

The overall distribution of the Refugio sample is similar to values for the Copan and Petén Maya (Gerry and Krueger 1997:#5343) who are considered to have a diet heavily dependent upon maize. In addition, a segment of the sample is similar to that of Huebner (1991:#5344), in that they appear to be dependent on CAM plants and C_3 meats. One individual is an obvious outlier in having an extreme level of protein intake represented by the dramatic departure from the carnivore demarcation. This represents an intake of protein much higher than required for normal growth and

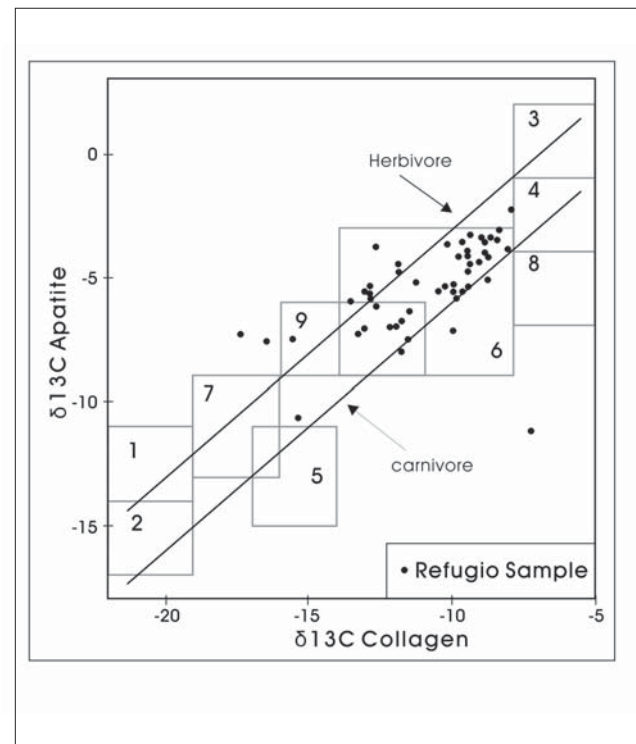


Figure K-5. Plot of Carbon apatite and collagen values for the Refugio sample. Human dietary groups: 1) C_3 Plants; 2) C_3 Plants + C_3 Meats; 3) C_4 Plants; 4) C_4 Plants + C_4 Meats; 5) Marine only; 6) Mixed, mainly maize; 7) C_3 Plants + Marine; 8) C_3 Plants + C_4 Meats; 9) CAM plants and C_3 Meats. After Krueger (1985) and Huebner (1991).

Table K-2. Distribution of ethnic groups by dietary cluster

	Native	Hispanic	European	Indeterminate	Total
Cluster 1	3	0	0	1	4
Cluster 2	18	3	4	6	31
Cluster 3	13	4	0	2	19
Total	34	7	4	9	54

Chi-square = 4.85; df = 4; P = 0.30 (excluding indeterminates)

Chi-square = 4.93; df = 4; p = 0.29 (indeterminates = Native)

development (Ericson et al. 1989:#5342). Several other individuals fall outside of the previously described dietary regions. This is most certainly due to unusual dietary practices of a small segment of the population.

Ethnic Variation

Table K-2 presents a contingency table of the distribution of our ethnic assignments in the three clusters. We performed two Chi-square tests, one omitting the indeterminate and one assuming the indeterminate are Native, which is their most likely affiliation. Neither is significant, so may accept the null hypothesis of equal distribution of ethnic groups among dietary clusters. The one pattern that may be meaningful is that all four individuals we have designated European fall into cluster 2, but the European cells are so sparse that it does not become statistically significant.

Refugio Dietary Variation in Regional Perspective

In order to understand the variation seen in the diet at Refugio, we must consider the amount of variation seen in other Native American groups local to the region. The comparisons offered here are critical to the understanding of the diet of the Refugio mission population. Figure K-6 shows the comparison of ^{13}C and ^{15}N concentrations for the Refugio sample as well as other Texas archaeological samples from varying time periods. Table K-3 gives the relevant temporal information and summary statistics for the sites included in the comparison. It is evident from Figure K-5 that the diet of the Refugio sample is highly variable in comparison to the comparative data. The range of diet at Refugio encompasses both maize intensive diets (San Juan Capistrano), and terrestrial hunter-gatherer diets (Bearing Sink, Mitchell Ridge).

The variation in the Refugio diet is easily recognized in the results of a discriminant function using the Carbon and Nitrogen isotopic values. The results of a jackknife cross-validation procedure reveal that 63 percent of the Refugio sample is misclassified. The low amount of dietary variation in other samples is also shown in this procedure. For instance, 94 percent of the Bearing Sink sample classifies correctly, and 84 percent of the San Juan Capistrano sample classifies correctly. This points to the low degree of variability in these samples in comparison to the Refugio sample.

An ANOVA model indicates that significant regional and temporal variation exists in the isotope data. Figure K-7 shows the plot of regional sample isotope means and Figure K-8 shows the isotopic means plot by time-period. The ANOVA model is highly significant for both comparisons, and its results are shown in Table K-4.

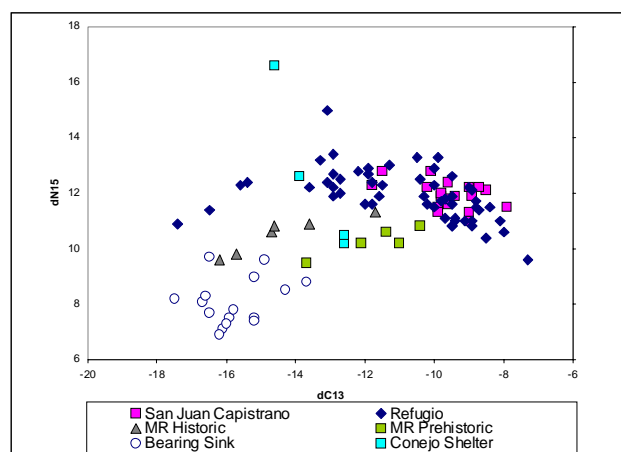


Figure K-6. Plot of Texas regional sample collagen isotope values.

Table K-3. Sample statistics for sites used in Texas regional analysis

Site	Time Period	Region	N	Mean $\delta^{15}\text{N}$	s.d.	Mean $\delta^{13}\text{C}$	s.d.	Reference
Refugio	Historic	East	52	11.93	0.92	-10.91	2.24	Norr (2001); Present Study
San Juan Capistrano	Historic	Central	19	11.9	0.49	-9.59	0.94	Cargill and Hard (1999)
Mitchell Ridge	Protohistoric-Historic	East	6	10.48	0.74	-14.36	1.79	Huebner (1994)
Mitchell Ridge	Preceramic-Late Prehistoric	East	5	10.26	0.50	-11.72	1.27	Huebner (1994)
Conejo Shelter	Late Archaic	West	4	12.47	2.95	-7.80	0.56	Huebner (1991)
Bearing Sink	Archaic	West	16	8.09	0.85	-15.77	0.97	Bement (1994)

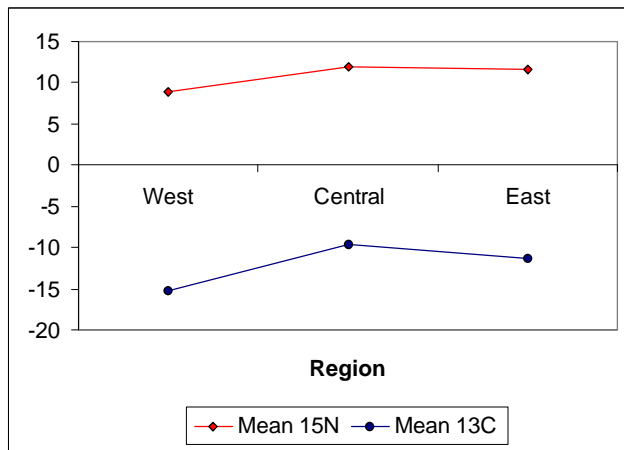


Figure K-7. Isotopic means by geographical region.

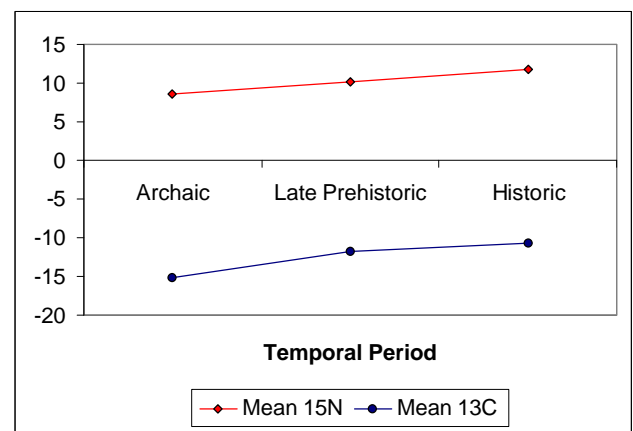


Figure K-8. Isotopic means by temporal period.

Table K-4. ANOVA results for regional and temporal comparisons

Model	Isotope	R^2	F ratio	P
Regional	^{13}C	.467	44.34	<.0001
	^{15}N	.418	36.28	<.0001
Temporal	^{13}C	.415	35.94	<.0001
	^{15}N	.453	41.86	<.0001

The regional trend suggests that the Central Texas region has significantly higher ^{13}C and slightly higher ^{15}N values than both the eastern and western Texas groups. The less negative values of ^{13}C for the central Texas sample indicate a higher degree of maize reliance than the other regional groups. Both the central and eastern samples have significantly higher values of both ^{13}C and ^{15}N indicating a higher degree of reliance on C_4 grasses and Nitrogen rich marine foods compared to the west Texas samples.

The results of the temporal model indicate an increase in both ^{13}C and ^{15}N intake into the historic period. This suggests a heavier reliance on maize in historic times, which would be expected due to the Spanish Mission system's practice of maize horticulture. The temporal differences seen in the model are considered biased due to the Archaic period samples being both from west Texas. This region shows significant differentiation from both the central and east groups. The increased ^{15}N levels are probably a result of the large sample of coastal hunter-gatherers present at the Refugio mission, who represent a large proportion of the sample from that site (see Figures K-3 and K-5).

Discussion

The dietary heterogeneity of the Refugio sample indicates the diverse subsistence strategy of its inhabitants. The population living at Refugio has isotopic signatures consistent with maize horticulturalists, coastal hunter-gatherers, and inland hunter-gatherer groups. While the Spanish mission at Refugio was no doubt a recurrent resource base for the Native American groups living in the area (Ricklis 1996), the traditional maize enriched diet was obviously not the only nutritional source utilized. The dietary pattern suggests that one segment of the Refugio population was permanently residing at the mission and consuming the traditional maize enriched diet supplemented with terrestrial mammals such as cattle. Another segment of the population was most likely residing at the mission seasonally and spending considerable time on the coast. The higher signatures of terrestrial protein and nitrogen enrichment indicate a coastal diet rich in marine resources. A third segment of the sample was consuming neither a coastal diet nor the traditional maize enriched diet of the mission. The isotopic signatures of this segment of the population resemble west Texas prehistoric hunter-gatherers, and may represent individuals foreign to the area. This dietary cluster could represent a small group of non-coastal individuals, given the known amount of contact between the coastal

Native American tribes, the Central Texas tribes (Comanche and Kiowa), and the Caddoan groups to the north. These dietary groups not only make sense based on ethnographic sources and archaeological data, but also when examined statistically using a finite mixture model.

Temporal variation in the Texas samples is closely related to the findings of Larsen et. al. (1992) in that the amount of ^{13}C increases in the historic period due to the heavy reliance on maize. Contrary to the findings of Larsen et. al. (1992) the levels of ^{15}N increase in the Texas samples into the historic period representing the bias of the historic sites toward the coast, which is also identified in the regional comparison.

Osteological Analyses

Section L

Summary and Conclusion

The preceding sections of this volume have presented our methods, findings and interpretations in detail. In this section we provide a general overview of those finding and their implications with reference to the questions set forth in Section A. The report has been organized along topical lines, each dealing with a specific component of the data. The questions set forth in Section A crosscut these categories. The goal of this section is to synthesize information from relevant sections as it relates to these questions. For easier reference, the questions are reiterated here:

1. How did violence and physical hardships of life in the frontier area affect the population of the mission?
2. What were the actual causes of death of the inhabitants of the mission?
3. What were the effects of Old and New World diseases on the populations of the mission?
4. What were the physical characteristics of the Karankawa?
5. Is there evidence of intermarrying between the groups?
6. Did the Native Americans use the mission as a seasonal resource or were they fully dependent on foods produced at the mission?

The first three questions overlap somewhat. Violence is a component of (1) and (2) and disease is a component of (2) and (3). We will therefore address the first three questions under the headings of violence, physical hardships, and disease/cause of death.

Violence

There is ample osteological evidence of violence in the Refugio sample. Much of it is in the form of scalping, which implies external aggression. It is difficult to estimate scalping rates, given the nature of the skeletal material. An approximation is possible using the number of scalped crania in relation to the number of frontals, since the frontal will normally show evidence of scalping. There are five instances of scalping identifiable among 67 complete or partial frontals. This yields a rate of 7.5 percent, which must be regarded as a conservative estimate, since partial frontals

may not preserve the evidence of scalping. The value approaches the nine percent rate observed in postcontact Northern Plains (Disorganized Coalescent) populations (Owsley 1994), suggesting that the mission population was experiencing a similar level of aggression.

The total number of skeletally identifiable trauma deaths is nine. Considered in relation to the number of burials with appreciable remains (approximately 140 have some postcranial measurement), would yield a rate of ca. 7.5 percent. This number too, must be regarded as an underestimate, since diagnostic parts of other trauma deaths are likely not present. Historical records note 26 trauma deaths out of 125 (Oberste 1942), almost 21 percent. Although additional quantification is not possible, it is clear that intergroup violence extracted a considerable toll on the mission's inhabitants. As indicated in Section E, the seasonal increase in violence may relate to availability of food at the mission. Much of this toll was likely exacted by equestrian groups such the Comanche or the Kiowa (Ricklis 1996).

In addition to those with perimortem trauma, there are four individuals, two males and two females, with antemortem trauma. Antemortem trauma is nonlethal, either healed or healing at the time of death. Antemortem trauma is somewhat more likely to represent intragroup violence than is perimortem trauma. Both males exhibit facial fractures, which likely result from fighting. Both the females may be victims of domestic violence. One in particular has the facial trauma consistent with what might be expected in domestic abuse. The level of intragroup violence is low compared with intergroup violence.

Physical Hardships

The Refugio population does not exhibit evidence of exposure to excessive physical hardship. Formation of enthesophytes may be taken as evidence of high levels of activity. The overall frequency of enthesophytes is low. In males the probability is higher that enthesophytes will form on the lower limb, while in females upper limbs are more likely to be affected, suggesting a sex difference in activity patterns. A similar sex difference may exist in lower versus upper limb robusticity.

Schmorl's depressions and spondylolysis indicate vertebral trauma or compression. They too are uncommon in Refugio, indicating that health and well being did not suffer much from physical hardships.

Disease/Cause of Death

Cause of death is notoriously difficult to infer from osteological evidence, except in the case of trauma. In addition to the trauma deaths discussed above, there is one individual with a medical condition likely to have resulted in death. The individual exhibiting the neoplastic condition, possibly multiple myeloma, is likely to have succumbed to complications resulting from this disease process.

The only infectious disease encountered was treponematosi. This is usually regarded as New World in origin. If infectious diseases of Old World origin were present at Refugio, they are not identifiable osteologically. It is possible that cases of congenital treponemal infections were responsible for death or premature birth.

The only area that suggests the Refugio population experienced adverse health affects is that of dental hypoplasia. They have high frequencies, considerably higher than those seen at Mission San Juan Capistrano, although this may be an artifact of data collection. This high frequency might indicate seasonal shortages which caused temporary growth insults, but which had no long-term significance for the individuals involved.

Karankawa Physical Characteristics

The skeletal sample is fragmentary, making it difficult to do overall assessments of morphology. That is offset to some extent by the large sample size, making it possible to obtain at least some information for most aspects of the skeleton. Our ability to generalize about the Karankawa is also inhibited by the mixed nature of the sample. We are confident that there are some individuals of mainly European ancestry in the sample, although the number is not large. Within the Native American sample a morphological assessment is further complicated by the likely presence of tribes other than Karankawa, which are unidentifiable osteologically. According to the burial records (Oberste 1942) about 85 percent of the Native American groups at the mission were identified as Karankawa. We really have no idea how differentiated Karankawa were from their neighbors. Our general feeling that postcranially at least, there were broad similarities. On that basis we feel our generalizations are broadly applicable to Karankawa.

Our data on body size are especially important in view of historic records stating that Karankawa were particularly large individuals. Our assessment of body size does not support an average height of six feet, the figure often mentioned in historic accounts. Rather our stature estimates would place the males at about 165-167 cm (ca. 5' 5"-5' 6") and females at about 153-155 cm (ca. 5' 0"-5' 1"). These heights would place them at about average or slightly above for Native Americans generally. The idea that Karankawa body size set them apart from their neighbors has made its way into the scientific literature (e.g., Ricklis 1996). We were unable to develop any skeletal support for this idea. To the contrary, Karankawa body size must have been more or less comparable to the other groups in the region.

We have also evaluated at some length stature estimation procedures that have been applied to Texas Coast populations in the past. We argue that previous stature estimates have likely been over estimates. The evidence from the Refugio sample, as well as evidence from living Texas populations, suggests that the Karankawa were likely a relatively long-legged population. Application of stature estimation formulae from short-legged reference samples, such as Trotter and Gleser's (1958) Mongoloids is inappropriate.

Our results support previous osteological evidence that coastal populations are skeletally robust. The robusticity is apparent in shafts and articular surfaces of long bones and in the midfacial region of the cranium. It is unlikely that Karankawa skeletal robusticity has a unitary cause. Despite considerable research into postcranial robusticity, it still is not clear how it should be interpreted. It seems likely that the Karankawa were a mobile population. Size and shape of the femur midshaft has been put forth as an indication of mobility (Larsen 1997), but hunters and gatherers do not necessarily exhibit robust postcranial skeletons (Collier 1989). Midfacial robusticity, likely not to be a product of function, suggests that at least certain components of Karankawa robusticity are genetic in origin.

Evidence of Intermarrying

Our assumption at the outset was that the Refugio sample was heterogeneous, consisting of Native, European derived, and mixed ancestry. This composition is reflected in our ancestry assignments made on the basis of morphological assessments. The only opportunity for quantitative investigation of issues relating to ancestry and admixture is in dental metrics and dental morphology. Analysis of dental metrics clearly shows that the overall pattern of the Refugio

sample is Native American. Formal classification of all individuals with dental morphology yields 23 percent European origin, 68 percent Native, and nine percent admixed. These assessments involve some arbitrary decisions about posterior probabilities. A more liberal interpretation of intermediate probabilities would increase the number of admixed at the expense of the “pure” categories.

Seasonal Use of the Mission

Ricklis (1996) observes that the Karankawa utilized the mission as a seasonal resource. The demographic analysis revealed a mortality pattern reflecting group movements likely related to yearly variations in subsistence resources. Oral health also supports more of a hunting and gathering subsistence rather than a maize dependent subsistence. The low frequency of dental caries and low antemortem tooth loss are more often seen in hunting and gathering populations such as that seen in the Morhiss and Ernest Witte sites.

The isotope data provide the most convincing osteological evidence that at least some of the population buried at the mission were seasonal users, while others were apparently permanent residents. We have argued that permanent residents have a more ^{13}C -enriched diet due to more maize consumption, while the seasonal residents have higher marine diets and are less ^{13}C enriched. These diet groups crosscut ethnic assignments, except that all individuals we identified as European are in the permanent resident group. Native Americans and those of mixed ancestry are found in both seasonal and permanent resident groups.

In conclusion, the population of the Refugio mission was a relatively healthy group that experienced low stress or physical hardships. The primary risk to those individuals of the mission was violent in nature. Physically, the group was not exceptionally tall as had been reported earlier, however, they were robust. Because of the lack of intact crania, little can be said regarding the reports of cultural modification to the head. Further comparison of the osteological and dental data from the Refugio mission with other Texas coast groups may shed light on some of these unanswered questions. Further comparison of the isotopic data of this population with other Texas groups would also address questions raised in this study.

References Cited

Aufderheide, A. C., and C. Rodriguez-Martin

- 1998 *The Cambridge Encyclopedia of Human Paleopathology*. Cambridge University Press, Cambridge.

Bass, W. M.

- 1987 *Human Osteology. A Laboratory and Field Manual*. Missouri Archaeological Society, Columbia, Missouri.
1995 *Human Osteology: A Laboratory and Field Manual*. 4th edition. Missouri Archaeological Society, Columbia, Missouri.

Black, T. K.

- 1979 The Biological and Social Analyses of a Mississippian Cemetery from Southeast Missouri: The Turner Site, 23 Bu 21A. *Anthropological Papers*, No. 68. Museum of Anthropology, University of Michigan, Ann Arbor.

Bocquet-Appel, J. P., and C. Masset

- 1977 Estimateurs en Paleodemographie. *L'Homme* 17:65-70.

Bridges, P. A.

- 1995 Skeletal Biology and Behavior in Ancient Humans. *Evolutionary Anthropology* 4:112-120.

Brooks, S. T.

- 1955 Skeletal Age of Death: Reliability of Cranial and Pubic Age Indicators. *American Journal of Physical Anthropology* 13:567-597.

Brooks, S. T., and J. M. Suchey

- 1990 Skeletal Age Determination Based on the Os Pubis: A Comparison of the Acsadi-Nemeskeri. *Human Evolution* 5:227-238.

Brothwell, D. R.

- 1972 *Digging up Bones*. Trustees of the British Museum, London, England.

Brues, A. M.

- 1990 The Once and Future Diagnosis of Race. In *Skeletal Attribution of Race*, edited by G. W. Gill and J. S. Rhine, pp. 1-7. *Anthropological Papers*, No. 4, Maxwell Museum of Anthropology, Albuquerque, New Mexico.

Buikstra, J. E., and L. W. Konigsberg

- 1985 Paleodemography: Critiques and Controversies. *American Anthropologist* 87:316-333.

Buikstra, J. E., and D. H. Ubelaker (editors)

- 1994 *Standards for Data Collection from Human Skeletal Remains*. Research Series, No. 44. Arkansas Archeological Survey, Fayetteville, Arkansas.

Burr, D. B., and B. Martin

- 1989 Errors in Bone Remodeling: Toward a Unified Theory of Metabolic Bone Disease. *American Journal of Anatomy* 186:186-216.

Cargill, D. A., and R. J. Hard

- 1999 Assessing Native American Mobility versus Permanency at Mission San Juan Capistrano through the Use of Stable Isotope Analysis. *Bulletin of the Texas Archeological Society* 70:197-213.

Cervantes, C. D., F. Lefshitz, and J. Levenbrow

- 1988 Radiologic Anthropometry of the Hand in Patients with Familial Short Stature. *Pediatric Radiology* 18(3):210-214.

Chapman, F. H.

- 1972 Vertebral Osteophytes in Prehistoric Populations of Central and Southern Mexico. *American Journal of Physical Anthropology* 36:31-38.

Cole, T. M.

- 1994 Size and Shape of the Femur and Tibia in Northern Plains Indians. In *Skeletal Biology in the Great Plains: Migration, Warfare, Health and Subsistence*, edited by D. W. Owsley and R. L. Jantz, pp. 219-233. Smithsonian Institution Press, Washington, D.C.

Collier, S.

- 1989 The Influence of Economic Behaviour and Environment upon robusticity of the Post-cranial skeleton: A Comparison of Australian Aborigines and other Populations. *Archaeology in Oceania* 14:17-30.

Comuzzie, A. G.

- 1987 The Bioarchaeology of Blue Bayou: A Late Prehistoric Mortuary Site from Victoria County, Texas. Unpublished Master's thesis, Department of Anthropology, Texas A&M University, College Station.

Comuzzie, A. G., M. Marek, and D. G. Steele

- 1984 Analysis of Human Skeletal Remains from the Palm Harbor Site (41AS80), a Mortuary Site on the Central Gulf Coast of Texas. *Bulletin of Texas Archeological Society* 55:213-249.

Dihlmann, W.

- 1985 *Joints and Vertebral Connections in Clinical Radiology*. Thieme, New York.

Dockall, H. M.

- 1997 Archaic Hunter-Gatherer Adaptation on the Inland Portion of the West Gulf Coastal Plain: The Bioarchaeological Evidence. Unpublished Ph.D. dissertation, Department of Anthropology, Texas A&M University, College Station.

Doran, G. H.

- 1975 The Long Bones of Texas Indians. Unpublished Master's thesis, Department of Anthropology, The University of Texas at Austin.

Duetsch, E., E. Pe'er, and I. Gedalia

- 1984 Changes in Size, Morphology, and Weight of Human Anterior Teeth during the Fetal Period. *Growth* 48:74-85.

Dutour, O.

- 1986 Enthesopathies (lesions of muscular insertions) as Indicators of the Activities of Neolithic Saharan Populations. *American Journal of Physical Anthropology* 71:221-224.

Edwards, J. H.

- 1961 The Recognition and Estimation of Cyclical Trends. *Annals of Human Genetics* 25:83-86.

El-Najjar, M., M. V. DeSanti, and L. Ozebek

- 1978 Prevalence and Possibly Etiology of Dental Enamel Hypoplasias within the Human Permanent Dentition. *American Journal of Physical Anthropology* 68:185-192.

Ericson, J. E., M. West, C. H. Sullivan, and H. W. Krueger

- 1989 The Development of Maize Agriculture in the Viru Valley, Peru. In *The Chemistry of Prehistoric Human Bone*, edited by T. D. Price, pp. 68-104. Cambridge University Press, Cambridge.

Faulhaber, J.

- 1970 Anthropometry of Living Indians. In *Handbook of Middle American Indians*, vol. 9, edited by R. Wauchope and T. D. Stewart, pp. 82-104. University of Texas Press, Austin.

Fazekas, G., and F. Kosa

- 1978 *Forensic Fetal Osteology*. Akademiai Kiado, Budapest.

Fraley, C., and A. Raftery

- 1998 *How Many Clusters? Which Clustering Method? Answers via Model-Based Cluster Analysis*. Technical Report No. 329. University of Washington Department of Statistics, Seattle.
- 1999 *MCLUST: Software for Model-based Cluster and Discriminant Analysis*. Technical Report No. 342. University of Washington Department of Statistics, Seattle.

France, D. L.

- 1998 Observational and Metric Analysis of Sex in the Skeleton. In *Forensic Osteology*, edited by K. J. Reichs, pp. 163-186. 2nd edition. Charles C. Thomas, Springfield, Illinois.

Francis, J. R.

- 1999 Temporal Trends in Mission Populations: A Comparison of Pathological Frequencies and Long Bone Length at Mission San Juan Capistrano, San Antonio, Texas. Unpublished Master's thesis, The University of Texas at San Antonio.

Galloway, A. (editor)

- 1999 *Broken Bones: Anthropological Analysis of Blunt Force Trauma*. Charles C. Thomas, Springfield, Illinois.

Gatschet, A. S.

- 1891 The Karankawa Indians, The Coast People of Texas. *Archaeological and Ethnological Papers of the Peabody Museum*, Vol. 1, No.2, Cambridge.

Genoves, S.

- 1967 Proportionality of the Long Bones and their Relation to Stature among Mesoamericans. *American Journal of Physical Anthropology* 26:67-78.

Gerry, J. P., and H. W. Krueger

- 1997 Regional Diversity in Classic Maya Diets. In *Bones of the Maya. Studies of Ancient Skeletons*, edited by S. L. Whittington and D. M. Reed, pp. 196-207. Smithsonian Institution Press, Washington, D.C.

Gilbert, B. M., and T. W. McKern

- 1973 A Method for Aging the Female Os Pubis. *American Journal of Physical Anthropology* 38:31-38.

Gill, G. W.

- 1984 A Forensic Test Case for a New Method of Geographical Race Determination. In *Human Identification: Case Studies in Forensic Anthropology*, edited by T. A. Rathbun and J. E. Buikstra, pp. 329-399. Charles C. Thomas, Springfield, Illinois.
- 1995 Challenge on the Frontier: Discerning American Indians from Whites Osteologically. *Journal of Forensic Sciences* 40:783-788.
- 1998 Craniofacial Criteria in the Skeletal Attribution of Race. In *Forensic Osteology*, edited by K. J. Reichs, pp. 293-318. 2nd edition. Charles C. Thomas, Springfield, Illinois.

Gill, G. W., and B. M. Gilbert

- 1990 Race Identification from the Midfacial Skeleton: American Blacks and Whites. In *Skeletal Attribution of Race*, edited by G. W. Gill and S. Rhine, pp. 47-53. Anthropological Papers, No. 4. Maxwell Museum of Anthropology, Albuquerque, New Mexico.

Gill, G. W., and J. S. Rhine

- 1986 *Skeletal Race Identification: New Approaches in Forensic Anthropology*. Maxwell Museum, Albuquerque, New Mexico.

Goodman, A. H., and G. Armelagos

- 1985 Factors Affecting the Distribution of Enamel Hypoplasias within the Human Permanent Dentition. *American Journal of Physical Anthropology* 68:479-493.

Goodman, A. H., and J. C. Rose

- 1990 Assessment of Systematic Physiological Perturbations from Dental Enamel Hypoplasias and Associated Histological Structures. *Yearbook of Physical Anthropology* 33:55-110.

Guatelli-Steinburg, D., and J. R. Lukacs

- 1999 Interpreting Sex Differences in Enamel Hypoplasia in Human and Non-human Primates: Developmental, Environmental, and Cultural Considerations. *American Journal of Physical Anthropology* 110:73-126.

Hanihara, T.

- 1998 Metric and Nonmetric Dental Variations of Major Human Populations. In *Human Dental Development, Morphology, and Pathology*, edited by J. R. Lukacs, pp. 173-200. Anthropological Papers, No. 54. University of Oregon, Eugene.

Hattori, K., N. Numata, M. Ikoma, A. Matsuzaka, and R. R. Danielson

- 1991 Sex Differences in the Distribution of Subcutaneous and Internal Fat. *Human Biology* 63:53-63.

Herskovits, M. J.

- 1969 *Anthropometry of the American Negro*. AMS Press, New York.

Hillson, S.

- 1996 *Dental Anthropology*. Cambridge University Press, Cambridge.

Hillson, S., C. Grigson, and S. Bond

- 1998 Dental Defects Congenital Syphilis. *American Journal of Physical Anthropology* 107:25-40.

Holliday, T. W.

- 1997 Body Proportions in Late Pleistocene Europe and Modern Human Origins. *Journal of Human Evolution* 32:423-448.
- 1999 Brachial and Crural Indices of European Late Upper Paleolithic and Mesolithic Humans. *Journal of Human Evolution* 36:549-566.

Holman, D. J.

- 2000 MLE: A Programming Language for Building Likelihood Models. Version 2.
<<http://faculty.washington.edu/~holman/mle>>

Howells, W. W.

- 1973 *Cranial Variation in Man*. Papers of the Peabody Museum of Archaeology and Ethnology, No. 67, Harvard University, Cambridge, Massachusetts.

Hrdlicka, A.

- 1970 *The Old Americans: A Physiological Profile*. Arno Press, New York.

Huebner, J. A.

- 1991 Cactus for Dinner, Again! An Isotopic Analysis of Late Archaic Diets in the Lower Pecos Region of Texas. In *Papers on Lower Pecos Prehistory*, edited by S. A. Turpin, pp. 175-190. Texas Archeological Research Laboratory, The University of Texas, Austin.

Humphreys, S. B.

- 1971 The Skeletal Biology of Eighteenth Century Coahuiltecan Indians from San Juan Capistrano Mission, San Antonio, Texas. Unpublished Master's thesis, Department of Anthropology, Southern Methodist University, Dallas.

Iscan, M. Y., S. R. Loth, and R. K. Wright

- 1984 Age Estimation from the Rib by Phase Analysis: White Males. *Journal of Forensic Sciences* 29:1094-1104.

Jacobi, K. P.

- 1994 An Analysis of Genetic Structuring in a Colonial Maya Cemetery, Tipu, Belize, Using Dental Morphology and Metrics. *American Journal of Physical Anthropology* Supplement 18:114.
- 1996 An Analysis of Genetic Structure in a Colonial Maya Cemetery, Tipu Belize. Unpublished Ph.D. dissertation, Indiana University, Bloomington.

Jacobi, K. P., D. Collins Cook, R. S. Corruccini, and J. S. Handler

- 1992 Congenital Syphilis in the Past: Slaves at Newton Plantation, Barbados, West Indies. *American Journal of Physical Anthropology* 89:145-158.

Jantz, R. L.

- 1995 Franz Boas and Native American Biological Variability. *Human Biology* 67:345-353.

Jantz, R. L., and D. W. Owsley

- 1994 Growth and Dental Development in Arikara Children. In *Skeletal Biology in the Great Plains: Migration, Warfare, Health and Subsistence*, edited by D. W. Owsley and R. L. Jantz, pp. 247-258. Smithsonian Institution Press, Washington, D.C.
- 2001 Variation among early North American Crania. *American Journal of Physical Anthropology* 114.

Jantz, R. L., D. R. Hunt, A. B. Falsetti, and P. J. Key

- 1992 Variation among North Amerindians: Analysis of Boas' Anthropometric Data. *Human Biology* 64:435-461.

Johnston, F. E., and L. M. Schell

- 1979 Anthropometric Variation in Native American Children and Adults. In *The First Americans: Origins, Affinities, and Adaptations*, edited by W. S. Laughlin and A. B. Harper, pp. 275-292. Gustav Fischer, New York.

Jurmain, R. D.

- 1975 Distribution of degenerative Joint Disease in Skeletal Populations. Unpublished Ph.D. dissertation, Harvard University, Cambridge, Massachusetts.

Kelley, M. A., D. R. Levesque, and E. Weidl

- 1991 Contrasting Patterns of Dental Disease in Five Early Northern Chilean Groups. In *Advances in Dental Anthropology*, edited by M. A. Kelley and C. S. Larsen, pp. 203-213. Wiley-Liss, New York.

Key, P. J.

- 1983 *Cranimetric Relationships among Plains Indians*. Report of Investigations, No. 34. Department of Anthropology, The University of Tennessee, Knoxville.

Kieser, J. A.

- 1990 *Human Adult Odontometrics*. Cambridge University Press, Cambridge.

Konigsberg, L. W., J. E. Buikstra, and J. Bullington

- 1989 Paleodemographic Correlates of Fertility. *American Antiquity* 54:626-636.

Krogman, W. M., and M. Y. Iscan

- 1986 *The Human Skeleton in Forensic Medicine*. 2nd edition. Charles C. Thomas, Springfield, Illinois.

Krueger, H. W.

- 1985 Models for carbon and Nitrogen Isotopes in Bone. Poster presented at Biomineralization Conference, Airlie House, Warrenton, Virginia.

Lahr, M. M.

- 1996 *The Evolution of Modern Human Diversity*. Cambridge University Press, New York.

Larsen, C. S.

- 1997 *Bioarchaeology: Interpreting Behavior from the Human Skeleton*. Cambridge University Press, New York.

Larsen, C. S., C. B. Ruff, M. J. Schoeninger, and D. L. Hutchinson

- 1992 Population Decline and Extinction in La Florida. In *Disease and Demography in the Americas: Changing Patterns Before and After 1492*, edited by J. W. Verano and D. H. Ubelaker, pp. 41-67. Smithsonian Institution Press, Washington, D.C.

Lester, C. W., and H. L. Shapiro

- 1968 Lumbar Vertebrae of Pre-historic American Eskimos: A Study of Skeletons in the American Museum of Natural History, Chiefly from Point Hope, Alaska. *American Journal of Physical Anthropology* 28:43.

- Lovejoy, C. O., R. S. Meindl, T. R. Pryzbeck, and R. P. Mensforth
1985 Chronological Metamorphosis of the Auricular Surface of the Ilium: A New Method for the Determination of Adult Skeletal Age at Death. *American Journal of Physical Anthropology* 68:47-56.
- Lovejoy, C. O., K. F. Russell, and M. L. Harrison
1990 Long Bone Growth Velocity in the Libben Population. *American Journal of Human Biology* 2:533-541.
- Mann, R. W., and S. P. Murphy
1990 *Regional Atlas of Bone Disease: A Guide to Pathologic and Normal Variation in the Human Skeleton*. Charles C. Thomas, Springfield, Illinois.
- Mann, R. W., S. A. Symes, and W. M. Bass
1987 Maxillary Suture Obliteration: Aging the Human Skeleton Based on Intact or Fragmentary Maxilla. *Journal of Forensic Sciences* 32:148-157.
- Marrero, O.
1983 The Performance of Several Statistical Tests for Seasonality in Monthly Data. *Journal of Statistical Computer Simulation* 17(4):275-296.
- McKern, T. W., and T. D. Stewart
1957 Skeletal Changes in Young American Males, Technical Report EP-45. Headquarters, Quartermaster Research and Development Command, Natick, Massachusetts.
- Meadows, L., and R. L. Jantz
1995 Allometric Secular Change in the Long Bones from the 1800s to the Present. *Journal of Forensic Sciences* 40:762-767.
- Meadows Jantz, L., K. Schneider, S. A. Novak, and W. F. McCormick
1999 Trauma Patterns in the William M. Bass Donated Skeletal Collection, Poster presented at the American Academy of Forensic Sciences meeting, February, 1999.
- Meindl, R. S., and C. O. Lovejoy
1985 Ectocranial Suture Closure: A Revised Method for the Determination of Skeletal Age at Death Based on the Lateral-Anterior Sutures. *American Journal of Physical Anthropology* 68:57-66.
- Meindl, R. S., C. O. Lovejoy, R. P. Mensforth, and R. A. Walker
1985 A Revised Method of Age Determination Using the Os Pubis, with a Review and Tests of Accuracy of other Current Methods of Pubic Symphyseal Aging. *American Journal of Physical Anthropology* 68:29-46.
- Merbs, C. F.
1996 Spondylolysis of the Sacrum in Alaskan and Canadian Inuit Skeletons. *American Journal of Physical Anthropology* 101(3):357-367.
- Merchant, V. L., and D. H. Ubelaker
1977 Skeletal Growth of the Protohistoric Arikara. *American Journal of Physical Anthropology* 46:61-72.
- Moorrees, C. F. A., E. A. Fanning, and E. E. Hunt
1963a Age Variation of Formation Stages for Ten Permanent Teeth. *Journal of Dental Research* 42:1490-1502.

- 1963b Formation and Resorption of Three Deciduous Teeth in Children. *American Journal of Physical Anthropology* 21:205-213.
- Morse, D.
1969 *Ancient Disease in the Midwest*. Illinois State Museum Reports of Investigations, No. 15.
- Nelson, C. T.
1938 The Teeth of the Indians of Pecos Pueblo. *American Journal of Physical Anthropology* 23:261-293.
- Newcomb, W. W.
1961 *The Indians of Texas: From Prehistoric to Modern Times*. University of Texas Press, Austin.
- Norgan, N. G.
1994 Relative Sitting Height and the Interpretation of the Body Mass Index. *Annals of Human Biology* 21:79-82.
- Norgan, N. G., and P. R. Jones
1995 The Effect of Standardizing the Body Mass Index for Relative Sitting Height. *International Journal of Obesity and Related Metabolic Disorders* 19:206-208.
- Novak, S. A.
1998 Domestic Assault: Soft Tissue and Skeletal Manifestations. *American Journal of Physical Anthropology* Supplement 26.
1999 Skeletal Manifestation of Domestic Assault: A Predictive Model for Investigating Gender Violence in Prehistory. Unpublished Ph.D. dissertation. University of Utah, Salt Lake City.
- Oberste, W. H.
1942 *History of Refugio Mission*. Refugio Timely Remarks, Refugio, Texas.
- O'Rourke, D. H., and M. H. Crawford
1980 Odontometric Microdifferentiation of Transplanted Mexican Indian Populations: Cuanalan and Saltillo. *American Journal of Physical Anthropology* 52(3):421-434.
- Ortner, D. J.
1968 Description and Classification of Degenerative Bone Changes in the Distal Joint Surfaces of the Humerus. *American Journal of Physical Anthropology* 28:139-156.
- Ortner, D. J., and J. G. Putschar
1985 *Identification of Pathological Conditions in Human Skeletal Remains*. Smithsonian Contributions to Anthropology, No. 28. Smithsonian Institution Press, Washington, D.C.
- Owsley, S. D., and R. L. Jantz
1997 The Forensic Data Bank: Documenting Skeletal Trends in the United States. In *Forensic Osteology*, edited by K. J. Reichs, pp. 441-458. 2nd edition. Charles C. Thomas, Springfield, Illinois.
- Owsley, D. W.
1982 Dental Discriminant Sexing of Arikara Skeletons. *Plains Anthropologist* 27:165-169.
1994 Warfare in Coalescent Tradition Populations of the Northern Plains. In *Skeletal Biology of the Great Plains: Migration, Warfare, Health, and Subsistence*, edited by D. W. Owsley and R. L. Jantz, pp. 333-343. Smithsonian Institution Press, Washington, D.C.

Owsley, D. W., and R. L. Jantz

- 1983 Formation of the Permanent Dentition in Arikara Indians: Timing Differences that Affect Dental Age Assessments. *American Journal of Physical Anthropology* 61:467-471.
- 1985 Long Bone Lengths and Gestational Age Distributions of Postcontact Period Arikara Perinatal Infant Skeletons. *American Journal of Physical Anthropology* 68:321-328.
- 1989 *A Systematic Approach to the Skeletal Biology of the Southern Plains, From Clovis to Comanchero: Archeological Overview of the Southern Great Plains*. Research Series, No. 35. Arkansas Archeological Survey, Fayetteville.

Owsley, D., R. Jantz, S. Novak, D. Kollmann, and J. Francis

- 1999 Documentation of Human Skeletons from San Juan Capistrano, Technical Report. Manuscript on file, Center for Archaeological Research, The University of Texas at San Antonio.

Palkovich, A. M.

- 1978 A Model of the Dimensions of Mortality and its Application to Paleodemography. Unpublished Ph.D. dissertation, Northwestern University, Evanston, Illinois.

Perzigian, A. J.

- 1976 The Dentition of the Indian Knoll Skeletal Population: Odontometrics and Cusp Number. *American Journal of Physical Anthropology* 44(1):113-121.

Phenice, T. W.

- 1969 A Newly Developed Visual Method of Sexing the Os Pubis. *American Journal of Physical Anthropology* 30:297-301.

Pindborg, J. J.

- 1970 *Pathology of the Dental Hard Tissues*. W. B. Saunders, Philadelphia.

Powell, J. F.

- 1994 Bioarchaeological Analyses of Human Skeletal Remains from the Mitchell Ridge Site. In *Aboriginal Life and Culture on the Upper Texas Coast: Archaeology at the Mitchell Ridge Site, 41GV66, Galveston Island*, edited by R. A. Ricklis, p. 287. Coastal Archaeological Research, Corpus Christi, Texas.

Redfield, A.

- 1970 A New Aid to Aging Immature Skeletons: Development of the Occipital Bone. *American Journal of Physical Anthropology* 33:207-220.

Regan, M. H., D. T. Case, and J. C. Brundige

- 1999 Articular Surface Defects in the Third Metatarsal and Third Cuneiform: Nonosseous Tarsal Coalition. *American Journal of Physical Anthropology* 109:53-65.

Reijneveld, S. A.

- 1990 The Choice of a Statistic For Testing Hypotheses Regarding Seasonality. *American Journal of Physical Anthropology* 83(2):181-184.

Resnick, D., and G. Niwayama

- 1981 *Diagnosis of Bone and Joint Disorders*, vol. 3. W. B. Saunders, Philadelphia.

Rhine, S.

- 1990 Non-Metric Skull Racing. In *Skeletal Attributions of Race*, edited by G. W. Gill and S. Rhine, pp. 9-20. Anthropological Papers, No. 4. Maxwell Museum of Anthropology, Albuquerque, New Mexico.

Ricklis, R. A.

- 1996 *The Karankawa Indians of Texas: An Ecological Study of Cultural Tradition and Change*. University of Texas Press, Austin.

Roberts, C., and K. Manchester

- 1995 *The Archaeology of Disease*. 2nd edition. Cornell University Press, New York.

Rose, J. C.

- 1999 *Bioarchaeology of the South Central United States*. Research Series, No. 55. Arkansas Archeological Survey, Fayetteville.

Ruff, C.

- 1987 Sexual Dimorphism in Human Lower Limb Bone Structure: Relationship to Subsistence Strategy and Sexual Division of Labor. *Journal of Human Evolution* 16:391-416.
- 1994 Biomechanical Analysis of Northern and Southern Plains Femora: Behavioral Implications. In *Skeletal Biology in the Great Plains: Migration, Warfare, Health and Subsistence*, edited by D. W. Owsley and R. L. Jantz, pp. 235-245. Smithsonian Institution Press, Washington, D.C.

Ruff, C. B.

- 2000 Biomechanical Analyses of Archaeological Human Skeletons. In *Biological Anthropology of the Human Skeleton*, edited by M. A. Katzenberg and S. R. Saunders, pp. 71-102. Wiley-Liss, New York.

Ruff, C. B., W. W. Scott, and A. Y. C. Liu

- 1991 Articular and Diaphyseal Remodeling of the Proximal Femur with Changes in Body-mass in Adults. *American Journal of Physical Anthropology* 86:397-413.

St. Leger, A. S.

- 1976 Comparison of Two Tests for Seasonality in Epidemiological Data. *Applied Statistics* 25(3):280-286.

Satterthwaite, F. W.

- 1946 An Approximate Distribution of Estimates of Variance Components. *Biometrics Bulletin* 2:110-114.

Saunders, S.

- 1993 Growth Deficit in Survivors and Non-survivors: Biological Mortality Bias in Subadult Skeletal Samples. *Yearbook of Physical Anthropology* 36:127-151.

Scheuer, J. L., J. H. Musgrave, and S. P. Evans

- 1980 The Estimation of Late Fetal and Perinatal Age from Limb Bone Length by Linear and Logarithmic Regression. *Annals of Human Biology* 7:257-265.

Schuetz, M. K.

- 1980 A Historical Outline of Mission San Juan de Capistrano. *La Tierra: Quarterly Journal of the Southern Texas Archaeological Association* 7.

Sciulli, P. W.

- 1979 Size and Morphology of the Permanent Dentition in Prehistoric Ohio Valley Amerindians. *American Journal of Physical Anthropology* 50:615-628.

Sciulli, P. W., and M. J. Giesen

- 1993 Brief Communication: An Update on Stature Estimation in Prehistoric Native Americans of Ohio. *American Journal of Physical Anthropology* 92:395-399.

Sciulli, P. W., K. N. Schneider, and M. C. Mahaney

- 1990 Stature Estimation in Prehistoric Native Americans of Ohio. *American Journal of Physical Anthropology* 83:275-280.

Scott, G. R., and C. G. Turner

- 1997 *The Anthropology of Modern Human Teeth: Dental Morphology and Its Variation in Recent Human Populations*. Cambridge University Press, Cambridge.

Seinsheimer, F.

- 1978 Subtrochanteric Fractures of the Femur. *Journal of Bone and Joint Surgery* 60:300-306.

Slaus, M.

- 2000 Biocultural Analysis of Sex Differences in Mortality Profiles and Stress Levels in the Late Medieval Population from Nova Raca, Croatia. *American Journal of Physical Anthropology* 111:193-209.

Smith, B. H.

- 1984 Patterns of Molar Wear in Hunter-Gatherers and Agriculturalists. *American Journal of Physical Anthropology* 63:39-56.

Smith, M. O.

- 1983 Patterns of Association Between Oral Health Status and Subsistence: A Study of Aboriginal Skeletal Populations from the Tennessee Valley Area. Unpublished Ph.D. dissertation, University of Tennessee, Knoxville.

Sorensen, M. V., and W. R. Leonard

- 2001 Neandertal Energetics and Foraging Efficiency. *Journal of Human Evolution* 40:483-495.

Steele, D. G.

- 1970 Estimation of Stature from Fragments of Long Limb Bones. In *Personal Identification in Mass Disasters*, edited by T. D. Stewart. Smithsonian Institution Press, Washington, D.C.

Steele, D. G., B. W. Olive, and K. J. Reinhard

- 1999 Central, South and Lower Pecos Texas. In *Bioarcheology of the South Central United States*, edited by J. C. Rose, pp. 133-152. Research Series, No. 55. Arkansas Archeological Survey, Fayetteville.

Steinbock, R. T.

- 1976 *Paleopathological Diagnosis and Interpretation: Bone Diseases in Ancient Human Populations*. Charles C. Thomas, Springfield, Illinois.

Stewart, T. D.

- 1956 Examination of the Possibility that Certain Skeletal Characters Predispose to Defects in the Lumbar Neural Arches. *Clinical Orthopaedics and Related Research* 8:44.
- 1970 Identification of the Scars of Parturition in the Skeletal Remains of Females. In *Personal Identification in Mass Disasters*, edited by T. D. Stewart. Smithsonian Institution Press, Washington, D.C.
- 1979 *Essentials of Forensic Anthropology*. Charles C. Thomas, Springfield, Illinois.

Storey, R.

- 1997 Individual Frailty, Children of Privilege, and Stress in Late Classic Copan. In *Bones of the Maya*, edited by S. L. Whittington and D. M. Reed, pp. 116-126. Smithsonian Institution Press, Washington, D.C.

Stuart-Macadam, P.

- 1985 Porotic Hyperostosis: Representative of Childhood Condition. *American Journal of Physical Anthropology* 80:187.

Suchey, J. M., and D. Katz

- 1998 Applications of Pubic Age Determination in a Forensic Setting. In *Forensic Osteology*, edited by K. J. Reichs, pp. 204-236. 2nd edition. Charles C. Thomas, Springfield, Illinois.

Takayuki, M., T. Shuhei, and R. Nakamura

- 1986 Brachymetacarpia and Brachyphalangia. *The Journal of Hand Surgery* 11:829-836.

Tanner, J. M.

- 1978 *Foetus into Man*. Harvard University Press, Cambridge, Massachusetts.

Trotter, M., and G. C. Gleser

- 1952 Estimation of Stature from Long Bones of American Whites and Negroes. *American Journal of Physical Anthropology* 10:463-514.
- 1958 A Re-evaluation of Estimation of Stature Taken During Life and of Long Bones After Death. *American Journal of Physical Anthropology* 16:79-123.

Turner, C. G., C. R. Nichol, and G. R. Scott

- 1991 Scoring Procedures for Key Morphological Traits of the Permanent Dentition: The Arizona State University Dental Anthropology System. In *Advances in Dental Anthropology*, edited by M. A. Kelley and C. S. Larsen, pp. 13-31. Wiley-Liss, New York.

Ubelaker, D. H.

- 1978 *Human Skeletal Remains: Excavation, Analysis, Interpretation*. Aldine Manuals on Archeology, Chicago, IL.
- 1989 *Human Skeletal Remains: Excavation, Analysis, Interpretation*. 2nd edition. Taraxacum, Washington, D.C.

Walker, R. A., and C. O. Lovejoy

- 1985 Radiographic Changes in the Clavicle and Proximal Femur and Their Use in the Determination of Skeletal Age at Death. *American Journal of Physical Anthropology* 68:67-78.

Weaver, D. S.

- 1979 Application of the Likelihood Ratio Test to Age Estimation Using the Infant and Child Temporal Bone. *American Journal of Physical Anthropology* 50:263-270.

Wilkinson, R. G.

- 1977 Osteological Evidence for the Identification of Pre-Contact Karankawa. In *Anthropological Papers, Museum of Anthropology, University of Michigan, No. 61*, edited by C. E. Cleland, pp. 40-54. University of Michigan Press, Ann Arbor.

Willey, P.

- 1990 *Prehistoric Warfare on the Great Plains: Skeletal Analysis of the Crow Creek Massacre*. Garland Publishing, New York.

Wood, J. W., G. R. Milner, H. C. Harpending, and K. M. Weiss

- 1992 The Osteological Paradox. *Current Anthropology* 33:343-370.

Woodbury, G., and E. Woodbury

- 1935 *Prehistoric Skeletal Remains from the Texas Coast*. Lancaster Press, Lancaster, Pennsylvania.

Wright, L. E.

- 1997 Intertooth Patterns of Hypoplasia Expression: Implications for Childhood Health in the Classic Maya Collapse. *American Journal of Physical Anthropology* 102(2):223-247.

Volume II
Osteological Analyses

Mission Refugio

Appendix IIA
Burial Descriptions

Osteological Analyses

Appendix II A

Burial Descriptions

Lee Meadows Jantz, Nicholas P. Herrmann, and Corey S. Sparks

Guest appearances by Douglas Owsley, Derinna Kopp, and Katherine Weisensee (joined in August 2000)

Burial Feature 02

41RF1-BP02-006

This individual is a female aged 35-44 years (code 24) of Hispanic ancestry, represented by a mostly complete but fragmentary skeleton. This was a secondary burial that was previously disturbed. Evidence of postmortem damage is present in the form of cuts and fractures. Examples of postmortem cuts are located on the frontal, a few ribs, and left distal radius. These are determined to be postmortem yet not fresh (from recent excavation) by the lack of radiating fractures and staining. The cortical surface of the bone also shows taphonomic changes from root etchings. The bone is light to medium orange-brown in color.

Age

Age is estimated based on the morphology of the sternal rib ends, slight arthritic changes of most joints, and open cranial suture closure. The ribs are consistent with a Phase 5, which suggests an age range of 33 to 46 years.

Ancestry

The nasal morphology shows a slight nasal sill and slight development of the nasal spine. The zygomaxillary sutures exhibit slight recurvature. The central incisor is moderately shovel-shaped. The femora are round.

Sex

The sex of this individual was estimated based on the overall size of the postcranial skeleton and the gracile nature of the supraorbital region. The mandible is moderately robust.

Dentition

Much of the dentition is present. There is no evidence of antemortem tooth loss although seven teeth have been lost postmortem. Calculus deposits range from moderate to three-dimensional. Carious lesions are present interproximally on the distal surface of the right maxillary second molar, and the right distal mandibular second incisor and first molar. The left central maxillary incisor, although missing postmortem, has a periapical abscess. The mandibular third molars have small periodontal abscesses on their lingual alveolar margins.

Enamel chipping is present on several teeth. The teeth affected include the distal surface of the upper right third molar, the mesial-occlusal surface of the upper right first molar, the distal-buccal surface of the upper right canine, the mesial-buccal surface of the upper first left premolar, the mesial-lingual surface of the lower first left molar, and the mesial-lingual surface of the lower right first molar.

Interproximal grooving is present on the following maxillary teeth: mesial surface of the right third molar, the bucco-distal surface of the right second molar, the distal surfaces of the left premolars, the bucco-distal surface of the second molar, the mesial lingual surface of the third molar. The distal surfaces of all the mandibular premolars exhibit interproximal grooving.

The maxillary incisors and associated alveolar bone show damage from an antemortem injury that was remodeling at the time of death. The left central incisor is missing postmortem, but was actively abscessing. The root of the right central incisor has a fracture in its apical third. The tip of this root is retained in the socket by encompassing bone. The crown and cervical half of the root were also recovered, and in life would have been held in place by the gums and surrounding alveolus. Mobility along the fracture smoothed and polished the fracture surface, which resembles a pseudoarthrosis in a bone fracture that fails to reunite. The crown and cervical half of the left lateral incisor is missing postmortem, as evidenced by a well-defined alveolar socket. However, this tooth was similarly fractured and the apical portion of its root is present in the alveolus. These changes in the alveolus and root fracturing of at least two anterior teeth are the result of trauma. The left maxilla was scored for antemortem fracturing because of remodeling of the anterior margins of the alveolus.

The apical thirds of the roots of the right maxillary first and second premolars are present in the sockets, but their crowns and much of their roots are missing postmortem. Although the surrounding alveolar bone appears normal, the roots of these teeth may have been fractured with the anterior teeth. It is unusual to see postmortem fracturing of roots deep within the alveolus. This type of breakage more often occurs as a result of trauma.

Small root fragments or dentin nodules are present in the maxilla between first and second premolars bilaterally.

Functional Morphology

The nuchal region is slightly developed. The humeri exhibit moderate development of the attachments for teres major, pectoralis major, and slight development of the attachment of the deltoid. The distal humeri have moderately developed supracondylar ridges. The ulna exhibits slight development of the attachment for pronator quadratus.

The elbows show evidence of habitual tight flexion and hyperextension. The humeri have supracapitular facets from contact with the radial head, and the ulnae show erosion of the coronoid processes. These changes reflect tight flexion of the elbow. Habitual hyperextension is evidenced by lipping and erosion on the olecranon fossae and lateral extension of the articular surface of the olecranon process. The left arm is more affected than the right.

The femora show marked roughening at the gluteal attachments. The linea aspera are also moderately developed. The left linea aspera measures approximately 7.2 mm in diameter and 2.6 mm in height at midshaft. The left tibia exhibits a large squatting facet.

Pathology

The right parietal exhibits a well-healed chop type fracture. This defect has a long medial margin (21 mm) and is approximately 10 mm wide. The middle and lateral portion of the defect appears to be incomplete spalls that have healed. Remodeling has rounded the margins of the wound. No evidence of active infection is present, as the surface texture of this defect is consistent with the surrounding ectocranial surface.

Slight osteoarthritis is present on most of the long bone joint surfaces. Although highly fragmented and poorly represented, the vertebrae exhibit some arthritic changes. The second cervical exhibits slight lipping on the facets, and the first lumbar has slight lipping on the facet margin and slight porosity and eburnation on the joint surface and margins.

The right clavicle exhibits a well-healed incomplete fracture on the lateral portion, and the left clavicle exhibits a well-healed complete fracture on the lateral portion.

The tip of the coronoid process of the left ulna exhibits a well-healed fracture. Galloway (1999) describes this type of fracture as occurring in one of two ways:

1. "Impact along the long axis of the arm may be one mechanism of injury (Scharplatz and Allgower 1976) as the radius is displaced pulling the ulna along with it. The coronoid process will then be driven against the trochlea."
2. "The small protrusion of bone also serves as an attachment site for anterior ligaments of the elbow and so is vulnerable to avulsion. The brachialis muscle provides the mechanism of injury, especially when the elbow is hyperextended. These avulsive fractures form Type I of the Regan and Morrey (1989) classification system for this region of this bone."

41RF1-BP02-015

This individual is a Native American female, aged 60+ (code 29), and is represented by a highly fragmentary skeleton. Preservation is poor, however the hand and foot bones are well represented. This is typical of this series. The bone is an orange-brown in color, and root etchings are prevalent on the cortical surfaces.

Age

The age of this individual is estimated as 60+ years based on several indicators. The auricular surface exhibits areas of micro and macro porosity. This morphology is consistent with a Phase 7 or 8, suggesting an older individual. The cranial sutures are mostly obliterated. Osteoarthritis is evident on most joint surfaces. Osteoporosis is evident in the foot bones, however the long bones do not appear to be affected.

Ancestry

The ancestry of this individual is estimated as Native American. The fragmentary nature of these remains precludes use of the cranium or face for metric analysis. The central incisor has slight shovelings. The proximal femora exhibit moderate platymeria.

Sex

Sex is estimated as female for this individual based on the small and gracile nature of the majority of the elements and the presence of a preauricular sulcus.

Dentition

One nearly complete tooth and five roots represent the dentition of this individual. All of the teeth exhibit pathology. The five roots, representing a maxillary first premolar and first molar, mandibular left canine, and first and second premolars, exhibit complete destruction of the crowns and pulp exposure due to carious lesions. The only crown present is a right central incisor. This tooth also has a large lesion on the interproximal and root region resulting in near loss of the crown. Pulp exposure has resulted from the lesion.

Functional Morphology

The nuchal region of the cranium exhibits slight to moderate development. The hand bones exhibit well-developed ridges resulting from habitual strenuous use.

Pathology

Osteoarthritis is present on most of the joint surfaces. The severity of arthritic changes range from slight to severe. The most marked changes are located on the lumbar vertebrae. The facets of these bones exhibit severe osteophytic lipping and porosity and slight eburnation.

The distal femoral joint surfaces have bilateral osteochondritis dessicans. Both patellae were scored for slight enthesophyte development.

Burial Feature 03

41RF1-BP03-007

From a Sort

This burial is commingled with a minimum of three individuals. However, the primary burial represents the very fragmentary and incomplete remains of an adolescent. Sex and ancestry are indeterminate. The estimate of age as between 12 and 16 years (code 15) is necessarily broad due to the fragmentary nature of the material. A few epiphyseal fragments are present.

The other individuals are not clearly associated with this burial. A cervical vertebra of an infant, a maxillary canine (R $\frac{3}{4}$) representing a 8-10 year old, and hand and wrist bones of an adult are included, but these remains are not considered as discrete individuals and are thus not analyzed.

Burial Feature 04

41RF1-BP04-008

This individual is a male, 22-26 years of age (code 21) of Native American ancestry, represented by a mostly complete yet fragmentary skeleton. The cranium is highly fragmented, and the postcranial skeleton is only slightly less fragmentary. This skeleton represents a very robust and tall individual with well-developed muscle attachments. The bone quality ranges from fair to good, and the bone is a light to medium orange-brown in color.

Age

Age is based on sternal rib end morphology, auricular surface morphology, lack of arthritic changes, union of the medial clavicle, and general bone density. The rib morphology is consistent with Phases 2 and 3. The superior demiface of the left auricular surface is present and exhibits morphology consistent with Phase 5. The cortical bone is smooth and dense. All of these features suggest an age range of 22-26 years.

Ancestry

The ancestry of this individual is estimated as Native American. The fragmentary maxillae exhibit a slight nasal sill with mostly guttering in this region. The incisors are moderately shovel-shaped. The proximal femora are strongly platymeric. Overall, the postcranial skeleton is large. These characteristics suggest Native American ancestry.

Sex

The sex is based on a very large, robust mandible with and the large postcranial size. The mandible exhibits wide and high ascending rami with an approximate 90 degree angle. The gonial angle also shows inversion. The temporal lines are prominently ridged. The humeral and femoral heads measure 49 mm in diameter. The muscle attachment sites on the postcrania are well marked and robust.

Dentition

The dentition of this individual reflects generally good oral health. No caries activity is present. Dental attrition is slight. Calculus deposits range from flecks to three dimensional with the posterior teeth being the least affected.

Enamel chipping is present on the following teeth: the labial surface of the maxillary right canine, the mesio-distal cusp of the maxillary left first molar, the labial distal margin of the mandibular left central incisor, and the occlusal mesial margin of the mandibular right canine.

The right maxillary lateral incisor exhibits a developmental defect in the form of a crease or fold on the enamel and root located on the lingual distal side.

Enamel hypoplasias are present on both of the upper canines. The defects consist of slight horizontal bands across the buccal surface.

Functional Morphology

The left and right humeri exhibit well-developed and robust muscle attachments for the teres major, pectoralis major, and deltoid muscles. These muscle attachments sites exhibit raised broad ridges. The right humerus is more marked than the left humerus indicating a right sided preference. The right humerus exhibits a marked and raised ridge on the proximal posterior third of the shaft for the attachment of the lateral head of the triceps. The supracondylar ridge exhibits slight development. The right ulna shows moderate development of the attachment for pronator quadratus, and the left ulna exhibits slight to moderate development of this muscle.

The femora exhibit marked rugosity in the region of gluteal muscle attachments. The proximal femora exhibit marked platymeria. The linea asperae show marked development especially in the lower middle third of the diaphysis. The linea aspera of the left femur at midshaft measures 8 mm in width and 3 mm in height.

Pathology

The tenth thoracic vertebra has slight porosity on the inferior articulating facets.

The left tibia was scored for a localized healed enthesophyte on the proximal one third medial surface.

41RF1-BP04-012

From a Sort

This is a male aged 50+ (code 28) of indeterminate ancestry. This is a mostly incomplete postcranial skeleton in a fragmentary state. This burial was disturbed and commingled with 41RF1-BP04-018. The extra elements from these commingled burials, 41RF1-BP04-018 and 41RF1-BP04-012, are included with 41RF1-BP04-018.

Age

The age estimate of this individual is based on pubic symphysis and auricular surface morphology. The pubic symphysis is consistent with a Todd Phase 10 (50+), and the auricular surface is consistent with a Phase 7 (50-59). These indicators and the slight arthritic lipping in evidence are consistent with an age estimate of 50+.

Ancestry

Ancestry is indeterminate in this individual. None of the indicators or features are present to suggest an ancestry.

Sex

Sex is estimated based on a narrow pubic bone and a narrow subpubic angle. Both of these characteristics indicate male.

Functional Morphology

The left clavicle exhibits marked development at the attachment for the deltoid muscle.

Pathology

The one vertebral fragment exhibits slight lipping on the centrum. The sacral promontory shows slight porosity. The left and right acetabula were scored for slight lipping.

The distal one third of the shaft of the left ulna exhibits a well-healed fracture.

41RF1-BP04-013

This individual is a female aged 17-20 years (code 20) of Native American ancestry represented by a highly fragmentary mostly complete skeleton. The bones are orange-brown in color and are moderately root etched.

Age

Age is estimated as 17-20 years based on third molar development and epiphyseal fusion. The maxillary third molars exhibit complete root development without formation of the apex. The long bones epiphyses are all fused. The iliac crest has not completed fusion. All of these characteristics indicate a young adult.

Ancestry

Ancestry is estimated based on the presence of a moderately shovel-shaped incisor and large squatting facets on the tibiae. These features are consistent with Native American ancestry.

Sex

Sex estimation is based on the gracile nature of the postcranial elements. The femur head diameter measures 41 mm.

Dentition

Most of the dentition is present. Carious lesions are present on the maxillary first molars and the left mandibular second molar. Flecks to moderate calculus is present.

Functional Morphology

This individual exhibits little or no development of muscle attachment sites. The tibiae exhibit large squatting facets.

41RF1-BP04-014

From a Sort

This is a commingled burial with a minimum of three individuals sorted into 41RF1-BP04-019, 41RF1-BP04-025, and 41RF1-BP04-014. The sort is based on robusticity and color of the bones.

This individual is a female aged 25-34 years (code 23) represented by a fragmentary cranium and postcranial elements. The color of the bones is a light to medium orange-brown, and plant root damage is evident. The left third and fourth metacarpals and left hamate exhibit green staining indicating contact with a metallic object.

Age

Age is estimated using the auricular surface on the right ilium. This surface exhibits features consistent with Phases 2 and 3 suggesting an age range of 25-24 years.

Ancestry

No evidence of ancestry is present.

Sex

Sex is estimated as female based on the presence of a moderate preauricular sulcus and the overall small size of the postcranial elements.

Functional Morphology

The cranial fragments exhibit moderately developed supramastoid crest and nuchal muscle attachments.

The left and right distal humeri exhibit supracapitular facets indicating habitual tight flexion of the elbows. The left is more marked than the right humerus.

Pathology

The frontal and left and right parietals were scored for slight well-healed ectocranial porosis.

The distal humeri were scored for slight osteophytic lipping on the joint margins.

The third left metacarpal exhibits swelling of the shaft. Radiography of this bone reveals the cortical thickening is responsible for this swollen appearance. The other bones of this hand appear unaffected.

41RF1-BP04-016

This individual is a male aged 50-60 years (code 28) represented by a fragmentary but mostly complete skeleton. The bones are orange to medium brown in color and are root etched.

Age

Age indicators are numerous in this individual compared to others in this series. The cranial sutures are mostly obliterated which occurs at older ages. The rib morphology is consistent with a Phase 4-5 suggesting a range of 35-45. The pubic symphysis morphology is scored as a Todd Phase 8, which indicates an age range of 40-44. The auricular surface morphology is consistent with a Phase 8 and is characterized by very irregular and severely broken down surface with small areas of dense bone. Most of the joint surfaces exhibit slight to moderate arthritic changes. Vertebral osteophytosis is moderate to severe with marked porosity in the cervical centra. Based on all of these characteristics, the age is estimated as 50-60 years.

Ancestry

Ancestry estimation is uncertain at this time. The overall robusticity of this skeleton is slight in comparison to the Native Americans of this series. The occipital region is only slightly rugged. However, the femora were slightly platymeric, and the tibia exhibit small squatting facets. Although worn, the dentition shows shoveling.

Sex

Sex estimation is based on a femoral head diameter of 49 mm and the presence of a squared chin on the mandible.

Dentition

The dentition exhibits moderate to heavy deposits of calculus. No caries are present. The anterior teeth exhibit heavy wear, while the posterior teeth show little attrition.

Hypoplastic defects were observed on each of the maxillary and mandibular canines. The defects are plane-form in nature and extend past the heavily worn occlusal surface.

Functional Morphology

The right distal humerus has a marked supracapitular facet indicating habitual tight flexion of the elbow. The attachments for teres major and pectoralis major are slightly developed. The left distal ulna shows slight development of the attachment for pronator quadratus.

The femora have slight to moderate roughening of the areas for the gluteal muscle attachments. The left tibia has a slight squatting facet.

Pathology

The left temporomandibular joint (TMJ) shows slight porosity. The right TMJ is scored for moderate osteophytic lipping.

The atrium of the right maxilla exhibits evidence of sinusitis in the form of bony spicules.

A Staphne's defect is present on the left mandibular ramus. This defect is approximately 8 mm by 6 mm.

Most of the vertebrae exhibit slight to severe arthritic changes. Vertebral osteophytosis is moderate to severe. The cervical vertebra show marked porosity of the centra. The thoracic vertebrae have slight to severe porosity on the margins and joint surfaces of the articular facets. The lumbar vertebrae exhibit moderate osteophytic formation on the facets and the centra. The sacrum is more severely affected with severe lipping on the promontory.

Most of the joint surfaces exhibit light to moderate arthritic changes. The glenoid fossae of the scapulae have slight marginal lipping, and the right fossa also shows slight marginal porosity. The distal radii and proximal right ulna have slight marginal lipping.

Both acetabula have slight marginal lipping. The joint surfaces of the knees and ankles exhibit slight to moderate lipping on both the margins and surfaces.

The left patella was scored for slight healed enthesophyte development.

The left and right tibia and left fibula exhibit localized areas of healed periostitis on the proximal third diaphyses.

This individual is scored for generalized osteoporosis.

41RF1-BP04-018

From a Sort

This individual is a male, 40-49 years of age (code 26) of Native American ancestry. The skeletal remains were commingled with several other individuals, primarily with 41RF1-BP04-012. These 2 burials, 41RF1-BP04-018 and 41RF1-BP04-012, were disturbed during the interment of 41RF1-BP04-30. The bones are moderately preserved in a fragmentary condition and are the orange-brown color typical of this series. Several of the bones have a black soil adhering in small patches. A fragment of ilium exhibits a small area (9 mm by 15 mm) of green staining similar to that of copper salt staining.

Age

The age of this individual is estimated based on morphological changes of the pubic symphysis and auricular surface, as well as arthritic changes. The right pubic symphysis is consistent with a Todd score of 9 (45-59 years), and the auricular surface is consistent with a Phase 5 (40-45 years). These indicators in consideration with the extensive mild arthritic lipping on the joint surfaces, suggest the age is on the upper end of the 40-49 year range.

Ancestry

Ancestry of this individual is estimated as Native American based on nasal morphology, slight to moderate platymetric femora, and overall robusticity. The inferior nasal margin has a slight sill, which is indicative of Hispanic as compared to Native American, however the region of the nasal spine exhibits destruction from a possible lesion. The femora exhibit slight to moderate platymetric, and the postcranial elements are rather robust. These are characteristics that are indicative of Native Americans in this series.

Sex

Pelvis morphology and overall robustness of this skeleton suggest this individual is male.

Dentition

The dental health of this individual was poor. Periapical abscessing has resulted in the antemortem loss of the left

maxillary incisors. The left and right mandibular second and third molars are abscessing. The third molars exhibit porosity and loss of the alveolar margin suggesting periodontal abscessing. The left mandibular second molar was lost antemortem as evidenced by recent resorption of the bony socket. Calculus deposits were coalesced.

Functional Morphology

The supramastoid and nuchal regions of the cranium are moderately developed.

The postcranial skeleton is rather large and robust. The right clavicle exhibits a roughened attachment site for the deltoid muscle. The humeri have moderate development of the deltoid tuberosities and only slight development for the attachments for teres major and pectoralis major.

The femora exhibit a marked roughening in the gluteal muscle attachment sites.

Pathology

The left and right maxillae were scored for the presence of a possible lytic lesion located at the nasal spine region.

The vertebrae exhibit slight to moderate lipping on the facets and the centra. Two thoracic vertebral bodies have small Schmorl's depressions on the superior surfaces. The largest Schmorl's is broken postmortem preventing measurement. The smaller one measures approximately 9 mm in length and 2 mm in width. These depressions are oriented transversely.

The humeri, radius, and ulna exhibit slight lipping and porosity on the joint surfaces.

The right ischium exhibits slight enthesophytic development on the tuberosity. The right femur has slight lipping on both the proximal and distal joint surfaces.

41RF1-BP04-019

From a Sort

This is a commingled burial with a minimum of three individuals were sorted into 41RF1-BP04-014, 41RF1-BP04-019, and 41RF1-BP04-025. The sort is based on robusticity and color of the bones.

This is the most complete individual from the commingled sort. This is a male aged 35-44 (code 24) of Hispanic or Native American ancestry. Very little of the cranium is present, and the postcranial remains are incomplete. Like other burials

in this series, the bone is an orange-brown in color. Plant root damage is present. The postmortem fractures show evidence of recent and old damage.

Age

Age estimation is based on sternal rib end morphology, pubic symphysis morphology, and auricular surface morphology. The sternal rib end falls into a Phase 4, which provides an age range 25-34. The pubic symphysis scores are Todd Phase 6 (30-35 [Todd 1921]) and Suchey-Brooks Phase 3 (40-44 [Brooks and Suchey 1990]). The articular facets on the ribs exhibit arthritic lipping. These features in concert suggest an age range of 35-44.

Ancestry

Ancestry is estimated as either Hispanic or Native American. This estimate is based on the presence of slight platymeria seen in the femora and large squatting facets on the tibiae. The overall size of the long bones is not consistent with the Karankawa males in this series.

Sex

Sex is estimated as male based on the overall size of the postcranial skeleton. The long bone joint surfaces are in the male range. The femoral head diameter measures 47 mm.

Dentition

Only the maxillary right central incisor is present and exhibits moderate shoveling.

Functional Morphology

The left humerus shows only slight development of the deltoid tuberosity. The right ulna, in contrast, exhibits marked development of the attachment for pronator quadratus. This suggests that this individual was pronating his right arm habitually and not using his upper arms strenuously.

The femora exhibit moderate roughening in the region of gluteal attachments.

Pathology

Some of the pathology present on this individual is seen on elements not generally scored or coded. The left fifth metacarpal exhibits a small well-healed enthesophyte on the medial midshaft. The ribs exhibit slight arthritic lipping on the vertebral facets.

The vertebrae were coded for slight marginal osteophytic lipping on the articular facets.

The right tibia shows slight development of a healed and localized enthesophyte on the anterior tibial tuberosity

41RF1-BP04-021

From a Sort

This individual is a robust male, 45-54 years of age (code 27), of possible Native American or Hispanic ancestry. This burial was disturbed by later interments. Consequently skeletal remains that are fragmentary and represent only the head, shoulders, and incomplete arms represent the individual. The bone is a light to medium orange-brown in color with black soil like material adhering. Several of the postcranial elements exhibit postmortem chop marks from the disturbances, while the cranium exhibits several perimortem chops or edged blows and multiple cutmarks on the frontal.

Several individuals are actually represented in this burial. Leg bones of a smaller adult (41RF1-BP04-F01RA and 41RF1-BP04-T01RA) and infant bones were separated and coded as ossuary elements.

Age

Age estimation is based on the osteoarthritic changes exhibited on the joint surfaces and dental attrition and antemortem tooth loss.

Ancestry

Ancestry is estimated as either Native American or possibly Hispanic. This is based on the nasal aperture morphology and overall robusticity. The inferior nasal morphology exhibits a slight nasal sill, which is indicative of Hispanic as compared to Native American. The postcranial elements are robust which is indicative of Native Americans in this series.

Sex

Sex is estimated as male based on the robusticity of the skeletal elements. The proximal ulnae were moderately large, and the muscle attachment sites are also moderately developed. These characteristics are consistent with a sex assessment as male.

Dentition

This individual experienced poor dental health as evidenced by the antemortem loss of at least eight teeth. Dental attrition is moderate. Four of the five teeth present exhibit carious lesions ranging from small to large with resulting pulp exposure and abscessing. The maxillary teeth present include

the right canine and second molar and left first molar. All of these exhibit large carious lesions.

The mandibular teeth present include the right third molar, left first premolar and third molar. The left mandibular first premolar exhibits an antemortem fracture of the buccal cusp. The fracture margins on the distal surface exhibit smoothing, while the fracture margins on the mesial surface are not smoothed. The right third molar has a large carious lesion that has destroyed the mesial half of the crown. Both the third molars have abscesses.

Functional Morphology

The postcranial elements reflect heavy use of the shoulders and arms. The right clavicle exhibits a marked roughened area on the lateral anterior surface at the attachment for the deltoid muscle. Only a small portion of the inferior deltoid tuberosity is present and prevents examination of that attachment.

The left and right ulnae exhibit moderately developed regions for the attachment of the flexor carpi ulnaris muscles that suggests habitual flexion of the wrists.

Pathology

Both antemortem pathology and perimortem trauma are evident in this individual. Antemortem changes are seen in the form of osteoarthritic changes on the joint surfaces of the cervical, thoracic, and lumbar vertebrae, glenoid fossae, distal humerus, proximal radius and proximal ulnae. Slight liping and slight to moderate porosity were scored on these joint surfaces.

Perimortem trauma is evident on the cranium in the form of cutmarks and chops by a bladed or edged weapon. A minimum of 5 blows and 16 cutmarks are present on the right frontal and right parietal. The largest of the chops measures 13.3 mm in length and 2.6 mm in width. The majority of the wounds occurs on the frontal approximately 54 mm above nasion and lateral centering on the right portion of the frontal squamous. The cutmarks on the frontal range in length from 1 to 13 mm, however, the longest may actually measure longer than recorded as the posterior portion is missing postmortem. The cutmark on the right parietal is located just posterior to the coronal suture. This cut measures 13.9 mm in length. Perimortem trauma to the head may actually be more severe than recorded. This individual was scored as a traumatic death.

41RF1-BP04-022

This burial represents an infant, aged newborn to 6 months, of indeterminate ancestry. The skeletal material is disturbed and fragmentary. Elements were recovered with Burials 41RF1-BP04-021 and 41RF1-BP04-016. The pectoral elements are well represented but most of the major lower limb elements are missing. The bone is yellow to brown in color and in fair condition. No dental remains are present and pathological lesions are absent.

Age

Age is based on the diaphyseal length of the left radius (58.5 mm) and the left humerus (~69 mm). These lengths correlate to an age of newborn to 6 months based on Ubelaker's (1978) growth standards for Plains Native Americans.

41RF1-BP04-025**From a Sort**

A face and a few fragmentary postcranial elements represent this individual. This is a male, aged 35-39, of Native American ancestry. The individual was sorted based on overall robusticity and a distinctive darker color in comparison to the other individuals. The facial skeleton is the best preserved specimen in this burial feature.

Age

Age is estimated using the morphological features of the sternal rib end and auricular surface, and medial clavicle epiphyseal fusion. The rib end morphology is consistent with Phase 5, which provides an age range of 34-42 years. The auricular surface is scored as a Phase 4, providing a range of 35-39 years. Based on these scores, age is estimated as between 35 and 39 years.

Ancestry

Ancestry is estimated using the morphological features of the face and dental morphology. The face is large and exhibits wide malars. The nasal morphology is characterized by an absence of a nasal sill and slight prognathism. The palate is also large and wide. The lateral incisor exhibits moderate shovel shaping. These characteristics are consistent with Native American ancestry.

Sex

Estimation of sex as male is based on the marked robusticity of these remains. The face exhibits large malars well marked by masseter muscles. The ribs are also very large.

Dentition

Only maxillary teeth represent this individual. The right maxillary teeth include the lateral incisor, first and second premolars and molars. The left maxillary teeth include the canine, first and second premolars, and first and third molars. Calculus deposits range from flecks on the lateral incisor to heavy on the canine and first premolars.

Functional Morphology

The malars exhibit well-developed and rugged attachments for the masseter muscles. The dentition also exhibits multiple planes of wear that suggests use of the teeth in some habitual behavior other than normal mastication.

41RF1-BP04-025A**From a Sort**

This individual is represented by several upper appendicular elements. The individual is female, aged 25-35 (code 22), of indeterminate ancestry. Elements were sorted and grouped based on overall size and color in comparison to the other individuals. The humerus exhibits old postmortem damage on the middle shaft. The spiral fracture suggests the burial was disturbed while the bone was still in a relatively "green" condition. The deep chop marks adjacent to the fracture margin is clearly postmortem in origin.

Age

The age estimate of 25-35 years is based on the complete fusion of the medial clavicle and the lack of degenerative osteoarthritic changes in the other elements. The medial clavicle typically is completely fused by 26 years.

Sex

Sex is estimated as female based on the small size of the elements.

Functional Morphology

The distal humerus shows moderately developed attachment for the brachioradialis and extensor carpi radialis longus. These serve to flex the forearm and extend the hand.

41RF1-BP04-030

This is a young female, aged 14-16 years, of Native American ancestry. A mostly complete but fragmentary skeleton represents her. This burial was a primary burial with two others being disturbed during the interment of this female. The two disturbed burials were apparently placed on top of this burial. Minimal commingling occurred and the

discrepancies in age make sorting extremely easy. The bone is an orange-brown in color, and some of the elements have a dark brown or black soil adhering. The cranium is mostly present although fragmentary.

Age

Age is estimated based on dental development as well as skeletal development. The third mandibular molar exhibits root one half developed that corresponds to a mean age of 15.8 years. The epiphyseal closure of the long bones and other postcranial elements is complete in some joints, while completely open or unfused on others. This mixed state of fusion characterizes the mid-teen years of development. The dental and skeletal developments are consistent with an age range of 14-16 years.

Ancestry

Ancestry of this individual is estimated as Native American. The nasal morphology reflects a slight nasal sill and a lack of a nasal spine. The maxillary incisors are strongly shovel-shaped. The femur is slightly platymeric, and the tibiae exhibit small squatting facets.

Sex

The sex of this individual is estimated as female. The frontal exhibits no development in the supraorbital region, and the occipital exhibits slight development in the nuchal region.

The overall gracile nature of the postcranial elements as well as the very small femoral and humeral head diameters (40 and 38 mm respectively) is indicative of female sex assessment.

Dentition

All of the dentition is present. Calculus deposits range from flecks to moderate.

Functional Morphology

Due to the young age of this individual, morphological signatures of behavior are sparse. The distal humeri exhibit bilateral septal apertures. The distal tibiae exhibit small squatting facets.

Burial Feature 05

41RF1-BP05-009

This individual is an adult male aged 25-29 possibly of Native American ancestry represented by a partial, fragmentary

burial. The bone is light to medium brown in color with plant root damage. The upper thorax and cranium are present and undisturbed. The left tibia is the only appendicular element present. The remainder of the skeleton may be mixed with the undifferentiated elements from Burial Feature 5.

Age

The age is based on the extent of epiphyseal fusion and dental wear. The medial clavicle is completely fused. The epiphyseal rings of the vertebral centra are fused but lack any degenerative changes. Tooth wear is slight to moderate with most cusps flattened or blunted. These characteristics are consistent with an age range of 25-29 years.

Ancestry

Ancestry of this individual is probably Native American. The lateral upper incisor is shoveled. The zygomaxillary suture is direct and lacks recurvature. These characteristics are typical of Amerindian populations.

Sex

The sex estimate of this individual is based on the general size of the skeletal and dental elements and cranial morphology. The right malar and ribs are robust, and the teeth are large. These characteristics are typical of male individuals.

Dentition

The dentition is well represented. The alveolar bone consists of a few fragments that could not be correlated to specific teeth. The crowns are present but the roots are fragmentary. Calculus deposits are slight to heavy. No caries are evident, but several linear enamel hypoplasias are visible on upper and lower canines and the right maxillary lateral incisor.

Pathology

The only skeletal pathology present in this individual is a unusually curved sternum. The manubrium and sternal body are fused.

Extra Elements

- 1) 5th metacarpal from a child.
- 2) Mandible fragment and mandibular molars from an adult. Possibly a female based on the size of the teeth. Now is 41RF1-BP05-M01C.
- 3) Infant vertebral centrum.

41RF1-BP05-010

This individual is a subadult of indeterminate sex and ancestry. Cranial, vertebral, and long bone elements, and

ribs represent the individual. The bone is highly fragmentary, but in fair condition. The surface color of the bone is yellow to brown, and plant root damage is evident.

Age

The age of this individual was determined by measurements of the radius and ulna and overall development of the postcrania. The measurements produced an estimated age of newborn.

41RF1-BP05-011

This individual is a infant of indeterminate sex and ancestry. Fragmentary and incomplete cranial and postcranial remains represent the individual. The surface color of the remains is yellow to brown, and plant root damage is evident.

Age

Age for this individual was determined using development of the deciduous canine and deciduous molars. The right mandibular canine is crown complete, the maxillary left first deciduous molar is root initial, and the maxillary left second deciduous molar is crown complete. These stages give an estimated age of 0.5 to 0.7 year of age. Due to the fragmentary nature of these remains, the estimated age is birth to six months.

Dentition

Upper and lower canines, and the first and second upper molars represent the dentition of this individual.

A non-linear array of hypoplastic pits is present on the occlusal margin of the upper left canine.

41RF1-BP05-017

This individual is a young adult female aged 20-24 years of Native American ancestry. The skeleton is very fragmentary, but most elements are represented. The bones are the yellowish brown typical of this series, and they exhibit evidence of plant root damage. This individual was sorted and grouped by field excavators *in situ* and articulated elements could be grouped. A pipe trench disturbed the lower limbs, and several additional elements from adults and subadults were mixed with this burial. Burial 41RF1-BP05-009 was recovered directly above this individual.

Age

The age estimate of this individual is based on the degree of epiphyseal closure, pelvic indicators, cranial suture closure, dental wear, and degenerative pathology. The pubis

symphyses are fragmentary but are complete enough to assess for age. Both faces display completely fused pubic tubercles, a developing superior ventral demiface, filled dorsal furrows, and well defined ventral ridges and furrows. These characteristics are typical of Suchey-Brooks' Stage 2 and Todd's Stage 3. The eroded partial auricular surface appears fine-grained, which is consistent with a young individual. Cranial suture closure is limited, and dental wear is slight. The vertebral column exhibits severe degenerative pathology, but no other elements display such extreme pathology and appear young in texture. Taken together, these indicators are consistent with an individual in their early twenties.

Ancestry

Ancestry of this individual is estimated as Native American. This assessment is based on the presence of slight shoveling of the maxillary incisors and marked femoral platymeria. The skeleton is small, but this individual exhibits well-developed muscle attachments on the appendicular elements. These characteristics are indicative of a Native American.

Sex

The sex estimate is based on the small size of the skeletal elements, pelvic morphology and cranial morphology. The ventral arc of the pubic symphysis is developing, and the subpubic angle flares laterally. These characteristics are typical of female individuals.

Dentition

The teeth from this individual are small and lightly worn, however, severe dental pathology is evident. Numerous dental caries are present in mandibular and maxillary molars. Four of the mandibular molars have lesions, and three of the maxillary molars are affected. The crown of the mandibular left first molar is completely destroyed. Dental calculus deposits range from slight to moderate. The degree of alveolar resorption could not be assessed due to fragmentation. Several of the teeth have hypoplastic defects, but the most effected is the mandibular left canine with three observable linear hypoplastic grooves.

Functional Morphology

The right tibia and talus exhibit large squatting facets.

Pathology

Pathological lesions are present on the cranium and on the vertebral column. A well-healed cranial fracture is evident on the right frontal. The defect is located 18 mm above the supraorbital margin and 19 mm from the zygomatic process

of the frontal. The defect is oval-shaped and measures 15 mm long by 14 mm wide. Two bony projections fill the interior region of the defect. The margins of the projections and the defect are smooth and rounded indicating the trauma is not recent. Limited surface porosity is evident on the ectocranial surface of the frontal directly lateral of the defect. However, the endocranial table is too fragmented to assess.

Eight thoracic centra and one lumbar body display moderate Schmorl's depressions. These depressions are primarily located on the inferior surfaces of the centra. Severity is consistent throughout the series. Mild marginal porosity is evident on one lumbar centrum and three thoracic bodies. The pathological elements display slight to moderate compression on the anterior margins of the centra. A summary of the extent of anterior compression is provided in Table IIA-1. The lower thoracic and lumbar vertebrae are more anteriorly compressed than the upper thoracic elements. Marginal porosity is located along the anterior margins of the effected centra.

Extra Elements

- 1) Cranium fragments and dentition from an adult male which may represent an additional burial from Burial Feature 5.
- 2) Numerous infant fragment including a mandible, several ribs, proximal ulna, and radius shaft – placed with 41RF1-BP05-055.
- 3) Several elements associated with a small child (5-10 years). Elements include phalanges, ribs and epiphyses.

41RF1-BP05-032

From a Sort

This individual is a child aged 11 to 14 years (code 14) possibly of Native American ancestry. Skeletal material is

limited to the mandible and a fragmentary cranium. No postcranial elements were associated with this individual. The cranium and mandible were matched based on the presence of marked linear enamel hypoplasia on the permanent first molars and lateral incisors. In general, the bone is yellowish to brown bone with some plant root damage.

Age

The age of this individual is based on dental development. The roots of the upper third molars have just begun to develop, the initial cleft formation is evident in the lower third molars, and the apex of the first lower premolar is half closed. The mean age for this pattern is 12.6 years. The marked hypoplasia may have inhibited tooth formation. As a result of this insult, dental development may provide a low age estimate.

Ancestry

The upper lateral incisor is slightly shoveled, which is typical of Native American populations. The assessment is considered possible Native American due to the absence of more criteria.

Sex

The individual is probably female based on the morphology of the mandible and cranium. The mandibular eminence is pointed, the gonial angle is not direct, and the teeth are relatively small. These characteristics are typical of females.

Dentition

Eleven teeth and a nearly complete mandible represent the dentition. The premolars have erupted and are just reaching the occlusal plane. Three of the teeth are unerupted third molars. The crowns of the third molars are complete, and growth of the roots has initiated. Attrition is light to moderate

Table IIA-1. Vertebral Compression from Burial 41RF1-BP05-017

Vertebra	Posterior Height (mm)	Anterior Height (mm)	Compression Ratio (A/P)
T-6	19	18	0.95
T-7	19	17	0.89
T-8	18	17	0.94
T-9	18	17	0.94
T-10	20	17	0.85
T-11	24	19	0.79
T-12	22	19	0.86
L-1	23	19	0.83

with heavier wear on the molars. Calculus deposits range from flecks to coalesced rings. Hypoplastic defects are evident in six teeth including all four first molars, a lateral maxillary incisor, and a lateral mandibular incisor. The defects are present in the occlusal third of the crown for all teeth and indicate an age-at-insult between 1.5 to 2 years based on developmental standards.

Pathology

The dental pathology exhibited by this individual is consistent with congenital syphilis. Hypoplastic defects are evident in eight teeth from this individual. The defects present in the first molars and incisors are located in the occlusal third of each crown and correlate to an age-at-insult between 1.5 to 2.5 years based on Wright's (1997) developmental standards for Maya. The mandibular premolars exhibit linear defects in the apical third of the crown that correlate to an age-at-insult between 5 to 5.5 years.

The first molars exhibit morphological characteristics consistent with "Mulberry molars" as described by Hillson et al. (1998). The occlusal planes are dominated by severe hypoplasias, resulting in malformed cusps and dentin exposure. The hypoplastic defects consist of localized pits near the occlusal margin and linear field bands across the buccal surfaces (see Section F of this volume, Plate F-7). Approximately 75 percent occlusal enamel is missing from all the first molars. These areas probably represent locations of defective and incomplete enamel that has fractured or quickly worn down due to normal mastication. The remaining crown and root development in the molar is normal.

The two lateral incisors, one mandibular and one maxillary, exhibit severe linear hypoplastic defects. In the maxillary incisor, the defect is near the incisal margin that has resulted in a reduced incisal diameter. Such a pattern is consistent with a Hutchinson's incisor (Hillson et al. 1998), but this term is typically restricted to central incisors. In the mandibular incisor, the hypoplasia represents a wide field defect extending from the incisal third of the tooth to the middle of the crown. These defects have resulted in a reduced incisal diameter.

Various researchers identify Mulberry molars and Hutchinson's as classic dental stigmata of congenital syphilis (see Hillson et al. 1998 for a review). The dental defects present in this individual are consistent with these descriptions, but the age-at-insult between 1.5 and 2.5 years is later than typically documented in congenital syphilis

cases (Hillson et al. 1998:26). No postcranial skeletal elements are present, and no bone pathology is evident in the cranium.

41RF1-BP05-033

This very disturbed burial is a young adult male of unknown ancestry represented by a fragmentary right humerus and fragmentary left radius. The bone is orange-brown in color and while fragmentary the bone is well preserved. Both elements are robust.

Age

The age estimate is estimated as young adult based on closure of epiphyses and lack of degenerative changes on the articular surfaces.

Sex

Sex estimation is based on the robusticity of the two long bones.

Functional Morphology

The right humerus exhibits moderate development of the attachments for the pectoralis major, teres major, lateral head of the triceps, and deltoid muscles. The distal humerus exhibits marked development of the lateral supracondylar ridge for the attachments of the extensor carpi radialis muscle.

41RF1-BP05-034

From a Sort

This individual is a child aged 9 to 12 (code 12) of indeterminate ancestry and sex. The skeletal material is in good condition, but most elements are extremely fragmented. Additional elements were sorted from the mixed elements recovered from the lower half of Burial Feature 5. The individual was easily identified based on overall size and skeletal development. In general, the bone is yellowish to brown with some plant root damage.

Age

The age estimate is based on epiphyseal fusion, femur diaphyseal length, and dental development. The vertebral bodies exhibit fusion lines at the neural arches, and the long bone epiphyses are completely separate. The estimated length of the femur diaphysis (285 mm) corresponds to an age of 7.5 to 8.5 years. The development of the third molars (maxillary and mandibular) and maxillary premolars correlate to crown half complete (C ½) and root half complete (R ½), respectively. The dental development is consistent with an individual from 9 to 12 years.

Ancestry

Ancestry could not be estimated for this individual. The only criterion present is slight platymeria of the proximal femur.

Dentition

The dental remains are in good condition. The entire mandible is present but fragmentary. The maxillae are poorly represented. All the incisors and canines are missing postmortem. The second maxillary deciduous molars are still present. The roots have been eroded to make room for the premolar crown. Development of the premolars is root ½ as previous mentioned. The first molar is complete with slight occlusal wear. The partial third molar crowns are unerupted. A large interproximal lesion with pulp exposure is present in the maxillary second left deciduous molar. One distinct linear enamel hypoplasia is evident in all three maxillary premolars as well as on the maxillary first molars.

Pathology

Moderate cribra orbitalia is present bilaterally. The condition exhibits spicule development in the central portion of the supraorbital plate. The left orbit appears more severe than the right, however both sides are fragmentary.

41RF1-BP05-035**From a Sort**

This individual is a newborn infant (code 01) of indeterminate ancestry and sex. The skeleton is mixed with another newborn infant identified as 41RF1-BP05-055. The skeletal material is fragmentary and limited to a few cranial elements and two long bone sections.

Age

The age is based on the relative size of the fibula and right ulna segments. Neither element is complete, and no dental remains are present.

41RF1-BP05-036**From a Sort**

This individual is a very gracile female aged 30-39 (code 23) of Native American ancestry. The skeletal material is in good condition, but the cranium is extremely fragmented. Additional elements were sorted from the mixed elements recovered from the lower half of Burial Feature 5. The individual was easily identified based on overall size. In general, the bone is yellowish to brown with some plant root damage.

Age

Age is estimated utilizing epiphyseal fusion of the medial clavicle, auricular surface and pubic symphysis morphology, and secondary degenerative indicators. The medial clavicle and iliac crest are completely fused. The right auricular surface exhibits coarse texture with well defined surface organization and slight striae. The left surface exhibits marked microporosity, coarse to dense surface texture, and slight lipping at the apical margin. These characteristics are consistent with a Phase 3 for the right side and Phase 5 for the left. The right pubic symphysis is severely broken down. The surface displays marked porosity, complete destruction of the dorsal margin, and moderate dorsal lipping. This pattern is consistent with Todd's Stage 10 and Suchey-Brooks' Stage 6. Mild marginal osteoarthritic lipping is evident on the proximal ulna, odontoid process of the second cervical vertebrae, and acetabulum. These indicators suggest an age range estimate of 30 to 39 years.

Ancestry

Ancestry is estimated as Native American based on the presence of platymetric proximal femora, moderately robust facial structure, slight squatting facets, and a shovel-shaped lateral maxillary incisor. Overall, this individual is very gracile, but muscle attachment sites are well defined which is consistent with a Native American pattern.

Sex

This individual is extremely gracile. The morphology of the pubic bone is square with a wide subpubic angle and sharp subpubic ramus. The morphology of the pubic symphysis is elongated and very porous with a large "parturition" pit. Such defects have often been associated with childbearing, but this association is tenuous.

Dentition

The mandible and maxilla are both fragmentary. All molars are present but only one anterior tooth is included. The alveolar structure for the entire right maxilla is present, but the teeth are missing postmortem. A large periapical abscess is associated with the maxillary central right incisor. The molars exhibit light to moderate occlusal attrition with no evidence of carious lesions. The limited alveolar structures associated with the molars are well-developed and display no periodontal changes. The maxillary left lateral incisor is shoveled with slight attrition and is relatively large compared to the molars.

Functional Morphology

Overall the bones are small with slight to moderate muscle attachment sites. The clavicle displays well marked attachment sites of the deltoid and pectoralis muscles.

Pathology

Identified pathological conditions include osteoarthritic changes, a periapical abscess, and a non-osseous tarsal coalition (Regan et al. 1999). Mild marginal osteoarthritic lipping is present on the dens process of the second cervical vertebra, the proximal right ulna, and the right acetabulum. A non-osseous tarsal coalition of the third cuneiform and metatarsal is evident. This coalition consists of a small (2 mm) defect on the plantar margin of the anterior/proximal cuneiform and posterior/distal metatarsal.

41RF1-BP05-039

This individual is a male aged 20-24 (code 21) of indeterminate ancestry. Evidence of a traumatic death is present in the form of a metal projectile point present in the rib cage and recovered during the excavation. Other evidence of a traumatic death includes the presence of multiple cutmarks on the anterior cranial vault indicating perimortem scalping. Small rust colored stains are present on the anterior centra of three of the thoracic vertebrae. Due to the fragmentary nature of the ribs and vertebrae, the identification is limited to upper thoracic region.

A nearly complete but fragmentary skeleton represents the remains. The cranium is extremely fragmentary allowing for only a few cranial measurements. Only a few small fragments of the face are present. The bone is in a good condition (although fragmentary) and is a light to medium brown orange in color.

Age

Age is estimated using the epiphyseal fusion of the clavicle, vertebral rings, and iliac crest. The medial clavicle exhibits partial fusion of this epiphysis, as does the iliac crest. The vertebral rings exhibit recent fusion. The third molars have completed root formation. These indicators taken in concert allow for a relatively narrow age range estimate of 20-24 years.

Ancestry

Ancestry estimate as possible Native American is tentative as it is based only on the presence of moderate platymeria of the proximal femora. The maxillary incisors are slightly shoveled.

Sex

Sex is estimated as male based on the pelvic morphology and generally larger size of the postcranial elements. The pubis lacks a ventral arc.

Dentition

All of the teeth are represented for this individual while only fourteen tooth sockets are present. The maxillary first molars exhibit small occlusal caries, and the mandibular first molars exhibit small buccal caries. Calculus deposits range from flecks to three-dimensional, the worst located on the anterior mandibular teeth.

Functional Morphology

The muscular development of this individual is moderate compared to other individuals in this series. The deltoid attachment of the clavicles shows moderate development. The humeri exhibit slight to moderate development of the attachments for the pectoralis major, teres major, latissimus dorsi, lateral head of the triceps, and deltoid muscles. The distal humeri exhibit marked development of the attachment for extensor carpi radialis on the lateral supracondylar ridge. The ulna exhibits moderate development of the attachment for pronator quadratus.

The proximal femora exhibit roughening at the attachments for the gluteal muscles. The middle third of the shaft shows anterior-posterior elongation, however, the linea aspera is not marked.

Pathology

Pathology is present in antemortem and perimortem forms. The frontal and left and right parietals were scored for mild active ectocranial porosis. The anterior portion of the sagittal suture exhibits complete fusion and obliteration.

Perimortem trauma is evidenced by numerous cutmarks on the anterior cranial vault indicating this individual was scalped at or near the time of death. A minimum of twenty cutmarks was recorded on the frontal and left and right parietals. Examination of the fragments representing the posterior vault did not yield any cuts to this portion of the cranium, however, much of the bone is missing. The cuts are very narrow suggesting that the attacker employed a sharp metal blade. The widest cut is labeled "Q" measuring approximately 0.7 mm in width. The lengths of the cutmarks range from approximately 2 mm to as long as 95 mm. The cutmarks are labeled with letters and measurements are

presented in Table IIA-2. The orientation of the cuts on the frontal bone is diagonal with the right side showing the more anterior and inferior cuts and the left side being where the more superior and posterior cuts are located.

During the excavation of this burial a metal projectile point was found in association with the rib cage. Close examination of the rib fragments revealed a perimortem cutmark on one right rib from the upper to mid thoracic region. This cutmark is located on the superior surface approximately 20 mm lateral to the center of the tubercle of the rib. The length of the cutmark is approximately 9.4 mm, and the deepest portion of the cut is located medially.

Based on the presence of multiple perimortem cutmarks, this individual was scored as a traumatic death and projectile present.

The calcanei exhibit bifurcation of the anterior and medial talar articulations. A moderately deep non-articular interval and medial displacement of the surfaces where the talus articulated indicates that there may have been an inversion of the ankle, the right more than the left. The lateral side of the

right calcaneus exhibits a marked development of the peroneal trochlea, which may have responded to the inversion.

41RF1-BP05-040

From a Sort

This individual is an adult male aged 30-39 (code 23) of indeterminate ancestry. The individual is represented by cranial and postcranial axial elements. The remains are quite fragmented which hindered the assessment of ancestry. The surface color of the remains is yellow to brown, and plant root damage is evident.

Age

Age for this individual is estimated between 30 and 39 years. This estimate is necessarily broad due to the extreme fragmentation. The left TMJ exhibits slight porosity, and the vertebral centra exhibit slight marginal lipping. These arthritic changes are consistent with a late young adult.

Sex

Estimation of sex is based on the moderate sized mastoid process and moderate development of the supramastoid crest.

Dentition

The dentition for this individual included the right maxillary premolars and the first right and left molars. Wear was scored as slight, and calculus was moderate to coalesced. The upper left lateral incisor was lost postmortem, and was affected by a periodontal abscess. The second maxillary premolar had a root caries on the mesial interproximal surface. The maxillary first left molar has a root caries on the distal-interproximal surface with pulp exposure. There is a linear enamel hypoplasias on the second maxillary premolar.

Pathology

Schmorl's nodes were present on the inferior endplates of the 12th thoracic and 1st lumbar vertebrae. Slight osteophytic formation is on the centrum margin of T10, and slight lipping and porosity are present on the facets of T10-T12.

41RF1-BP05-040A

From a Sort

This individual is a male represented by a few fragmentary elements from both the axial and appendicular skeleton. This burial is highly disturbed and is sorted from the previously described individual based on duplicated elements and size discrepancies. Age is estimated as young adult, and ancestry is indeterminate. Sex is estimated as male based on the robustness of the glenoid fossa, radius and ulna.

Table IIA-2. Cutmarks on cranial vault of 41RF1-BP05-039

Cutmark	Length (mm)
A	6.9
B	22.6
C	19.3
D	85.6 (chord) 95 (with tape)
E	12.8
F	36.3
G	7.7
H	27.8
I	2.7
J	6.7
K	11.7
L	Not a cut
M	58.4
N	2.0
O	10.4
P	23.2
Q	10.7 (widest cut at 0.7 mm)
R	15.4
S	9.8
T	7.6
U	9.7

Functional Morphology

The right ulna displays moderate development of the interosseus crest and attachment for brachialis.

Pathology

The second lumbar vertebra exhibits slight osteophytic marginal lipping of the vertebral facet, and moderate porosity on the facet surface. L4 displays slight eburnation on the margin of the superior articular processes. This damage is most likely caused by a traumatic event centered on the 3rd – 4th lumbar vertebrae that wedged the superior articular facet of L4 into the spinous process of L3, also resulting in spondylolysis of L4. Also, L4 and L5 show moderate osteophyte formation, as well as moderate porosity on the centrum margin due to an irritated vertebral disk most likely resulting from the increased movement of the joint from the separation of the neural arch of L4. In response to the increased pressure, L5 is wedge shaped with the body being reduced from 29 mm on the left lateral side to 24 mm in height on the right lateral side of the body.

A fragment of the sacrum is present that exhibits a healed and unfused fracture of the right ala with approximately half of the sacroiliac joint surface present. This bone fragment appears to have been held in place by the attendant muscles and ligaments, however due to the fragmentary nature of the bone, analysis is necessarily limited.

This individual has a healed fracture of the right distal radius.

41RF1-BP05-055**From a Sort**

This individual is a newborn infant (code 01) of indeterminate ancestry. The skeleton is mixed with 41RF1-BP05-035, a newborn infant. The skeletal material is fragmentary, but most elements are represented. No diaphyseal sections are complete, and no teeth were identified.

Age

The age is based on the relative size of the long bone shaft sections and vertebral body size. The left clavicle is complete, measuring 42 mm in length that corresponds to late term fetal or newborn development.

41RF1-BP05-066**From a Sort**

This individual is an older adult aged 35 to 50 years (code 97). Based on characteristics of the teeth, the individual may be of Native American ancestry. The individual is

represented by a series of teeth, cranial fragments, and upper vertebral elements. The skeletal material is in good condition, but the elements are extremely fragmented. In general, the bone is dark brown with some plant root damage.

Age

The age estimate is based on the degree of dental attrition and the extent of vertebral degenerative joint disease. Heavy occlusal wear and moderate vertebral lipping are consistent with an adult over 35.

Ancestry

The teeth exhibit heavy occlusal attrition with an edge-to-edge wear pattern, which is typical of Native American populations.

Sex

The sex of this individual is possibly male. Overall, the teeth and vertebral centra are large.

Dentition

Eleven maxillary and mandibular teeth are represented. A small alveolar section of the right maxilla is present. Overall, occlusal wear is moderate to heavy. Wear varies as a result of antemortem tooth loss. The occlusal surface of the third right maxillary molar is completely encased in calculus. Deposits on the other teeth range from flecks in the lower incisors to heavy on the molars. Periapical abscesses are associated with the maxillary right lateral incisor and canine, and the first premolar is missing antemortem with complete resorption of the socket. A interproximal root caries is located on the distal margin of the right canine. The mandibular first molar appears to have been lost antemortem based on the polished appearance of the interproximal facet on the left mandibular second premolar. Two additional carious root fragments are present, but these elements could not be specifically identified.

Pathology

Skeletal pathology is limited to vertebral degenerative joint disease. The centra of the cervical vertebrae have moderate osteoarthritic marginal lipping and moderate surface porosity.

41RF1-BP05-073

This individual is a child, aged 2.5 to 3.5 years, of Native American ancestry. The burial is represented by only a fragmentary cranium and seven maxillary teeth. The bone is a deep orange-brown in color.

Age

Age is estimated based on dental development of the left maxillary first permanent molar and left maxillary central and lateral incisors. The laterals of the occipital are unfused.

Ancestry

Ancestry is estimated as Native American based on the presence of strongly shoveled incisors.

Burial Feature 06**41RF1-BP06-031**

This is an extremely fragmentary burial representing a female aged 40-49 years of indeterminate ancestry. The bone is light to medium brown in color with root damage and adhering soil. A soil matrix holds the proximal tibiae together. The right scapula has green staining on the body.

Age

The age is estimated using the presence of osteoarthritic lipping on the joint surfaces. The hand bones exhibit slight to moderate arthritic changes. The overall density of the bones is good and in conjunction with the arthritic lipping indicates an age range of 40-49 years.

Ancestry

Ancestry is indeterminate in this individual. None of the indicators or features are present to suggest an ancestry.

Functional Morphology

The lateral epicondylar ridge is moderately developed of the right humerus. The femora are slightly platymeric.

Pathology

Most of the joint surfaces present were for scored slight lipping.

Burial Feature 07**41RF1-BP07-038**

This individual is a female aged 55+ years of either Hispanic or European ancestry. The skeleton is in a poor and very fragmentary state. The bones are the orange-brown typical of this series. The bone exhibits evidence of root damage.

Age

The estimated age of this individual is based on the degenerative arthritis on the vertebral fragments and the auricular surface morphology. The lumbar vertebrae exhibit evidence of osteoarthritic changes associated with older age. The auricular surface is scored as Phase 7 (50-59 years). While considering the fragmentary condition limits the assessment, these characteristics suggest an age range of 55 years or older.

Ancestry

Ancestry of this individual is estimated as either Hispanic or European. This assessment is based on inferior nasal sill morphology, slight platymeria, small squatting facets, and overall gracile nature of the bones. The nasal sill is moderate in relief, and the skeletal elements exhibit very slight muscle development. These characteristics are indicative of European ancestry. The right femur exhibits slight platymeria, and the tibiae have small squatting facets. These characteristics are indicative of Hispanic or Native American.

Sex

The sex estimate of this individual is based on the small gracile skeletal elements.

Dentition

The anterior portion of the dental arcade of the maxillae and mandible is present and shows evidence of extensive antemortem dental loss and possibly edentulous.

Functional Morphology

Although the bones are very fragmentary, it is obvious that this individual had little or no muscle development. The only evidence of habitual activity is present in the left and right greater multangular bones of the wrist. These bones of both wrists exhibit eburnation from extensive movement at the carpal metacarpal articulation.

The left and right tibiae exhibit small squatting facets.

Pathology

The skeleton exhibits osteoarthritic changes (lipping and/or porosity) ranging from slight to severe. The temporomandibular joints exhibit moderate erosion in the mandibular fossae bilaterally.

Osteoarthritic changes are present in the form of lipping and porosity in the cervical, thoracic and lumbar vertebrae. The most severe surface porosity is evident on the facets of the lumbar vertebrae.

The left and right first ribs and two other middle ribs exhibit healed localized slight periostitis. A dense bony build-up on the inferior surface of the first ribs, anterior to the articular tubercle most likely represents pleural adhesions.

The greater multangulans exhibit eburnation on the articular facet for the metacarpals. The first metacarpal exhibits an erosive arthritic lesion on the inferior margin of the distal articulation.

The right distal femur and right proximal tibia exhibit severe porosity and eburnation. The joint surfaces are extremely fragmented, but the porosity and eburnation appears to be restricted to the lateral condyle. Degenerative activity is focused in the central and distal portions of the tibial articulation. Porosity increases towards the lateral margin of the surface, but the lateral border is missing as a result of post-depositional damage.

Burial Feature 08

41RF1-BP08-020

This burial is represented by a very fragmentary skeleton of a female, aged 25-34 years (code 22), of possible Native American ancestry. This burial was a primary interment that disturbed another burial, 41RF1-BP08-026. While these burials were somewhat commingled, a sort was not necessary. These bones are light to medium brown in color, and root damage is apparent in the cortical surfaces. There is an orange, possibly rust, staining on some of the rib fragments. This has been labeled as red ochre staining, however, this does not seem to be the case. Excavation photographs show that the burial was disturbed by the intrusion of an iron pipe across the middle part of the burial most likely resulting in rust staining on the bones.

Age

Age is estimated based on the sternal rib end morphology and presence of slight arthritic changes. The rib end morphology is consistent with a Phase 5 (33-46 years). Several of the joint surfaces are exhibiting the beginnings of degenerative changes. These characteristics are indicative of an age range of 30-39 years. However, a maxillary third molar has not completed its development. The other maxillary

third molar also shows evidence of recent eruption. This dental development indicates a younger age. With all the indicators in consideration, the age is estimated as 25-34 years.

Ancestry

Ancestry is estimated as possibly Native American for this individual. The incisors are strongly shovel-shaped. However, no other criteria are present to base an estimate. The general size of the individual is small and gracile, but no other morphological evidence is present.

Sex

The sex estimate is female based on the gracile nature of the bones. The humeri are very small with a maximum estimated midshaft diameter measuring 19 mm.

Dentition

All of the teeth are present for this individual. Several of the teeth exhibit pit caries predominantly on the interproximal surfaces. The mandibular right second premolar exhibits a larger carious lesion on the interproximal surface that has resulted in pulp exposure. Calculus deposits range from flecks to heavy.

Several of the teeth exhibit antemortem enamel chipping.

The left maxillary lateral incisor exhibits a marked notch in the occlusal surface that is sometimes referred as a Tailor's notch. The left maxillary second premolar also exhibits a notch that is smaller in depth.

Functional Morphology

Due to the fragmentary nature of the remains, little evidence is present to evaluate functional morphology.

Pathology

The distal left humerus and distal left and right femora exhibit slight osteoarthritic lipping.

Extra Elements

- 1) One adult central incisor.
- 2) Two fragments of adult tali.
- 3) Infant bones.

41RF1-BP08-026

This individual is extremely fragmentary. The burial consists primarily of limb elements. No cranial or axial material is present. The individual is a male, aged 25-35 years (code 96), of indeterminate ancestry. The remains represent a secondary

burial recovered near 41RF1-BP08-20. The bones exhibit root damage and postmortem damage associated with disturbance of the burial (fragmentation and surface scrapes).

Age

The age is simply based on the condition of the bone and the degree of osteoarthritis. No primary age indicators are present. All observable epiphyseal locations are fused, and slight osteoarthritis is present on the distal humerus bilaterally. This pattern suggests a young adult individual over 25 years old (15-35, code 96).

Ancestry

Ancestry is indeterminate for this individual. No skeletal criteria are present to base an estimate. The general size of the individual is robust and large, but no morphological evidence is present.

Sex

The sex is estimated as male based on the general robustness nature of the elements.

Functional Morphology

The linea aspera of the right femur exhibits slight development especially in the upper half. The femora exhibit roughening at the gluteal attachments.

Pathology

The pathological changes observed include enthesopathies and osteoarthritic lipping. Slight bilateral osteophytes are present on the distal humerus articular surface. Mild enthesophytes are evident on the palmar surface of a proximal hand phalanx, on the superior aspect of the patella, and along the anterior margin of the distal right fibula.

Extra Elements

- 1) Infant right temporal (petrous portion) – became 41RF1-BP08-020A.
- 2) Juvenile ilium fragment near acetabulum (unfused).

Burial Feature 09

41RF1-BP09-041

Very incomplete remains represent this burial. Four deciduous teeth, one proximal hand phalanx, one half of a vertebral arch fragment, and the proximal third of the left ulna are present. The mandibular deciduous canines are crown ½ that indicates an age range of newborn to 6 months.

41RF1-BP09-042

This individual is one of the better preserved with the exception of the skull. The individual is a female, aged 40-49 years (code 25), of possible European ancestry. The burial represents a coffin burial, and the bones have some dark brown stains. The skull has cracking and exfoliation on the outer table, which is also a dark brown in color. The postcranial elements exhibit root damage.

Age

The age is estimated using morphological features of the pubic symphysis and auricular surface and the degenerative changes on the joint surfaces. The pubic symphysis is scored as a Phase 10 in the Todd system, and a Phase 6 in the Suchey system. These suggest age is over 50 years. The auricular surface is scored as Phase 5-left and 4-right suggesting an age range of 35-44 years. The degenerative changes exhibited on the joint surfaces are minimal. This slight level of arthritic change suggests the younger end of the 40-45 year range. Based on these age indicators, the age is estimated as 40-49 years.

Ancestry

Ancestry is estimated using the dental morphology and postcranial morphology. The incisors lack shovel shaping. The overall size of the dentition is small. The proximal femora are round. These features are characteristic of European ancestry. However, the tibiae exhibit moderate squatting facets.

Sex

The sex is estimated as female using the pelvic morphology and gracile nature of the postcranial elements. The pubic bone is very wide.

Dentition

The dentition of this individual is very small for this series. The maxilla and mandible are fragmentary, and several teeth are present without the alveolar tooth sockets. The maxillary left first molar, maxillary right canine, and the mandibular right first molar have been lost antemortem as evidenced by alveolar resorption.

The right maxillary first molar and the left mandibular first and second molars exhibit carious lesions. The caries are focused at or below the cemento-enamel junction (CEJ) suggesting marked periodontal resorption. A large periapical abscess encompasses a small root fragment of the maxillary left second molar. The abscess is associated with a sinus fistula extending into the left maxillary atrium.

Calculus buildup on these teeth ranges from flecks to three dimensional. Calculus deposits are present on the occlusal surface of the maxillary right first molar. Numerous linear enamel hypoplasias are evident on the maxillary incisors and mandibular canines. These defects are restricted to the apical third of the crowns.

Functional Morphology

The left and right clavicles exhibit marked development for the attachment for the deltoid muscle. The right is more marked than the left. The humeri exhibit slight development of the attachments for the pectoralis major and teres major. The lateral epicondylar ridges are moderately developed.

The pubic bones exhibit long deep dorsal pits indicating several episodes of childbirth.

The femora exhibit roughening at the gluteal attachments.

Pathology

The only pathological lesions scored on this individual are slight arthritic changes as either lipping or porosity. Moderate articular porosity is evident on the mandibular condyle and mandibular fossa of the temporal. All of the vertebral sections exhibit slight marginal lipping and joint surface porosity. Marginal osteoarthritic lipping is evident on the distal ulna and radius. The hands exhibit slight to moderate arthritic changes. The right first metacarpal and trapezium exhibit osteoarthritic lipping and articular surface eburnation. Degeneration of this joint is possibly associated with a compression fracture of the trapezium.

Additional skeletal anomalies include unilateral os acromiale on the left scapula and bony changes associated with chronic maxillary sinusitis. Ossified hard tissue evidence of chronic maxillary sinusitis is visible in both atria. Slight surface porosity and bony spicules are present in the left atrium. Changes in the left sinus are more severe as a result of the oro-atrial fistula associated with the periapical abscess of the second molar.

Extra Elements

- 1) Infant cranial and postcranial elements – moved to 41RF1-BP09-041.

Burial Feature 10

41RF1-BP10-043

This burial is represented by a very fragmentary skeleton of an adult male, aged 25-34 years (code 96), of indeterminate ancestry. This burial was a partial primary interment that was disturbed by road construction. The lower limb elements and sacrum are well represented, but these bones are very fragmentary. A few vertebral and upper limb bone fragments are also present. The bones are orange to brown in color and exhibit plant root damage.

Age

The age estimate is based on a limited number of general observations. No primary age indicators are present. Osteoarthritic lipping is present on the proximal and distal femur, but these lesions are restricted to marginal lipping. The general appearance of the bone is youthful and appears to be from a young adult between 25 and 35 years.

Sex

The sex estimate is male based on the robust nature of the skeletal material.

Functional Morphology

Due to the fragmentary nature of the remains, little evidence is present to evaluate functional morphology. However, the femora, tibiae, and fibulae are well marked with muscle attachments and are quite large.

Pathology

The distal left femur and right proximal femur exhibit slight osteoarthritic lipping. A small enthesophyte is present at the right tibial tuberosity. A small osseous elevation exists on the left tibial tuberosity, but this was not as developed as the lesion on the right tibia.

Burial Feature 11

Six burials were identified in this feature (41RF1-BP11-044, 044A, 045, 054, 058, and 059). Several elements were found mixed between the five individuals. These remains were placed with the proper burial. Identification was based on development or general robusticity.

41RF1-BP11-044

This is a very fragmentary skeleton of an individual representing an adult male, aged 35-45 (code 25), of possible Native American or Hispanic ancestry. Although this burial is a primary one, the lower limbs extend under a disturbed group of elements identified as 41RF1-BP11-054 and 41RF1-BP11-044A. A tooth found with 41RF1-BP11-044 is from 41RF1-BP11-054. The bones are light to medium orange brown in color, and plant root damage is evident.

Age

The age estimate is based on the surface morphology of the pubic symphysis, dental wear, and general postcranial degenerative bone pathology. The pubic symphysis is smooth with a complete symphyseal rim and slight marginal osteophyte development. The surface is typical of Todd's Stage 8 and Suchey-Brooks Phase 5. The component scores for McKern and Stewart (1957) are 5-5-4, which correspond to a 29+ age range for males. The teeth are moderately worn with secondary dentine exposure on the first molars. The vertebrae display slight osteophyte development on the margins of two centra. These traits are characteristic of an adult between 35 and 45 years old.

Ancestry

Ancestry of this individual is possibly Native American or admixed. The postcranial skeleton exhibits the typical morphology of marked robusticity and large joint surface areas. The incisors are moderately shovel-shaped. These characteristics are indicative of Native American ancestry. However, the inferior nasal aperture is more European in morphology. The nasal aperture appears to be relatively narrow with a well-marked sill. These features may suggest admixed ancestry.

Sex

Sex is estimated as male based on the robust and large size of the skeletal elements and the morphology of the pubic symphysis. The femoral head is greater than 50 mm in diameter.

Dentition

The dentition is well represented but surrounding alveolus is poorly preserved. The entire right maxillary series is present. One interproximal caries at the CEJ is present on the right second maxillary molar. Two lesions are evident in the mandibular series including a small occlusal pit caries on the right second molar and a buccal root defect on the left third molar. Several anterior teeth display chipped enamel along the labial/buccal margins; the right maxillary incisors,

canine and first premolar, and mandibular right first premolar and left canine. One slight interproximal groove is evident between the first and second lower left molars.

Functional Morphology

The fragmentary nature of the bones prevents analysis of the functional morphology.

Pathology

The inferior border of the nasal bones and nasal border of the maxillae are remodeled and pitted. Some type of destructive lesion has resorbed the margins. The margins of the defect are not sharp or clear delineated. The nasal bones slope into the nasal aperture.

Slight osteoarthritic lipping is evident on the distal femora and proximal ulna. The right patella is bipartite and exhibits a 2.1 cm notch on the superior medial surface. The small patellar bone fragment is present and displays a roughened surface along the margin that coalesces with the patellar body.

41RF1-BP11-044A**From a Sort**

This individual is an infant (code 01) of unknown sex or ancestry. The remains were associated with 41RF1-BP11-044. This burial is fragmentary, and the bones are a light to medium brown in color. The elements that represent this individual include the right temporal, right maxilla fragment, several small cranial fragments, the left maxillary canine, two vertebrae, fragments of four ribs, left scapula fragment, and fragments of the right ulna, tibia and fibula. Age is estimated based on the small size of the elements and dental development.

41RF1-BP11-045

This is a very fragmentary skeleton of a female, aged 18-24 (code 21), of Native American ancestry. Although this is a primary burial, it is slightly commingled with the adjacent burial, 41RF1-BP11-044. The bones are light to medium orange brown in color, and plant root damage is evident.

Age

The age is estimated based on unfused epiphyses on the vertebral bodies, iliac crest, and ischial tuberosities. The epiphyses on the heads of the ribs are beginning fusion. The long bones have completed fusion of their epiphyses. These features indicate an age range of 18-24 years.

Ancestry

Ancestry is estimated using dental and femora morphology. The incisors are shovel-shaped, and the femora are moderately platymeric. These characteristics are indicative of Native American ancestry.

Sex

Sex is estimated as female based on the gracile size of the skeletal elements. The femoral head diameter is 40 mm.

Dentition

The majority of the teeth are present, however, none of the maxillary or mandibular alveolar bone is present. The maxillary canines and mandibular central incisors, canines, and left lateral incisor are missing. The observable teeth have no carious or abscess activity. The teeth exhibit slight attrition, and calculus deposits range from slight to moderate.

Pathology

The posterior middle third shaft of the right tibia exhibits an area of healed localized mild periostitis. The bone is fragmented, and the medullary cavity exhibits some change.

Extra Elements

- 1) Infant bones including a left femur – added to 41RF1-BP11-044A.

41RF1-BP11-054

This individual is a very fragmentary skeleton representing a young adult male, aged 25-35 (code 22). The individual is probably of Native American ancestry based on dental morphology and overall size. The bones are light to medium orange brown in color, and plant root damage is evident. Green copper staining is present on the neural arch of a mid cervical vertebra (C3-6). Although these remains are from a primary interment, several additional elements from an infant are mixed with this burial. The infant remains are considered part of 41RF1-BP11-59, and have been coded with that burial.

Age

The age is estimated based on the complete fusion of all available epiphyses including medial clavicle and sacral bodies. Dental attrition is slight and no degenerative pathology is present. These limited features indicate an age range of 25-35 years.

Ancestry

Ancestry of this individual is possibly Native American. The postcranial skeleton exhibits the typical morphology of

marked robusticity and large joint surface areas. The incisors are moderately shovel-shaped.

Sex

Sex is estimated as male based on the robust size of the skeletal elements. The mandible exhibits a squared chin. The femoral head diameter measures 49 mm.

Dentition

The majority of the teeth are present. The maxillary left third molar and the mandibular right first molar are abscessing and may have been lost antemortem (were coded as postmortem loss). The maxillary right third molar has an occlusal caries, the left maxillary left second molar has a distal interproximal root caries, and the mandibular left third molar has a caries on the buccal surface at the CEJ affecting the root. Calculus deposits range from flecks to three-dimensional deposits on the lingual sides of the anterior mandibular dentition. The teeth exhibit slight attrition and three mandibular teeth display chipped enamel including right premolars and left first molar.

Functional Morphology

The fragmentary nature of the bones prevents a thorough analysis of functional morphology. The deltoid muscle attachment on the anterior margin of the clavicle is well demarcated. The pronator quadratus insertions on the ulnae are enlarged and elongated proximally.

Pathology

This individual lacks any degenerative pathology. The spinous process of an upper thoracic exhibits a healed partial fracture. The callus is solidified and reduced.

A localized area of sclerotic bone is present on the posterior distal third of the left tibia shaft. This area may represent a healed mild periostitis (or a greenstick fracture?).

41RF1-BP11-058

This individual is a young adult male of indeterminate ancestry. The skeletal remains are in a very fragmentary state, and the individual is represented by only fragmentary cranial, rib and vertebral elements.

Age

The age is estimated only as a young adult. The fragmentary condition precluded a more precise estimate. The young adult assessment is based on the complete fusion of epiphyseal rings on the vertebral fragments, and the absence of arthritic changes indicates a young adult.

Sex

The only indicator of sex is a rugged fragment of a zygomatic bone. The robusticity of this element suggests male as the sex of the individual.

41RF1-BP11-059

This individual is an infant aged approximately as newborn. The remains are quite fragmentary, however, most of the skeletal elements are present. The deciduous incisors are present in the development stage of root initial and crown $\frac{3}{4}$. These incisors exhibit shovel-shaped morphology. The bone is a brownish gray in color.

Age

Age is estimated based on dental development. The mandibular deciduous first molar is in the cusp initial stage of development that indicates newborn age. The postcranial elements are too fragmentary to be measured, however, these elements appear to be more developed than the dentition suggests.

Burial Feature 12**41RF1-BP12-046**

This fragmentary burial represents the remains of an adult female, aged 30-40 (code 23), of Native American ancestry. Although this burial is a primary interment, the lower half is impacted by the intrusion of Burial 41RF1-BP12-050. The lower limbs and left innominate are disturbed. Only fragments of the lower limbs are present. The bones are light to medium orange brown in color, and plant root damage is evident.

Age

The age estimate is based on the morphology of the auricular surface, dental wear, sternal rib morphology, and general postcranial degenerative bone pathology. The auricular surface is irregular with a deeply entrenched surface and peaked margins. Small islands with fine and coarse-grained textures are present suggestive of Phase 3. The sternal rib ends are quite smooth and are indicative of a young adult, however, the rib ends represent elements of the lower series (7-10), which may affect the age estimate. The dentition is moderately worn with agenesis of the third mandibular left molar. Slight vertebral osteophytosis is evident on the lower lumbar series. These morphological features indicate an age range of 30-40 years.

Ancestry

Ancestry estimate is based on dental morphology and slight platymeria of the proximal right femur. The incisors are slightly shovel-shaped. Overall dental wear is marked with an edge-to-edge pattern. These characteristics are indicative of Native American ancestry.

Sex

Sex is estimated as female based on the gracile and small size of the skeletal elements and the morphology of the innominate. The sciatic notch is wide.

Dentition

The mandible and a majority of the teeth are present. The maxilla is extremely fragmented and only a few fragments of the maxillary alveolus are identifiable. The teeth exhibit moderate attrition, and calculus deposits range from slight to heavy. The left mandibular third molar is absent as a result of agenesis. The maxillary left third molar is hyper-erupted exposing the interproximal region to insult. A large carious lesion is present at the CEJ on the mesial surface. Three right mandibular teeth (canine through second premolar) exhibit unusual labial or occlusal surface abrasions. A distal occlusal surface facet is located on the right canine. The canine facet is aligned with a 3.4 mm long cluster of grooves on the labial (buccal) surface of the right first premolar. The grooves extend from the mesial occlusal margin obliquely across the labial surface of the tooth. The first premolar has a second wear facet on the distal occlusal surface. This wear facet correlates with a 2.6 mm long groove on the buccal surface of the second premolar.

Pathology

Pathological conditions in this individual include vertebral osteophytosis, osteoarthritis, lumbar spondylolysis, and a healed fracture. Vertebral osteophytosis is limited to the lumbar region, and it is probably related to the complete spondylolysis of the fifth lumbar neural arch. The fifth lumbar separation occurs bilaterally along the lamina. The arch coalesces well with the pedicle, and the margin is not actively modeling. This pseudoarthrosis appears quite stable. Osteoarthritic activity is limited to a couple vertebral articulations of ribs and the distal left radius.

The distal radius is fragmented, but moderate marginal lipping is present. The distal ulnar articulation is absent and the carpal display only slight modification. It is possible that the radial osteoarthritis is related to the phalanx fracture. The insults may be associated with the same traumatic episode.

A proximal hand phalanx displays a healed complete fracture of the shaft and proximal articulation. A well-formed vascular canal is evident on the palmar surface. The fracture is healed and both joints appear functional.

Extra Elements

- 1) Infant bones – placed with 41RF1-BP12-050A.

41RF1-BP12-050

This individual is a robust male, aged 40-44 years (code 25), and of possible Native American ancestry. The skeleton is one of the better preserved in this series, however the skull is fragmentary. The bones are an orange brown in color.

Age

The age is estimated using morphological changes in the pubic symphysis and auricular surfaces. The pubic symphysis is consistent with a Todd Phase 8 (40-45 years), and the auricular surface is consistent with Phase 5 (40-44 years). The joint surfaces also are consistent with an age range in the early 40s as degenerative changes are slight. Based on these characteristics, age is estimated as 40-44 years.

Ancestry

Ancestry of this individual is possibly Native American. The postcranial skeleton exhibits the typical morphology of marked robusticity and large joint surface areas. The incisors are moderately shovel-shaped. The proximal femora exhibit slight platymeria. These characteristics are indicative of Native American ancestry. However, the inferior nasal aperture, maxillae, and mandible are more European in morphology. The nasal aperture appears to be relatively narrow with a moderate sill. The anterior maxilla and alveolar region is relatively high. The mandible exhibits a wide or relaxed gonial angle. These features may suggest admixed ancestry.

Sex

The sex of this individual is estimated as male based on pelvic morphology and overall robusticity of the skeleton. The pelvis exhibits narrow greater sciatic notches, and flat auricular surfaces. As mentioned previously, the postcranial skeleton is quite robust. The femoral head diameters measure 49 and 48 mm.

Dentition

All of the teeth are present with the exception of the mandibular left second premolar. All three maxillary left molars exhibit carious lesions interproximally at the CEJ. Calculus deposits range from moderate to heavy.

Numerous teeth exhibit enamel chipping. Effected maxillary teeth include the right second premolar, left first and second premolars. Mandibular teeth with evidence of chipped enamel include the right central incisor, first and second premolars, left central incisor and first molar.

Functional Morphology

This skeleton represents a well-developed robust male. Most of the muscle attachment sites on the postcranial skeleton are moderate to well-developed. Further descriptions are as follows:

The nuchal region is moderately developed.

The left and right clavicles exhibit marked roughening at the attachment for the deltoid muscles.

The right humerus exhibits well-developed attachments for pectoralis major, teres major, and remarkable development of the deltoid tuberosity. The lateral epicondylar ridge is marked for the attachment of the brachioradialis muscle. This muscle serves in rapid flexion and extension of the elbow. The left and right proximal ulnae exhibit evidence of habitual rapid extension and flexion of the elbow. The left proximal ulna has a small region of porosity (scored as osteoarthritis) that may be the result of repeated trauma from hyperextension of the elbow. The right ulna exhibits a rounded notch in the same location. The left distal radius exhibits a marked attachment for the brachioradialis muscle. The ulnae exhibit moderate development for the attachment for the pronator quadratus muscles.

The femora exhibit marked roughening for the gluteal attachments. The proximal femora exhibit slight platymeria. The linea aspera are well-developed. The linea aspera on the left midshaft measure approximately 9.1 mm in width and 2.3 mm in height.

The interosseous crests on the tibiae are moderately marked.

Pathology

A small button osteoma (7.5 mm in diameter) is located in the superior portion of the occipital squamous.

The fifth lumbar vertebra has a healed fracture resulting in a pseudoarthrosis on the right inferior articular facet. This facet also exhibits moderate eburnation on the margin and joint surface. Unfortunately, the corresponding facet on the sacrum is not present.

A left rib exhibits a well-healed complete fracture close to the sternal end.

The majority of the joint surfaces are scored for slight osteoarthritic lipping. The left mandibular condyle exhibits slight erosion.

The right clavicle and right acromial process of the scapula exhibit eburnation from chronic activity of this shoulder.

The left and right patellae have slight to moderate well-healed enthesophytic development.

The left ankle exhibits evidence of a severe sprain. The lateral distal third of the tibial shaft has enthesophytic development as does the corresponding surface on the fibula.

The left and right calcanei have slight to moderate well-healed enthesophytic development on the calcaneus tuberosities.

There is a Staphne's defect on the interior mandibular body.

Extra Elements

- 1) Infant temporal and femur – now 41RF1-BP12-050A.

Burial Feature 13

41RF1-BP13-047

This individual is a very fragmentary partial skeleton representing a young adult, aged 25-35 (code 22). The sex of the individual is difficult to estimate, but based on the general size of the remains of this individual is possibly male. The individual is probably of Native American or Hispanic ancestry based on dental morphology. This may be an individual of several in this series that exhibits evidence of a treponemal infection. The bones are primarily light to medium orange brown in color, but several elements display a brown to brownish gray color. Severe lamellar cracking is associated with these darkly colored areas and plant root damage is evident. The lower half of the burial is missing due to the intrusion of 41RF1-BP13-053. The location of the disturbed elements is unknown.

Age

The age is estimated based on the complete fusion of all visible epiphyses, slight dental attrition, and lack of degenerative changes in the vertebral elements and joint

surfaces. No strong age indicators are present. These limited features indicate an age range of 25-35 years.

Ancestry

Ancestry of this individual is possibly Native American or Hispanic. The central and lateral maxillary incisors are barreled with marked shoveling. These traits are more frequent in Native American populations. The cranial remains are far too fragmentary to access ancestry.

Sex

This individual is probably male. Indicators available are limited to a square mandibular eminence, blunt supraorbital borders, a slight supraorbital torus, and relatively robust distal humerus.

Dentition

The entire dental series is present and in occlusion. The upper and lower first molars and the lateral upper incisors are reduced in size. The upper are barreled shaped with marked shoveling. Numerous hypoplasias are evident throughout the series (see Pathology section). Crowns of the upper left first molar and lower right first molar are completely destroyed due to carious lesions. Large periapical abscesses surround the roots of these teeth. A small periodontal pocket is present between the first and second left mandibular molars.

Functional Morphology

The fragmentary nature of the bones prevents a thorough analysis of functional morphology.

Pathology

General porosity is evident on the cranium. The pitting is restricted to the area between the temporal fascia extending from the posterior frontal squamous to the superior occipital squamous.

The molars are characteristic Moon's molars, which are recognized by their small size in comparison to adjacent teeth and their unusual shape. The cusps are more centrally located on the occlusal surface, and constricted in size. In addition the maxillary and mandibular incisors and canines show reduced occlusal areas, characteristic of Hutchinson's incisors (Jacobi et al. 1992). The crown of the maxillary canine exhibits numerous linear and pit hypoplasias and constriction of the incisal margin. This pattern is present in all the anterior dentition from this individual.

These traits are consistent with clinical and anthropological descriptions of Moon's molars and Hutchinson's incisors, and they are commonly associated with congenital syphilis or endemic treponematoses.

41RF1-BP13-053

This burial represents a female, age 16-18 years (code 19), of possible European or Hispanic ancestry. The skeleton is mostly present but in a fragmentary state. The bone is primarily a yellowish brown in color, however, several of the bones have dark brown staining with cortical splitting. This is typical of bone that has been lying in water for extended periods. Root damage is present on the bones.

Age

The age is estimated based on dental development and skeletal maturation. The mandibular left third molar is at Stage R ½ (code 10) indicating an age of 15.8. However, the mandibular molars are impacted which may delay maturation. The maxillary third molar is at Stage A ½ (apex ½; code 13) indicating an age of 18.25 years.

Other skeletal indicators of age include recent fusion of the distal radial epiphysis, partial union of the iliac crest, and partial union of the cervical rim epiphyses. The distal femora and proximal tibiae epiphyses have fused. These characteristics suggest an age range of 16-18 years.

Ancestry

The ancestry of this individual is possibly European or Hispanic. This assessment is based on the slight shovel shaping on the incisors and round proximal femur. The left distal tibia has a small squatting facet, but the right is not available for analysis.

Sex

Sex is estimated as female based on the very gracile nature of the postcranial skeleton. Femoral head diameter measures 44 mm, which suggests female.

Dentition

The dentition of this individual is in good condition. The calculus deposits range from flecks to coalesced. The mandibular first molars exhibit pit caries on the occlusal surfaces, and the left mandibular second molar has a pit caries on the buccal surface. The left maxillary second premolar exhibits a periodontal pocket on the buccal side. This tooth is mal-aligned and has drifted lingually. The

pocket encompasses the areas between the first premolar and first molar.

Functional Morphology

The humeri exhibit moderate development of the deltoid tuberosities.

The proximal ulnae are unusual in morphology. The olecranon is not proportionally as wide (23 mm) in comparison to the minimum olecranon breadth (22 mm). The left distal ulna exhibits moderate development of the pronator quadratus attachment. The interosseous crests on the ulnae are squared in shape instead sharp.

The distal left tibia exhibits a small squatting facet.

41RF1-BP13-057

From a Sort

This fragmentary skeleton represents a young adult male, aged 25-35 (code 22), of possible Hispanic ancestry. The bones are light to medium brown in color, and plant root damage is evident. The remains consist of disarticulated elements that were scattered around the lower limbs of 41RF1-BP13-053. These remains represent a minimum of two individuals, and this burial represents the most complete individual sorted from the mixed elements. The remaining elements were given ossuary codes.

Age

The estimated age is based on the complete fusion of all available epiphyses including the medial clavicle. Dental attrition is slight and the third molar roots are completely formed. Slight osteoarthritis is evident on a thoracic vertebra and the distal femora. These limited features indicate an age range of 25-35 years.

Ancestry

Ancestry of this individual appears mixed or possibly Hispanic. The criteria for this assessment are weak. The postcranial skeleton exhibits a robust morphology but the overall size is small. The central upper incisor is not shovel-shaped, but the lateral are slightly barrel-shaped with are moderately shovel-shaped. These characteristics are indicative of mixed ancestry.

Sex

Sex is estimated as male based on the robustness of the skeletal elements. In general, the overall size of this individual

is intermediate. The maximum diameter of the femoral head is 44 mm.

Dentition

The maxillary dentition is nearly complete. The anterior teeth are represented from the mandibular series. Tooth wear is light with only small occlusal facets evident on the third molars. Calculus deposits range from moderate to three dimensional. No carious lesions are present, but periodontal resorption is evident on the upper anterior teeth from right canine to the first left premolar. The wear pattern on the upper anterior teeth is unusual, especially on the lateral incisors. These patterns may relate to a functional use of these teeth.

Pathology

General porosity is present on the ectocranial surface of the parietals and occipital. The pitting encompasses the region between the temporal fascia of the parietals and to the nuchal line of the occipital. A small osteophyte is present on the anterior margin of the tenth thoracic vertebra. Mild osteoarthritic lipping is present on the distal left femur.

Burial Feature 14

This burial feature has multiple individuals most of them are commingled. The primary burial of the child, 41RF1-BP14-051, is the only burial in this feature that is not commingled.

41RF1-BP14-049

From a Sort

This individual is an infant aged 1.5-2.5 years (code 03) of indeterminate sex and ancestry represented by a fragmentary and incomplete skeleton. A left femur, left tibia, right clavicle, and one right rib, represents the postcranial skeleton. None of these bones is complete.

Age

Age estimation of this individual is estimated as 1.5-2.5 years based on the size of the postcranial elements and petrous portions of the temporal bones. This individual is larger than 41RF1-BP14-063A. The deciduous right maxillary lateral incisor exhibits approximately ½ of its root development.

Pathology

The frontal and temporals are scored for mild active ectocranial porosis. The left tibia exhibits an active region of periostitis.

Extra Elements

- 1) Numerous fragments from adult bones as well as phalanges and carpals.

41RF1-BP14-051

This individual is a child, aged 2.5-3.5 years, possibly of Native American ancestry. The skeleton is mostly present and moderately intact. The bone is a light to medium brown in color.

Age

The age is estimated using dental and long bone development. The dentition is mostly complete which allows for a really good age estimate. The age ranges provided by the dental development are 2.4 (mandibular deciduous second molar) to 3.8 years (permanent mandibular second molar).

The right ulna measures 132 mm, and the left femur measures 199 mm in length. The ages provided in Ubelaker (1989) for these bones are 2.5-3.5 (femur) and 3.5-4.5 (ulna). Based on the dentition and long bone development, age is estimated as 2.5-3.5 years.

Ancestry

Ancestry is tentatively assessed as Native American based on the maxillary permanent central incisor shovel shape.

Dentition

The deciduous and permanent dental series are well represented. Numerous caries are present. Small mesial interproximal lesions are evident in the deciduous maxillary central incisors. Small occlusal pit caries are present on the right first and second deciduous molars, and a moderate defect is present on the occlusal surface of the first left deciduous molar.

Pathology

The postcranial skeleton is free of pathological changes. The cranial vault exhibits several areas of pathological changes. The posterior parietals exhibit porotic hyperostosis.

The right posterior parietal along the lambdoidal suture approximately 40 mm lateral of lambda exhibits an area of porosity that measures roughly 18 mm anterior-posterior (a-p) and a minimum of 16 mm medial-lateral (m-l). A more accurate measure of the breadth is prevented due to postmortem breakage. The left posterior parietal adjacent to asterion also exhibits a small region of thickening and

porosity typical of porotic hyperostosis. This area measures approximately 14 mm by 13 mm. The left temporal exhibits slight widespread ectocranial porosis.

41RF1-BP14-056

From a Sort

This individual is a male, aged 30-34 years (code 23) of Native American ancestry. This burial was a secondary burial being disturbed at a minimum by 41RF1-BP14-051 and finally by the pipe trench. The burial is commingled with the postcranial remains we identify as 41RF1-BP14-063. Both of these individuals are robust young adult males. This burial is identified as the larger of the two, and the sort is based on the slight differences in robusticity. The bone is an orange brown in color and is fragmentary. Root damage is evident, and rust colored staining is present on the left mandibular ramus. This is most likely from contact with the intrusive pipe.

Age

Age estimation is based on the morphology of the auricular surface on the left innominate, which is consistent with a Phase 3 to 4 suggesting an age range of 30-39 years. However, the remaining skeleton exhibits little arthritic change. Based on this evidence, age is estimated as 30-34 years.

Ancestry

Ancestry estimation of this individual is as Native American is based on the overall robusticity, shovel-shaped incisors, and squatting facets on the tibia. The nasal spine is sharp, and the maxillae exhibit prognathism.

Sex

Sex is estimated as male based on the robusticity of the skeletal elements. The cranial elements reveal a marked temporal line, and the mandible is large and squared. The postcranial fragments show a robust build. Femoral head diameter measures 49 mm. These features indicate a male.

Dentition

The teeth are relatively healthy. The mandibular second molars exhibit enamel extensions on the buccal surfaces. Calculus deposits range from moderate to three dimensional. Enamel chipping is present. Maxillary teeth exhibiting the enamel chipping include the right premolars, canine, incisors, left incisors, canine, and first premolar. Mandibular teeth that show enamel chipping include the right first molar and

the left first premolar. Agenesis of the left mandibular lateral incisor is evident.

Functional Morphology

The fragmentary cranial vault exhibits moderate development of the temporal line on the frontal. The right proximal humerus exhibits moderate development of the attachment for the pectoralis major and the latissimus dorsi. The left distal humerus has a well-developed epicondylar ridge.

The proximal ulnae have atypical notches on the medial side of the coronoid process. The right side is more pronounced than the left. The distal ulna exhibits moderate development of the pronator quadratus attachment.

The femur exhibits a roughened linea aspera.

The left distal tibia exhibits a moderate squatting facet. The tibiae exhibit marked development of the soleal line for the attachment of the soleus muscle, and the fibulae show corresponding enlargement of the attachments for the same muscle. The soleus muscle plantar flexes the foot.

Pathology

The right proximal ulna exhibits slight osteoarthritic lipping.

The left fibula has a small localized healed periostitis on the middle third shaft.

Extra Elements

- 1) Group 1 – Radius, ulna, ribs, vertebra, metacarpal or metatarsal aged approximately 0.5-1.0 year.
- 2) Group 2 – Fibulae, phalanges, ribs, crania of a newborn aged infant – these became 41RF1-BP14-056A.

41RF1-BP14-063

From a Sort

This individual is a male, aged 23-30 years (code 23) of Native American ancestry. Two other burials and a historic pipe trench disturbed this burial. Burial 41RF1-BP14-056 initially disturbed this burial. 41RF1-BP14-051 then disturbed 41RF1-BP14-056, and finally a pipe trench bisected the entire burial feature. The burial is commingled with the postcranial remains we identify as 41RF1-BP14-056. These two individuals are robust young adult males. This individual represents the less robust elements in the collection. Sorting of the ribs and vertebrae is more arbitrary than the long

bone assessments. The bone is orange brown in color and fragmentary. Plant root damage is evident.

Age

Age estimation is based on degree of epiphyseal closure and development of slight osteoarthritic lipping in the lipping in the lower limb joints. Dental attrition is slight. All primary age indicators of the pelvis and cranium are absent. Based on this limited evidence, age is estimated as 23-30 years.

Ancestry

Ancestry estimation of this individual as Native American is based on the overall robusticity, shovel-shaped incisors, and squatting facets on the talus.

Sex

The sex estimate is male based on the overall robust size of the postcranial elements, the perpendicular angle of the mandibular ramus, and size of the femoral head (48 mm).

Dentition

The cranium and maxilla are absent, but three maxillary teeth are present. The upper lateral incisor displays a well-formed lingual shovel morphology, and the lower lateral incisors exhibit slight shoveling. The teeth are relatively healthy. Two small occlusal pit caries are present in two molars, left maxillary second and left mandibular third. Interproximal grooves are present on the mesial lingual surface of the second maxillary molar and the mesiobuccal surface of the mandibular right third molar. Several teeth exhibit enamel chipping including the maxillary left second premolar, right mandibular first premolar, canine, lateral incisor, and left mandibular lateral incisor. The molars exhibit enamel extensions on the buccal surfaces. Calculus deposits range from moderate to coalesced.

Functional Morphology

The distal humeri have well-developed epicondylar ridges. The distal posterior radii exhibit pronounced ridges for the attachment of the brachioradialis muscle. The brachioradialis serves as a lower arm flexor and stabilizer.

The proximal fibulae exhibit moderate development of the soleal attachment line.

The left superior talus exhibits a small squatting facet. The distal tibia articulation is damaged at this location.

Pathology

The right distal femur exhibits slight osteoarthritic lipping along the interior margin of the medial condyle. Os acromiale is evident bilaterally. The left ossicle is present and the right scapular spine is present.

Extra Elements

- 1) Group 1 – Two maxillary teeth (a central incisor and third left maxillary molar) are present. Both elements are from an older adult.

41RF1-BP14-063A

From a Sort

This individual is an infant aged 0.5-1.5 years of indeterminate sex and ancestry represented by a fragmentary and incomplete skeleton. The postcranial skeleton is represented by the left and right femora and two right ribs. None of these bones are complete.

Age

Age estimation of this individual is estimated as 0.5-1.5 years (code 02) based on the size of the postcranial elements and thin cranial fragments.

Pathology

The middle third shaft of the left femur exhibits a region of active periostitis.

Both femora exhibit increased roughening on the posterior surface where the gluteal muscles attach.

Burial Feature 15

Burial Feature 15 is located in the northwestern corner of the burial concentration. Trenching for a pipeline and posthole excavation disturbed the feature. Originally, three burials were identified 41RF1-BP15-048, 41RF1-BP15-052, and 41RF1-BP15-081. Burial 48 was partially disturbed, and Burial 52 was *in situ*. Numerous commingled elements were recovered above Burial 52, and these were identified as Burial 48. These disturbed remains represent at least two additional individuals, 41RF1-BP15-048A and 41RF1-BP15-048B. The final burial is 41RF1-BP15-081, which consists of a series of disturbed elements clustered together on the northern end of the feature.

41RF1-BP15-048**From a Sort**

This individual is an adult male, age 30-34 years (code 23), of Native American ancestry. The individual consists of the *in situ* remains located in the northern half of Burial Feature 15. The skeletal material is in good condition and most elements are complete. Bone color ranges from yellow to light brown, and plant root damage is evident. Green staining from a small copper medallion is present on the posterior superior border of the left scapula and first, second, and third ribs. These stains are located on the inferior visceral surface of the ribs.

Age

The age estimate of this individual is based on the available pelvic indicators, the degree of osteoarthritic activity, and dental attrition. The pubic symphysis morphology is classified as a Todd Stage 5 and a Suchey-Brooks Phase 4. The auricular surface morphology is consistent with Phase 3. Slight osteoarthritic activity is evident on the distal right femur and the distal left radius. These characteristics are consistent with an individual between 30 and 34 years.

Ancestry

Ancestry is estimated as Native American. The overall postcranial morphology is robust. The proximal femoral shafts display moderate platymeria (Index L = 79 and R = 81). A small squatting facet is evident on the anterior margin of the distal articular surface of the left tibia. The lack of cranial material precludes the use of cranial metrics, cranial morphology, or dental morphology.

Sex

This individual is classified as male. The pubic symphysis morphology is indicative of male with triangular shape, slight subpubic angle, and no ventral arc. The overall size of this individual is small, but the bones are robust. The femoral head and vertical diameter of the humerus head measure 45 mm and 44 mm, respectively.

Functional Morphology

The palmar surfaces of the phalanges display well-developed flexor tendon and tendon sheath attachments.

The femora display marked gluteal insertions and well-developed linea aspera (left width at midshaft is 8 mm, height is 5 mm, and right width is 7 mm, height is 6 mm). The length of the lateral condyle of the proximal left tibia is reduced as compared to the medial condyle. The valgus angle of left

femur is more direct than the right side. Loading of the femur on the tibia would have been reduced on the lateral condyle possibly resulting in a reduced lateral condyle. Slight squatting facets are present on the tibia as a result of repetitive flexion of the ankle.

Pathology

Two upper thoracic vertebrae, possibly the 2nd and 3rd, are ankylosed along the neural arches and articular facets. A short section of the posterior margin of these centra were fused, however these have broken apart due to post-depositional damage.

The midshaft of the left clavicle exhibits a complete healed fracture. The fracture margins overlap slightly with moderate reduction in clavicle length. The fracture area is delimited by sclerotic and porous bone. A vascular canal is evident along the medial margin of the reduced callus. The medial attachment site of the deltoid muscle has shifted to the inferior margin of the clavicle shaft.

Slight marginal osteoarthritic activity is evident on the distal right femur and the distal left radius articulations.

Extra Elements

- 1) Two rib sections and a neural arch of a vertebra from an infant were found with the remains.

41RF1-BP15-048A**From a Sort**

This individual is a young male, age 9.5-10.5 (code 11) of unknown ancestry. The individual was assembled from a sort from elements located in 41RF1-BP15-048. This disturbed burial consists of a mandible with several teeth, long bone elements, several ribs, several vertebrae, sternal elements, a right scapula, and a right innominate. The general color of bone is yellow to brown, and plant root damage is marked.

Age

Dental development and epiphyseal union are employed in the age estimation. The deciduous mandibular second molars are still in occlusion. The permanent mandibular second molars roots are $\frac{3}{4}$ complete and the mandibular third molar crowns are half complete. The roots of the first premolars and canines are $\frac{3}{4}$ complete. This pattern of dental development correlates to an age range between 9.5 to 10.5 years. The epiphyses of all major appendicular elements are unfused, and the ilium-ischium suture within the acetabulum was unfused.

Sex

Sex was determined by the pronounced mental eminence and large teeth present in this individual. Although still relatively young, the pubic bone also lacked a subpubic concavity.

Dentition

The dentition for this individual consists of mandibular dentition only. The wear pattern is light for the incisors and the permanent first molars. The deciduous first molar is moderately worn. There is heavy calculus on the deciduous right first molar and the permanent left first molar. Slight staining is evident on the central permanent incisor. The left mandibular first molar exhibits chipped enamel.

Functional Morphology

For the young age of the individual, there are marked sites of attachments for latissimus dorsi and pectoralis major muscles along the shaft of the humerus.

41RF1-BP15-048B**From a Sort**

This individual is a adult female, age 25-34 years, of unknown ancestry. The individual was assembled from a sort of elements identified as 41RF1-BP15-048. This individual consists of portions of the right appendicular skeleton. These elements are the same bones that are missing from 41RF1-BP15-048, but they are more gracile and appear slightly younger than that individual. The general color of bone is yellow to brown, and plant root damage is quite marked.

Age

The age estimate is based on the available pelvic indicators and epiphyseal closure. The auricular surface morphology is consistent with Phase 2 or 3. The medial clavicle epiphysis is complete fused, and no osteoarthritic activity is evident. These characteristics are consistent with an individual between 25 and 34 years.

Sex

The sex estimate is based on the relative size of this individual and the morphology of the innominate. The skeletal elements are gracile and display slight to moderate muscle attachment sites. The sciatic notch is moderately wide. These characteristics are consistent with a female individual.

Functional Morphology

The insertion of the deltoid muscle along the lateral anterior margin of the clavicle is marked.

41RF1-BP15-052

This individual is a very gracile female, aged 19-22 years (code 21) of mixed ancestry (Native American/Hispanic). The remains represent an extended primary interment with the arm crossed on the chest. Numerous elements are scattered on top of the burial, and these remains represent portions of 41RF1-BP15-048, 41RF1-BP15-048A, and 41RF1-BP15-048B. The bone is in good condition. The articular ends of the major long bones are damaged, and the diaphyses are crushed. The bone is uniformly light brown to yellowish brown in color, and most elements exhibit root damage.

Age

The age is estimated based on dental development and skeletal maturation. The dental remains are completely formed and slight attrition is evident on the third molars. The medial clavicle is unfused and the epiphyseal rings of the lumbar and thoracic vertebrae are actively fusing. All major epiphyses of the appendicular skeleton are fused. These traits are consistent with an individual from 19 to 22 years old.

Ancestry

This individual is estimated as deriving from mixed descent. The postcranial skeleton is extremely gracile. The femora display slight platymeria. The incisors exhibit slight shoveling, and the mandibular body is robust. The overall size of the postcranial skeleton is consistent with a Hispanic or Mesoamerican individual. The mandible size and tooth morphology suggests an individual of Native American descent.

Sex

This individual is a small gracile female. The postcranial skeleton represents a very small adult. The clavicles and upper limbs are extremely small. The mastoid processes are small, and the nuchal region is not well marked. The gonial angle is 135°. These traits are consistent with a female individual.

Dentition

The dentition is well represented. The maxillary alveolus is fragmentary, but the mandible is in fair condition. Overall, tooth size is small. The lateral maxillary incisors are peg-shaped and greatly reduced in size. Calculus ranges from

flecks to moderate deposits. Large buccal pit lesions are present in the right first and third mandibular molars and the left third mandibular molar. Occlusal lesions are evident in the mandibular left second molar and the mandibular left first premolar. The mandibular left first molar is missing antemortem with the socket completely resorbed. Attrition on the anterior is slight to moderate. The left mandibular premolars exhibit enamel chipping. Linear enamel hypoplasias are evident.

Functional Morphology

The muscle attachment sites of the arms and legs are defined but not well-developed. No vertebral pathology or osteoarthritic activity was evident.

Pathology

Bilateral mild periostitis is evident on the anterior surface of the maxilla directly superior to the alveolus and surrounding the infraorbital foramen. This reaction is probably related to active bilateral sinusitis present in the atria. The right atrium, which is complete, exhibits uniform bone development on the entire sinus surface. No dental fistulae are evident, but the severe dental caries in the mandibular series may have contributed to this condition.

Extra Elements

- 1) Group 1 – Two teeth (a lower right canine and a first left maxillary molar) are present. Both teeth are from an older adult.

41RF1-BP15-081

This individual is an adult, probably over 35 years old, of unknown ancestry. The individual consists of elements recovered in Burial Feature 15, north of Burial 41RF1-BP15-048. Elements recovered include a complete right ulna, the shaft and distal articulation of the right radius, several rib fragments, a right maxilla fragment, two vertebral fragments, and a mandibular premolar. These elements could not be associated with 41RF1-BP15-052 or 41RF1-BP15-048. The general color of bone is light brown, and plant root damage is evident.

Age

The age estimate of this individual is based on epiphyseal closure and dental attrition. The proximal and distal epiphyses of the radius and ulna are fused, and the premolar displays marked occlusal wear. Mild osteoarthritic lipping is evident on the costal articulation of the transverse processes of the thoracic vertebrae. These characteristics are consistent with an individual over 35 years old.

Sex

This individual is probably male. The sex estimate is based on the relative size of this individual. The skeletal elements are robust and display moderate muscle attachment sites. These characteristics are consistent with a male individual, but observations are limited.

Dentition

The right mandibular right first premolar is moderately worn, and displays no pathological lesions. A small interproximal groove is evident on the distal margin at the CEJ.

Functional Morphology

The insertion of the deltoid muscle along the lateral anterior margin of the clavicle is marked.

Pathology

Moderate to severe osteoarthritic lipping and porosity is evident on the distal articulations of the right radius and ulna. The radius displays moderate marginal lipping with severe surface porosity and eburnation. The distal ulna exhibits moderate lipping and slight eburnation. This pathology may be trauma related, but the corresponding carpals are missing.

Burial Feature 16

This burial feature includes the commingled remains of a minimum of five cremated individuals with the remains of non-cremated commingled individuals. A minimum of five individuals is represented in the commingled cremated remains. Several bags of burned fragments were not associated with an individual burial and were left unsorted (total weight of 1,720 grams).

41RF1-BP16-CRE1

From a Sort

This individual is a very gracile young adult female, age 25-34 years, of indeterminate ancestry. This individual represents an extremely fragmented cremation that was scattered above a series of primary burials. These elements were sorted from a concentration of burned human bone. Elements identified as this individual are completely calcined and were easily separated from the other burned materials. This individual displays a white to yellowish white surface color. Internal coloration ranges from white to a light gray. The degree of calcination suggests that the heat source was quite intense ($> 900^{\circ}\text{C}$) and long in duration. Numerous longitudinal and *thumbnail* fractures are evident in these

remains. These fractures suggest that soft tissue was present prior to burning.

Age

The age estimate is based on the complete fusion of observable epiphyses on the tibia, fibula, and vertebrae. The sagittal and coronal cranial sutures are completely open. The cortical bone is thick and the cancellous bone is well established. The available joint surfaces and vertebral centra lack osteoarthritic development. These characteristics correlate to a young adult ranging in age from 25 to 34 years.

Sex

Sex for this individual is based upon general size of the cranial and postcranial skeleton. The mandibular condyle, proximal ulna, distal radius and distal tibia articulations are very gracile.

Functional Morphology

A small squatting facet is present on the right distal tibia articular surface.

The bone mass of this individual is 290 grams, which is far less than would be expected if the entire skeleton was represented. A small percentage of the cranial and axial skeleton is present. The appendicular skeleton is represented by numerous long bone shaft fragments, but most of the anatomically diagnostic fragments and articular surfaces are missing.

Taphonomy

Represented elements include fragments of the cranial vault, mandible, long bone shafts, vertebrae, hands and feet. The cranial vault fragments display open sutures fragments with marked meningeal grooves. The mandible is represented by two inferior ramus fragments and the mandibular left condyle. One premolar tooth root is present. The other teeth and alveolar structures are absent.

Identified vertebral elements include the a fragment of the atlas, odontoid process of the axis, five cervical and thoracic centra, three lumbar neural arch fragments, and a portion of the sacral promontory. Identified pectoral girdle elements include the right scapula body and glenoid fossa, the proximal right ulna articulation, the left distal radius articular surface, several metacarpal shafts, a left capitate and two phalanges. The lower limb is represented by numerous long bone shaft fragments of the femora and tibiae, distal articulations of the right tibia and fibula, and fragments of the tarsals and metatarsals. All the elements are completely calcined.

The bones display a consistent pattern of complete burning. Bone color varies from white to yellowish white (Munsell Color Chart 2.5Y 8/1 to 2.5Y 8/2) on the exterior with a few elements exhibiting gray coloration on the interior (2.5Y 6/1). Several fragments have a vitreous, or porcelain, texture indicating an extended exposure to an intense heat source.

The long bone shaft fragments are relatively consistent in size and dimension. Shafts have splintered longitudinally and along transverse heat fractures. The larger shaft fragments range in size from 30 to 60 mm in length and 5 to 16 mm in width. Table IIA-3 provides a summary of the shaft fragment measurements from a sample of the larger elements. The severe fragmentation evident in this individual is expected given the degree of burning.

Table IIA-3. Sample of postcranial fragment dimensions from 41RF1-BP16-CRE1

Element	Length (mm)	Width (mm)
Radius shaft fragment	37	13
Fibula shaft fragment	37	14
Fibula shaft fragment	49	12
Fibula shaft fragment	29	13
Long bone shaft fragment	44	16
Long bone shaft fragment	45	15
Long bone shaft fragment	61	9
Long bone shaft fragment	53	6
Long bone shaft fragment	37	12
Long bone shaft fragment	42	14
Long bone shaft fragment	37	12
Long bone shaft fragment	53	10

41RF1-BP16-CRE2

From a Sort

This individual is female aged 30-39 (code 23) years of indeterminate ancestry represented by cremated very fragmentary remains (Table IIA-4). The identified fragments for this individual combine for a total weight of 569 grams. The bone fragments range in color from dark greys to brown to white on the cortical surfaces, and the inside is charred mostly black. This cremation was burned separately from the other cremated remains.

Table IIA-4. Sample of cranial and postcranial fragment dimensions from 41RF1-BP16-CRE2

Bone	Length (mm)	Width/Diam (mm)
Cranial fragment	29	25
Cranial fragment	21	12
Cranial fragment	49	25
Radius shaft fragment	31	12
Radius shaft fragment	21	12
Radius distal fragment	36	24
Femur shaft fragment	67	23
Femur shaft fragment	38	18
Femur shaft fragment	37	20
Femur shaft fragment	37	19
Femur shaft fragment	43	17
Tibial shaft fragment	50	11
Tibial shaft fragment	34	19
Tibial shaft fragment	31	16
Tibial shaft fragment	30	15
Tibial shaft fragment	28	17

Age

The age is based on the dense bones, solid cortical bone and slight lipping on the finger phalanx. Small segments of the cranial sutures are present and open.

Sex

The mandibular condyle is small, and the distal radius is small and gracile. These features are characteristic of females.

Taphonomy

All pieces of this individual are burned. The bones show a fairly consistent pattern of burning which suggests that this individual was fleshed at the time of cremation. The bones vary in color from black to gray to whitish gray, and in a few instances to a whitish color from beginning calcination. Most of the fragments are black to gray in color (Munsell Color Chart codes ranges from N8/ to N3/). Those pieces that are more extensively burned include the fragments of the cranium such as the frontal and parietals. Many of these burned elements are also characterized by speckled discoloration. On several of the fragments, the cortical surfaces exhibit transverse fracturing from the intense heat. The level of burning is such that extensive fragmentation has occurred.

Identifiable elements include the following:

Cranial Elements

- 1) A minimum of 78 cranial fragments including frontal and parietals and fragments of the left and right petrous temporals.
- 2) Fragment of the right mandibular condyle.

Postcranial Elements

- 1) Fragments of the 1st and 2nd cervical vertebrae.
- 2) Fragments of the left and right glenoid fossae.
- 3) Fragments of the right radius.
- 4) Fragments of the humerus.
- 5) Fragments of the femora, tibia, and fibula.
- 6) 2 hand phalanges and 1 tarsal.

41RF1-BP16-CRE3**From a Sort**

This individual is a male aged 22-30 (code 22), of indeterminate ancestry, represented by highly fragmentary cremated skeletal remains (1,123 grams of burned bones; Tables IIA-5 and IIA-6).

Age

Age is based on open cranial sutures, lack of osteoarthritis, dense smooth cortical bone, and lack of dental pathology of the tooth sockets present. The bone fragments have smooth cortical surfaces and moderately compact cancellous bone as is characteristic of young adults.

Sex

The size of the distal segment of the right humerus, the humeral head, thickness of the cortical bone of the long bones, identify this individual as male. The linea aspera is moderately defined.

Taphonomy

All pieces of this individual are burned. The bones show a fairly consistent pattern of burning. The bones vary in color from black to brownish gray to gray, and in a few instances to a whitish color from beginning calcination. Most of the fragments are black to gray in color. Those pieces that are more extensively burned include the fragments of the cranium such as the frontal and occipitals. Many of these elements are also characterized by speckled discoloration.

The degree of burning is not as extensive nor as intensive as that seen in 41RF1-BP16-CRE1. The degree of burning

has not resulted in transverse fracturing, not is the degree of burning sufficient to explain the degree of fragmentation.

The following is an inventory of identifiable fragments:

Cranial Elements

A number of cranial fragments including the following:

- 1) The left lateral supraorbital region and zygomatic process of the frontal bone.
- 2) The central portion of the occipital squamous.
- 3) Four small fragments of maxillary and mandibular alveolar bone.
- 4) The frontal bone superior to nasion including part of the frontal crest and sinus.
- 5) One premolar root.
- 6) Fragments of the left and right petrous temporals.
- 7) The right temporal superior to the mastoid process.
- 8) Mandibular symphysis, which is represented by two adjoining pieces containing the empty sockets of mandibular incisors and right canine.
- 9) Left ascending ramus adjacent to the mandibular condyle

Postcranial Elements

- 1) Fragment of the dens epistropheus of the second cervical vertebra.
- 2) Fragment of a cervical vertebra with a superior and inferior facet.
- 3) Incomplete neural arch of a thoracic vertebra.
- 4) Fragments of the humerus with one of the largest pieces being a section of the distal diaphysis of the right humerus.
- 5) Fragments of the left and right humeral heads.
- 6) Fragment of a distal right humerus joint surface.
- 7) Fragment of the acromial process of the scapula.
- 8) Fragment the ilium showing complete fusion of the iliac crest.
- 9) Two partial hand phalanges.
- 10) Partial third left metacarpal.
- 11) Fragment of a greater sciatic notch.
- 12) Fragments of the femora, tibiae, and fibula. Each of these pieces represents $\frac{1}{2}$ or less of the circumference of the bone represented by that section.
- 13) Fragments of the proximal and right distal femoral joint surfaces.
- 14) The distal joint surfaces of the tibiae.
- 15) An incomplete right talus.
- 16) Partial right first metatarsal.

Table IIA-5. Sample of cranial fragment dimensions from 41RF1-BP16-CRE3

Cranial Element	Max. length	Min. Length
Mandibular symphysis	31 (height)	26 (width)
Frontal fragment	37	23
Frontal fragment	33	27
Parietal fragment	38	30
Parietal fragment	34	25
Parietal fragment	37	25
Parietal fragment	35	29
Parietal fragment	28	23

Table IIA-6. Sample of postcranial fragment dimensions from 41RF1-BP16-CRE3

Element	Length (mm)	Width/Diam (mm)
Humerus distal fragment	78	29
Humerus fragment	42	19
Humerus fragment	35	18
Humerus fragment	23	21
Femur shaft fragment	90	26
Femur shaft fragment	65	29
Femur shaft fragment	61	30
Femur shaft fragment	57	19
Femur shaft fragment	47	28
Femur shaft fragment	45	25
Femur shaft fragment	50	22
Femur shaft fragment	51	25
Femur shaft fragment	46	21
Femur shaft fragment	46	21
Femur shaft fragment	48	25
Femur shaft fragment	44	25
Tibial shaft fragment*	45	17
Tibial shaft fragment	44	16
Tibial shaft fragment	46	15
Tibial shaft fragment	46	15
Tibial shaft fragment	34	28
Tibial shaft fragment	26	18
Tibial shaft fragment	18	17
Tibial shaft fragment	22	15

*Tibial shaft fragments are primarily from the anterior tibial crest.

41RF1-BP16-CRE4**From a Sort**

This individual is a male aged 25-39 (code 23) represented by a very incomplete cremated skeleton. These elements show blackening from charring along with unburned sections of the bone. Several elements exhibit a light gray color suggesting partial calcination.

Age

These remains represent a young adult. The humeral head, distal radius and vertebral centra epiphyses are fully united. No arthritic lipping is evident on the joint surfaces. The bones have moderate cancellous bone spacing, not as compact as in CRE3, suggesting that this individual is a little older.

Sex

Sex is estimated as male based on size of the proximal and distal humeri.

Taphonomy

The elements are extremely fragmented and only a limited number of elements could be identified (Table IIA-7). The entire sample weighs 220 grams. Recognized elements include distal right humerus diaphysis, a partial humeral head, distal left humerus joint surface and metaphysis, distal left radius joint surface, proximal ulna fragment, portions of each talus, a lower thoracic vertebra fragment, and the cancellous structure of a femoral head. Several long bone shaft fragments are present, but cranial elements are missing.

Table IIA-7. Sample of postcranial fragment dimensions from 41RF1-BP16-CRE4

Element	Length (mm)	Width/Diam (mm)
Humerus distal fragment (partially burned)	70	35
Humerus distal fragment (burned)	39	27
Humerus head fragment	45	29
Radius distal articulation	30	15
Ulna shaft fragment	47	13
Femur head fragment	42	23
Femur shaft fragment	40	20
Long bone shaft fragment	45	13
Long bone shaft fragment	49	9

No cranial fragments from the commingled sample match the burning pattern of the postcranial elements identified as this individual. It is possible that the cranium of this individual is not burned given that portions of the distal humerus and proximal ulna display only partial burning.

The pattern of burning of these fragments indicates postmortem burning after decomposition had occurred. The intensity of burning is much less severe such that most elements are only blackened and charred (Munsell color: N2.5). The pattern of burning within elements is not consistent with a fleshed cremation. For example, the cancellous structure of the femoral head displays a gray color (10Y 4/1) whereas the neck is only blackened. If the femoral head had been in the acetabulum at the time of burning it would show less heat modification than the neck. Another example is the internal trabeculae of the humeral head exhibits a gray color whereas the articular surface ranges from a black to a tan color indicating less heat damage.

41RF1-BP16-CRE5**From a Sort**

This individual is a gracile young adult female, age 25 to 34 years (code 22), of indeterminate ancestry. Elements identified as this individual are smoked/blackened to partially calcined. The bone color varies from a smooth black to dark gray to pale yellow color (Munsell Color N 2.5 to 10YR 4/1 to 5Y 8/3). These elements were separated from the other burned materials based on surface texture, color, and general size.

Age

The age estimate is based on the complete fusion of an observable epiphysis on the radius and well-developed cortical thickness of the femora. The sagittal and superior coronal sutures are completely open, but the inferior coronal suture is partially fused. The cortical bone is thick, and cancellous density within the talus is moderate to dense. These characteristics correlate to a young adult ranging in age from 25 to 34 years.

Sex

Sex for this individual is based upon general size of the cranial and postcranial skeleton. The cranial and femoral thickness, talus dimensions and distal radius size are fairly gracile.

Taphonomy

Represented elements include fragments of the cranial vault, long bone shaft sections, clavicle shaft, rib fragment, and a

right talus. The cranial vault fragments display open sutures fragments with slight meningeal grooves. Several parietal fragments exhibit diffuse ectocranial porosity. The occipital protuberance is present. The external occipital surface displays slight nuchal development. A humerus, radius and femur are represented by shaft fragments. The anterior half of the distal right radius articular surface is present. The right talus is small, but missing the posterior half.

Bone fragments from this individual weight 177 gm, which is far less than would be expected if the entire skeleton was represented. Postcranial and cranial elements are both poorly represented. Two postcranial elements refit together, and three cranial elements refit. The surface texture of the long bone shaft fragments is smooth and appears polished.

The long bone shaft and cranial fragments are relatively consistent in size and dimension. Shafts have broken longitudinally, but lack transverse heat fractures. The larger shaft fragments range in size from 30 to 70 mm in length and 12 to 16 mm in width. Table IIA-8 provides a summary of the shaft fragment measurements from a sample of the larger elements. The severe fragmentation evident in this individual is expected given the degree of burning.

Table IIA-8. Sample of postcranial fragment dimensions from 41RF1-BP16-CRE5

Element	Length (mm)	Width (mm)
Parietal fragment	60	26
Frontal fragment	54	50
Occipital fragment	49	37
Parietal fragment	31	40
Parietal fragment	34	31
Humerus shaft fragment	49	16
Humerus shaft fragment	48	15
Femur shaft fragment	69	17
Long bone shaft fragment	47	15
Long bone shaft fragment	46	13
Long bone shaft fragment	40	12
Radius shaft fragment	33	15

41RF1-BP16-060

From a Sort

This individual is a male aged 25-34 (code 22) of unknown ancestry. The skeleton is in a very fragmentary condition. This sort was based on the color, robusticity, and age of the bone. The bone is a light brown in color. Fragmentary vault bones and few facial bones represent the skull. No dentition is associated with this individual.

Age

Age estimation of this individual is based on small portions of the left pubic symphysis and right auricular surface. The pubic symphysis morphology is consistent with a Todd Phase 6, which indicates an age range of approximately 30-35 years. The morphology of the auricular surface is consistent with a Lovejoy Phase 2-3 which suggests an age range of 25-35 years. Osteoarthritic changes are slight supporting the younger end of the suggested ranges.

Sex

Sex is estimated based on the robustness of the elements.

Functional Morphology

The right clavicle exhibits marked attachment for the deltoid muscle. The lateral epicondylar ridge of the left humerus is marked for the attachment of the brachioradialis muscle. This muscle serves in rapid flexion and extension of the elbow. The distal humerus exhibits a developed facet above the capitulum indicating habitual tight flexion of the elbow.

Pathology

The cranial bones are thick (measures 10.1 mm mid parietal) yet only slight ectocranial porosis is noted. The left parietal exhibits slight ectocranial porosis.

41RF1-BP16-060A

From a Sort

This individual is an adult male aged 25-34 years of possible Native American ancestry. Preservation of this disturbed burial is poor to moderate. No cranial remains are associated with these postcranial remains. The color of the bone ranges from a light to medium brown, and root damage is apparent, especially in the etched cortical surface of the fibula fragments. The femora are the bones that appear in the photograph (Roll 7, #12) as articulated and extended legs, however the tibiae and fibulae are matched by sorting. The right tibia exhibits scrapes and fractures that are postmortem resulting from disturbance.

Age

Age is based on the virtual absence of osteoarthritic changes on the articular surfaces, the exception is the distal articular surface of the left humerus, which exhibits very slight lipping. The cortex of the long bones is youthful in appearance, and the intertrochanteric fossa of the femora are free of spicules.

Ancestry

Moderate platymeria is evident in the proximal femora, which suggests possible Native American ancestry. No other indicators are present.

Functional Morphology

The left clavicle exhibits marked roughening at the attachment of the deltoid muscle. The left humerus exhibits moderate development of the attachment for pectoralis major. Other muscle attachment sites are missing due to the fragmentation. The left radius shows marked roughening at the attachment for pronator teres.

The proximal femora exhibit slight development of Poirier's facets, only slight roughening of the gluteal muscle attachment sites, and moderate platymeria.

41RF1-BP16-060B**From a Sort**

This individual is a child, aged 7.5 to 8.5 years (code 09) of unknown sex and ancestry. The individual is represented by fragmentary postcranial elements. The burial is disturbed and exhibits evidence of this in the form of postmortem chop marks on the posterior shaft of the right femur. This individual was sorted on the basis of bone size, texture and color as well as the age of the individual.

Age

The right femur measures 287 mm, which suggests an age range of 7.5 to 8.5 years.

41RF1-BP16-060C**From a Sort**

The remains of an infant, aged 0.5-1.5 years (code 02), were sorted from the remains of several individuals in Feature 16. The burial is very incomplete represented by a few cranial fragments, a sacrum fragment, and two deciduous teeth. The color of the remains ranges from yellow to brown, and plant root action is evident.

Age

Age is estimated from dental elements. The deciduous maxillary and mandibular lateral incisors are both root ½ complete. These correspond to an age range of 0.5-1.5 years.

41RF1-BP16-067**From a Sort**

This individual is a female aged 12.5-13.5 (code 14) of unknown ancestry. This burial is represented by a very fragmentary cranium and teeth. This sort was based on the dental development. Small areas of black staining are present on the frontal just left of nasion and on the maxilla near the nasal aperture. This may be caused by contact with some of the cremated remains that were also recovered from this burial feature.

Age

Age is based on dental development. The mandibular third molars exhibit the initial root formation, which suggests an age of 12.8 years. The maxillary third molars are also unerupted.

Sex

The small size of the dentition suggest that this is a female.

Dentition

The majority of the teeth are present, however most of the maxillary anterior teeth are missing postmortem. Calculus deposits range from flecks to coalesced. None of the third molars were erupted. The right lateral maxillary incisor is barrel shaped.

41RF1-BP16-072**From a Sort**

This individual is a female aged 17-19 (code 19), of unknown ancestry. This was a disturbed burial, and the skeleton is represented only by very fragmentary elements. Most of the cranium is present, however it is fragmentary and measurements are minimal. Of the postcranial skeleton, only appendicular skeletal elements are present, and like the cranium, only minimal measurements are available. This individual was sorted on the basis of bone size and color.

Age

Age estimation is based on the developmental stage of the mandibular third molars. These teeth exhibit apex ½ formed. The skeletal elements exhibit no osteoarthritic changes, and the cranial sutures are open.

Sex

Sex is estimated as female based on the gracile nature of the elements.

Dentition

The teeth of this individual are mostly present. The right maxillary second molar and right mandibular second molar exhibit small pit caries on the occlusal surface. Calculus deposits range from flecks to moderate, and the attrition is only slight on all of the teeth. The lateral incisors exhibit slight shoveling.

Functional Morphology

The lateral portion of the right clavicle exhibits marked attachment for the deltoid muscle.

Pathology

The right parietal was scored for slight active ectocranial porosis.

41RF1-BP16-083**From a Sort**

This individual is an adult male, aged 30 to 40 years of possible Native American ancestry. These remains were disturbed and commingled with the other individuals in this burial feature. Skeletal representation is moderate to poor. Cranial elements include a fragmentary occipital, left temporal, parietals and a nearly complete mandible. Postcranial remains include portions of the left scapula, clavicle and humerus, a right clavicle, numerous rib fragments, a thoracic vertebra, small fragment of the left innominate, and the bones of the lower legs. The elements are fragmentary and show root damage. The bones are a light to medium brown in color.

Age

None of the traditional age indicators are present. The age estimation was based on dental attrition, condition of the cortical bone and osteoarthritic changes. Dental wear ranges from slight to moderate. The cortical bone is firm and youthful in appearance. Osteoarthritic changes are slight to moderate.

Ancestry

The large size of the mandible, the shape of the mandibular symphysis, and the shape of the dental arcade are consistent with Native American ancestry. Ancestry estimation is further suggested by pronounced development of the shoulder and arm bones and the enamel chipping exhibited on the dentition. These features are indicative of behavior, but are evident in other Native Americans in this series.

Dentition

Only nine teeth are present. The three left maxillary molars are present without their respective alveolar sockets. The mandibular dentition include mostly posterior teeth as well as the left lateral incisor. Calculus deposits range from flecks to three-dimensional. The left mandibular first molar has a pit carious lesion on the occlusal surface.

The most striking feature of the dentition of this individual is the extensive enamel chipping and breakage. Table IIA-9 describes the location and dimensions of these damaged teeth.

Functional Morphology

The nuchal region of the occipital shows moderate development.

The clavicles exhibit marked development for the attachment of the deltoid muscles.

Table IIA-9. Location and measurements of damaged teeth from 41RF1-BP16-083

Tooth	Location of Defect	Diameter (mm)	Height (mm)
Left max. 1st molar	buccal distal margin	1.6	5.9 (1 mm in depth)
Left max. 2nd molar	buccal mesial margin	3.2	2
Left man. lateral incisor	mesial margin	<1	<1
Left man. 2nd premolar	mesial margin	3	1.2
Left man. 1st molar	lingual distal margin	3.4	3.1
Right man. 2nd premolar	mesial margin	2.9	1
Right man. 1st molar	lingual mesial margin	3	1
Right man. 2nd molar	entire lingual margin	11.5	6.5

The dorsal lateral surface of the left scapula shows marked development of the attachment for teres minor. The proximal left humerus has moderate to well-developed attachments for the deltoid, pectoralis major, and lateral head of the triceps muscles. The distal portion of this bone shows a marked supracondylar ridge for the attachment of the brachioradialis muscle. All of these shoulder and arm muscles work to flex, extend, and rotate medially and laterally the shoulder and elbow.

Pathology

The left side of the mandibular body has a perimortem fracture. Most of the alveolus between the second premolar and the third molar is missing. The underlying inferior portion of the mandibular body has a jagged, diagonal fracture extending anteriorly and inferiorly from the third molar to the inferior ramus below the left canine and first premolar. The fracture edges are discolored and sharply defined. Although it is possible that this breakage could have been produced by old postmortem disturbance of this highly commingled burial feature, there are no indications of chopping or shovel damage. This individual likely died as a result of trauma, as the fracture margins show no evidence of healing. The fragmentary condition of the cranium and the remainder of the skeleton precludes comprehensive evaluation for trauma. Other pathological conditions are described below:

- 1) The left parietal exhibits slight, active, ectocranial porosis.
- 2) The thoracic vertebra has moderate lipping on the margin of the centrum. The neural arch also exhibits slight development of ligamentum flava.
- 3) The lateral portion of the left clavicle exhibits a well-healed fracture.
- 4) The left glenoid fossa shows expansion and lipping along the margin. The left distal humerus has slight osteoarthritic lipping on the margin and the joint surface.
- 5) The left patella and the Achilles attachment of the right calcaneus have small enthesophytes.
- 6) The right tibia exhibits moderate healed periostitis on the anterior middle third shaft.

41RF1-BP16-083A

From a Sort

This individual is an adult female, aged 18 to 22 years, of Native American ancestry. This burial is fragmentary and the material was sorted from the disturbed elements found

above 41RF1-16-093. The elements appear to have been redeposited after the interment of the primary burial. The excavation of the burial feature for 41RF1-16-093 probably disturbed the three individuals that represent Burial 83. The skeletal elements were sorted based on size, color, and age of the bones. In general the bone is in fair condition, but extremely fragmentary.

Age

The age estimate of this individual is based on epiphyseal closure, auricular surface morphology, and dental attrition. The auricular surface morphology is consistent with a Phase 1. Vertebral epiphyseal rings are actively fusing in the lumbar and thoracic vertebrae, and the epiphyseal line of the distal ulna is still evident. Dental attrition is slight on the posterior teeth. These characteristics are consistent with an individual between 18 and 22 years.

Ancestry

The ancestry of this individual is estimated as Native American. The teeth are large with a slight shovel on the central incisor. A small squatting facet is present on the distal tibia. These traits are characteristics of Native American populations.

Sex

The sex estimate is based on the overall small size of the postcranial skeleton and pelvic morphology. The auricular surface is slightly raised and subpubic angle is obtuse. These characteristics are consistent with female individuals.

Dentition

The teeth of this individual are well represented. Tooth wear ranges from slight to moderate from the posterior to the anterior teeth. Fragments of the alveolar bone are present, but these sections could not be correlated to specific teeth due to the lack of tooth roots. Calculus varies from moderate to coalesced deposits. No dental caries or abscesses are present. The upper right second premolar and second molar display small enamel fractures.

Functional Morphology

Small squatting facets are present on the anterior distal right tibia.

Pathology

Slight cribra orbitalia is evident on the orbital roof. The area is expanded and displays slight porosity.

41RF1-BP16-083B**From a Sort**

This individual is a child aged 10.5 to 11.5 years. Sex and ancestry are unknown due to the incomplete and fragmentary nature of this burial. This burial was greatly disturbed in this burial feature. The skeletal elements were sorted based on size, color, and age of the bones.

Age

Age is based on the development of the left mandibular second premolar and stage of development of the postcranial elements. The tooth exhibits $\frac{3}{4}$ root formation and suggests an age of 10.4 years. The vertebrae exhibit fusion of the neural arches to the centra, and the epiphyseal rings are not in evidence. The incomplete sacral elements are immature yet are moderate in size. The left proximal tibial epiphysis remains unfused, however the bone is moderate in size and is larger than the proximal tibiae belonging to 41RF1-BP16-060B.

41RF1-BP16-093

This individual is an adult male, aged 30 to 40 years, of Native American ancestry. The burial represents a primary interment. The commingled remains of Burial 83 were placed on top of this individual. The cranium and right upper limbs were disturbed by Burial 83, suggesting that 41RF1-BP16-093 was partially or completely skeletonized prior to the deposition of Burial 83. In general, the bone is in good condition, but fragmentary.

Age

The age estimate of this individual is based on the available pelvic indicators, the degree of osteoarthritic activity, epiphyseal closure, and dental attrition. The pubic symphysis classifies as a Todd Phase 8 and a Suchey-Brooks Phase 4. The auricular surface morphology is consistent with a Phase 3. These characteristics are consistent with an individual between 30 and 40 years.

Ancestry

The ancestry of this individual of this individual is estimated as Native American. The overall postcranial morphology is robust. The teeth are heavily worn and large, which are general characteristics of Native American populations. The robust postcranial remains are consistent with historic descriptions of Karankawa males.

Sex

The sex estimate is based on the overall robustness of the postcranial skeleton and pelvic morphology. The auricular surface is flat and not raised. The vertical diameter of the

humerus head is 48 mm and the maximum diameter of the femoral head is 48 mm. Both dimensions fall within male ranges.

Dentition

The teeth of this individual are well represented. Tooth wear ranges from moderate to severe attrition from the posterior to the anterior teeth. Alveolar bone is missing and a majority of the tooth roots are fragmentary. Calculus varies from flecks to heavy deposits. One large root caries is present on the maxillary right second molar. The lesion penetrates the pulp chamber.

Functional Morphology

Small squatting facets are present bilaterally on the anterior distal tibiae. Overall, the individual is robust and muscle attachments are well-developed.

Pathology

Ectocranial porosity is present on the squamous portion of the occipital and parietals. The porosity is restricted to the area superior and posterior to the temporalis fascia. Extensive mild osteoarthritic activity is evident on upper appendicular elements. Mild marginal articular osteophytes are present on the left distal humerus, the proximal and distal radii and ulnae, and the right carpal bones. Slight eburnation is present on the articular surface of the right distal ulna. Slight surface porosity is present bilaterally on the proximal radii and on the distal left humerus. Vertebral pathology includes mild marginal lipping and porosity on the lumbar vertebrae and the sacral promontory.

Extra Elements

- 1) One lower premolar from an adult.

Burial Feature 17**41RF1-BP17-062**

This individual is a male, aged 30-45 years (code 24), possibly of Native American ancestry. The individual represents a partially disturbed primary interment. Most of the elements from the upper thorax and cranium of this individual are missing. The burial is extremely fragmentary but in fair condition.

Age

All the primary age indicators of the pelvis and cranium are absent. The sacral elements and vertebral centra are completely fused. Dental attrition is moderate. Slight

osteoarthritic lipping is evident in the knee joints but not the elbow joint. This pattern is consistent with an adult between 30-45 years old.

Ancestry

Morphological evidence of ancestry is limited due to extreme fragmentation. The lower lateral incisor and canine exhibit moderate lingual shoveling, which is more frequently documented in Native American populations.

Sex

The overall size of the skeleton is large with moderately robust lower limbs. No primary sex indicators are available.

Dentition

Dental remains are limited to four loose teeth. All teeth are moderately worn with moderate to heavy calculus deposits. The wear pattern is consistent with an edge-to-edge occlusion pattern.

Functional Morphology

A small articular facet (8.5 mm in diameter) on the posterior surface of the femoral neck is roughened and raised from the neck. This facet may result from contact with the capsular ligament.

Pathology

Mild marginal osteoarthritic lipping is present on the distal femur bilaterally, the right patella, and the proximal right tibia. The proximal tibia shafts are expanded and healed periosteal lesion are evident on the fibulae. No localized periosteal deposits or sclerotic surface plaques are present on the tibiae. The proximal shaft is simply enlarged with normal compact bone thickness. The surface exhibits fine porosity with slight striations.

Extra Elements

- 1) Older adult maxillary premolar.
- 2) Subadult neural arch.
- 3) Adult coccyx.

41RF1-BP17-F01L

(was associated with 41RF1-BP17-062)

This element represents the proximal shaft of a left femur. The shaft is from an adult with thick cortical bone and well-developed trabeculae. The shaft exhibits a perimortem fracture in the intertrochanteric region. In general, the break is comminuted with oblique fracture lines. The element consists of nine bone fragments but numerous pieces are

missing postmortem. Galloway classifies this type of fracture as a “subtrochanteric fracture with butterfly segments” (1999:174-179; following the classification system of Seinsheimer [1978]). These types of fractures typically result axial loading of the femur or from “direct lateral force applied to the upper thigh” (Galloway 1999:177). Often these types of fractures occur due to a fall or high energy impact.

41RF1-BP17-070

A mostly complete skeleton of a newborn infant represents this burial. The bone is moderately well preserved and is light to dark brown in color. Age is estimated based on the length of the maximum length of the left tibia (69 mm). This individual is unremarkable with regards to pathology.

41RF1-BP17-071

From a Sort

This individual is an infant, aged 2-4 years (code 04), of indeterminate ancestry. The material was sorted from the disturbed elements found around 41RF1-17-062. The burial is very fragmentary and consists of a few cranial fragments, numerous deciduous teeth, and several permanent tooth crowns. The skeletal elements were sorted based on size, development, and color. In general, the bone is in fair condition, but extremely fragmentary.

Age

The age estimate is based on dental development. Eight deciduous teeth are present. These teeth are fully developed and in occlusion. Six permanent partial tooth crowns are also present. These teeth represent mandibular incisors and canines. The crowns of the permanent incisors are complete (Crc, code 6). The crowns of the canine are three-quarters complete (Cr $\frac{3}{4}$, code 5), which correlates to an age of 2.9 years. The dental development is consistent with an individual 2.5 to 3.5 years old.

Ancestry

The ancestry of this individual is indeterminate. The deciduous incisors exhibit slight lingual shoveling.

Dentition

The deciduous teeth are in good condition with slight occlusal wear. Calculus deposits on the teeth are slight. Linear enamel hypoplasias are evident at the base of the crowns of the mandibular canines. The crowns are not complete and these defects may represent stress episodes just prior to death. Enamel pit defects are present on the lateral mandibular incisors.

Pathology

Slight cribra orbitalia is present in the left orbit. The bone is damaged, but slight surface porosity without bony expansion is evident around the margins near the supraorbital border.

41RF1-BP17-074**From a Sort**

This individual is a child, aged 9 to 11 years, possibly of Native American ancestry. The material was sorted from the disturbed skeletal elements found around 41RF1-17-062. The burial is very fragmentary, and material consists of a few cranial fragments, teeth, and a limited number of postcranial elements. The skeletal elements were sorted based on size, development, and color. In general, the bone is in fair condition, but extremely fragmentary.

Age

The age estimate is based on dental development. Tooth development is observable on three mandibular teeth. The roots of the mandibular canine and second molar are $\frac{3}{4}$ complete. The crown of the mandibular third molar is $\frac{3}{4}$ complete. The dental development is consistent with an age from 9 to 11 years.

Ancestry

The ancestry of this individual is based on dental morphology. The lateral central incisor exhibits marked shoveling.

Dentition

The represented teeth are in good condition with slight calculus deposits and no carious lesions. Occlusal wear is slight on the first molars. The enamel of the right first mandibular is chipped on the buccal surface.

41RF1-BP17-078

This individual is an adult male, age 30-34 (code 23), of possibly Native American ancestry. The individual was defined as a disturbed burial identified by a scatter of elements located around 41RF1-BP17-079. The remains are fragmentary and very incomplete, with only the elements of the left arm and shoulder region and portions of both legs and feet. The bones range in color from brown to yellowish-brown, and root action is evident. No cranial or dental remains are associated with this individual.

Age

Age is estimated by the pubic symphysis morphology and general condition of the skeletal elements. The right pubic symphysis matches a Todd Phase 6, and the otherwise lack of degenerative joint disease indicates a young adult.

Ancestry

Ancestry for this individual is estimated as Native American due to the overall robusticity of the postcrania, which is indicative of other Native Americans in this series.

Sex

Sex for this individual is male, based on the morphology of the pubic symphysis and the overall robust nature of the postcrania.

Functional Morphology

This individual displays an overall robusticity of the postcrania. The clavicle displays well-developed attachment sites for deltoid and trapezius muscles.

The left humerus displays marked development of the attachment sites for deltoid, teres major, latissimus dorsi, and pectoralis muscles. The lateral epicondylar ridge is also well-developed showing the attachment of extensor carpi radialis longus.

Pathology

This individual has slight development of ligament flava on the vertebral arch of the third thoracic vertebra. Severe osteomyelitis is present on one left rib (#'s 3-10), most likely resulting from a previous fracture, or series of fractures. The lesion is widespread on the rib with nine cloacae present (seven located plural side, two exterior side) and signs of moderate healing.

41RF1-BP17-079

This individual is an infant, age newborn to 6 months, of indeterminate sex and ancestry. The remains are mostly complete, however the cranium is highly fragmented. The color of the bone ranges from light brown to yellowish brown, and there is evidence of root action on some of the elements.

Age

Age was estimated by long bone and dental development. Dental formation of the first deciduous maxillary molar is crown $\frac{1}{2}$ and the second maxillary molar exhibits initial

coalescence of the crown. These indicate an age of newborn to 6 months.

Ancestry

The maxillary incisors exhibit moderately shovel shaping indicating possible Native American ancestry.

Dentition

Nine identifiable teeth were present for this individual. The left maxillary first molar was crown $\frac{1}{4}$, and a maxillary second molar was crown initial and was unable to be sided.

41RF1-BP17-086

This individual is an adult female, age 30-39 years (code 23), of Native American ancestry. The individual consists of a primary extended burial located in the northern half of Burial Feature 17. Numerous disarticulated elements are located on the lower extremities. These elements were identified as Burial 87 and 90.

This individual is very small and gracile. The bone is in very good condition and well preserved. The cranium is fragmented but well preserved, and the postcranial elements are well represented. Surface color ranges from the typical light to yellowish brown.

Age

The age estimate of this individual is based on epiphyseal closure, auricular surface morphology, and general degenerative joint disease. The medial clavicle epiphyses and sacral bodies are completely fused. The auricular surface morphology is consistent with a Phase 3. Slight marginal osteoarthritic lipping is present on the distal femur and patella. No vertebral degeneration is evident.

Ancestry

The ancestry of this individual is difficult to determine. The skeletal size is not consistent with the morphological pattern in the Native American populations. The gracile femora are platymeric. The tibia and talus lack squatting facets. The upper incisor exhibits a marked shovel with an edge-to-edge wear pattern. Overall, skeletal and dental morphology suggest a individual with Native American ancestry.

Sex

The sex estimate is based on the overall small size of the postcranial skeleton and pelvic morphology. The auricular surface is slightly raised and subpubic angle is obtuse. These characteristics are consistent with female individuals.

Dentition

Complete dentition was present from this individual. The two teeth show slight wear with moderate to heavy calculus deposits. Carious lesions are present in the right maxillary third molar and left mandibular third molar, and several linear enamel hypoplasias are evident on the maxillary incisors.

Functional Morphology

The skeleton is very small. The attachment of the anterior border of the deltoid muscle on the clavicle is well marked. The individual appears to have repeatedly hyperextended her elbow. The posterior articular surface extends along the lateral margins of the olecranon fossa of the humerus. The lower limbs are unremarkable.

Pathology

The condition of the skeleton is excellent and several pathological conditions are evident. This individual exhibits bilateral *Brachymetacarpia* and *Brachymetatarsia* of the 1st, 4th, and 5th metacarpals and the 4th metatarsal. The right 5th metatarsal is shortened but the left element is normal. These elements are short in comparison to the other rays (Table IIA-10). The distal articular ends of the metatarsals are flattened and irregular in the shortened bones. Immature fusion of the distal epiphysis may have reduced the overall length of these elements. The middle phalanges of the 4th and 5th digits are also reduced as compared to the middle phalanges of the 2nd and 3rd digits. The expression of this disorder is highly variable in a Japanese sample from Nagoya, Japan (Takayuki et al. 1986). The pattern of reduction seen in this burial is consistent

Table IIA-10. Maximum length (in mm) of Metacarpals and Metatarsals from Burial 41RF1-BP17-086

Element	Left	Right
MC1	28	28
MC2	53.5	55
MC3	53	52
MC4	34	34
MC5	30	30
MT1	51.5	52
MT2	59	--
MT3	55	--
MT4	42	41
MT5	51.5	43

with only one individual from the Japanese study. Recent research by Cervantes and colleagues (1988) suggests that this disorder is frequently associated with individuals of familial short stature (Cervantes et al. 1988).

The styloid processes of the ulnae are modified. The processes are flattened and elongated. No osteoarthritic changes are evident, but small articular facets are present on the on the triquetral bones.

Mild marginal osteoarthritic lipping is evident on the distal femora and the right patella.

Extra Elements

- 1) Infant bones (5 fragments).
- 2) Adult carpal, metacarpals, and phalanges.

41RF1-BP17-087

From a Sort

This individual is an adult male, age 27-35 (code 22), of possible Hispanic/Native American mixed ancestry. The elements were associated with a scatter of bone located at the feet of 41RF1-BP17-086. The individual was sorted from the remains of 41RF1-BP17-090 based on overall robusticity, skeletal pathology, and the younger age of this individual compared to 41RF1-BP17-090.

Multiple perimortem cutmarks on the cranial vault indicate this individual suffered a traumatic death. The remains are well preserved, and most elements are complete. The color of the bone is yellow to brown, and root action is evident. Green copper staining is present on the fourth, fifth, and sixth thoracic vertebrae. Unfortunately, disturbance of the burial precludes clear association of artifacts.

This individual also displays unusual fractures on both the left and right radius and ulna. The fractures appear to have occurred when the bone was still fresh due to the spiraling fracture pattern. Most likely, the individual was interred as a primary burial, and the fractures resulted from the original exhumation of the remains soon after death.

Age

Age estimation is based on pubic symphysis morphology, auricular surface features, and the incomplete fusion of the epiphysis of the medial clavicle. The pubic symphysis is consistent with a Todd Phase 5+ and a Suchey-Brooks Phase 4. The auricular surface morphology is consistent with Phase 3. All of these indicators suggest a range of 27 to 35 years of age.

Ancestry

Ancestry estimation is based on facial morphology, dental morphology, and overall size of the remains. The morphology of the face is characterized by slightly retreating zygomatics, slight recurvature of the zygomaxillary suture, and reduced supraorbital ridge. The inferior nasal border exhibits a nasal sill. Slight shoveling is present on the lateral mandibular incisor. The individual is of short stature as indicated by long bones lengths, and the postcranial elements are robust in nature. The combination of these traits suggests that this individual is most likely of mixed Hispanic and Native American ancestry.

Sex

Estimation of sex is based on the robusticity of the skeletal elements. The cranial vault exhibits large mastoid processes and well-developed supramastoid crests, moderate development of the nuchal region, and large malars. Postcranial development shows well-developed or marked attachments for muscles (see Functional Morphology). These features indicate this individual is male.

Dentition

The dentition for this individual is fairly well represented. The mandibular dentition is more complete than the maxillary dentition. The overall wear is light on the molars and heavier on the anterior dentition. Linear enamel hypoplasias are present in several of the mandibular teeth including the canines, right lateral incisor, and the right second molar. Calculus deposits range from moderate to heavy on the anterior dentition and light to moderate on the posterior dentition.

Functional Morphology

This individual has a moderately developed postcranial skeleton. The attachments of the shoulder and upper arm muscles are well marked. The clavicle has a marked attachment for the deltoid. The attachments of deltoid, latissimus dorsi, teres major, and pectoralis major muscles are well-developed on the humerus. The ulna has a moderately developed interosseous crest.

Pathology

This individual appears to have been relatively healthy as indicated by absence of bone pathology. However, scalping cutmarks are present on the cranial vault indicating traumatic death. A total of eleven cuts are present with eight of the cuts arranged in an arc on the frontal (Table IIA-11). This arc extends from the left anterior temporal line reaching close to the right anterior temporal line. Direction of the cuts is difficult

to determine and thus not attempted here. Other arc shaped cuts are present on the parietals near the lambdoidal suture.

Table IIA-11. Location and measurements of cutmarks on burial 41RF1-BP17-087

Cut	Location	Length (mm)
A	frontal	15.1
B	frontal	13.1
C	frontal	2
D	frontal	11.1
E	frontal	11.9
F	frontal	5
G	frontal	10.7
H	frontal	8.9
I	left parietal	23.7
J	right parietal	13.1
K	right parietal	18.5

41RF1-BP17-090

From a Sort

This individual is an adult male, age 35 to 45 years (code 25), of Native American ancestry. The individual consists of disarticulated elements piled at the feet of 41RF1-BP17-086. Two other individuals were identified in the mixed remains including an adult male (41RF1-BP17-089) and an infant (41RF1-BP17-094) with this individual. The two adults were readily sorted based on overall size, bone texture, and skeletal pathology. This individual is very large and robust. Numerous pathological changes are present, and some may represent a treponemal infection. The bone is in good condition and well preserved, but most elements are fragmentary. Surface color ranges from the typical light to yellowish brown.

Age

The age estimate of this individual is based on pubic symphysis morphology, auricular surface features, and general degenerative joint disease. The pubic symphysis is partially represented. The surface morphology is consistent with Todd's Phase 7 and Suchey-Brook's Phase 4. The auricular surface exhibits a transitional surface texture with a tendency towards densification. Such a surface pattern is consistent with Phase 5. Osteoarthritic activity is wide spread in multiple joint complexes. Dental wear is quite heavy on the anterior teeth and the molars. These characteristics are consistent with an individual between 35 and 45 years.

Ancestry

Ancestry is estimated based on morphology of the postcranial elements as well as the dentition. The skeletal size is consistent with the morphological pattern reported for the local Native American Karankawa population. The femora are platymeric. The tibia and talus lack squatting facets. Dental attrition is marked with an edge-to-edge pattern. Overall, skeletal and dental morphology suggest a individual with Native American ancestry.

Sex

Sex for this individual is male, based on the morphology of the pubic symphysis and the overall robust nature of the postcrania, mandible and skull.

Dentition

The dental remains from this individual are fairly well represented. Most alveolar structures are present, but these are fragmented. Several anterior teeth have been lost postmortem. Heavy dental wear is present on the anterior teeth with moderate wear on the molars. Five molars exhibit periodontal abscesses, and four anterior teeth have periapical abscesses. The pulp chamber of the left central maxillary incisor is exposed as a result of occlusal wear. A large periapical abscess is present on the labial surface of the alveolus surrounding the tooth root, which exhibits hypercementosis. Large periodontal lesions surround several mandibular and maxillary molar roots. Two interproximal grooves are present, and one is associated with a periodontal abscess. The shape of both mandibular condyles is irregular, and the temporomandibular joints (glenoid fossa) show slight erosion with marginal lipping. The maxillary atria exhibit mild sinusitis with sclerotic bone apposition and remodeled bony spicules.

Functional Morphology

Overall, this individual is very robust. The deltoid muscle attachments on the lateral aspect of the clavicle are marked and well-developed. In addition, the humeri exhibit marked muscle development for the attachment of the biceps, deltoid and triceps.

Pathology

Numerous pathological lesions are present in this individual. Vertebral osteophytes are present on the anterior margin of the fifth lumbar centrum and in the upper lumbar centra. The upper thoracic series has slight marginal lipping along the vertebral facets.

In the upper limbs, the coronoid process of the right ulna and the right radial head are fractured. The break is incomplete and well-healed. In the radius, the fracture line bisects the radial head. The fracture separated more on the lateral half of the head. The primary force was directed at the posterior half of the head, which would have been in contact with the humerus. The ulna fracture is limited to the anterior third of the coronoid process. The fracture line is semilunar shaped and has resulted in slight marginal osteoarthritic lipping of the joint. The proximal head of the first right metacarpal and possibly the right trapezium exhibit healed fractures. Severe trauma induced osteoarthritic lipping surrounds the trapezium-first metacarpal joint, and the joint surface is eburnated. Osteoarthritic lipping and surface eburnation is present on two hand phalanges at the proximal-middle joint resulting in a reduced range of motion. These fractures appear to be the result of one incident, possibly a fall impacting on the thenar eminence of the hand with the arm in a pronated position. The impact force would have been directed up the radius and to a lesser degree the ulna resulting in the fractures in the elbow.

Mild marginal osteoarthritic lipping is present on the proximal ulnae, distal humeri, the glenoid fossa of the left scapula, and the left patella.

Marked periosteal expansion is present on the femora, tibiae and to a lesser extent the fibulae. Activity in the femora is restricted to the distal third of the shaft. On the right side, periosteal lesions begin 5.5 cm from midshaft. On the left femur, activity is present at 4.0 cm from midshaft. Activity in the tibia is present on all shaft surfaces. Periosteal lesions in the fibulae are limited and are typically near the interosseous crest. In all cases, the lesions are healed, and the areas show sclerotic surface deposits or plaques. On both femora, surface apposition is well defined with approximately 1 to 2 mm of bony expansion from the original lamellar/periosteal surface. These lesions indicate a long-term systemic infection in this individual. The activity pattern is consistent with a treponemal infection. However, cranial lesions (e.g., caries sicca) are absent.

Extra Elements

- 1) Occipital fragment from an adolescent/young adult.

41RF1-BP17-094

This late-term fetus is represented by two cranial bones, the left scapula, three left and five right partial ribs, both ilia, and most of the long bone diaphyses. The very young age precludes determinations of sex and ancestry. All elements

present show moderate to severe pathological changes from systemic infection, possibly congenital syphilis.

Age

Age is based on the lengths of the diaphyses of the radius (39 mm), ulna (44 mm) and femur (59 mm). These measurements correspond with a gestational age of approximately 8-9 lunar months.

Pathology

The long bones show pronounced thickening of the diaphyses due to formation of an abnormal layer of subperiosteal woven bone. These changes are evident along the entire circumferences and lengths of the diaphyses. Postmortem loss of some of this woven bone allows direct measurement of the thickness of this layer relative to the underlying cortical bone. These thicknesses range between 1.8 to 2.8 mm. Medullary cavities are represented by small channels due to internal apposition and stenosis. Even the ribs show subperiosteal bone formation.

Changes observed in infant skeletons due to congenital syphilis include “multiosseous, usually symmetrical, circumferential deposition of subperiosteal bone on the shafts of long bones. The trabeculae of this bone deposit often show a radial arrangement” (Ortner and Putschar 1985:198-199).

Burial Feature 18

41RF1-BP18-061

This individual is an infant aged newborn to six months (code 01) of indeterminate sex and ancestry. The extended articulated burial is the only individual identified in this feature. The remains are highly fragmentary, and fairly complete. The color of the remains ranges from yellow to brown, and root action is evident.

Age

Age for this individual is based on dental formation. The mandibular first molar is crown ½ complete (code 03), which corresponds to an age of .175 year.

Burial Feature 19

41RF1-BP19-064

This individual is an infant aged newborn to six months (code 01) of indeterminate sex and ancestry. The skeleton is

fragmentary and had been disturbed by the interment of Burial 41RF1-BP19-065. The color ranges from light to medium brown. No complete long bone diaphyses or dental remains are present. A section of the femur midshaft is greater than 75 mm in length suggesting an age of newborn to six months. No pathological lesions are evident in this individual.

41RF1-BP19-065

This individual is an infant aged newborn to six months (code 01) of indeterminate sex and ancestry. The skeleton is mostly complete and somewhat fragmentary, and the color ranges from light to medium brown. The age of the infant is based on dental development of the mandibular deciduous canines and right deciduous first molar. Dental development places this infant closer to newborn than older. The left radius has a length of 55 mm, which also indicates a newborn to six month old infant. The elements are unremarkable with regard to pathology.

Burial Feature 20

41RF1-BP20-002

This individual is an old adult, age 60 or greater (code 29), of European or non-Native American ancestry. The individual is probably male. The burial consists of a single extended primary interment. Several bone fragments from an infant are associated with this person. The burial feature is located in the middle of the burial area. The upper thorax and cranium were exposed during backhoe trenching at the site. These elements were removed, and the remaining portions of the burial were removed during later excavations. Copper beads and cloth fragments were identified with the burial. The bone is in good condition, but all elements are extremely fragmentary. Surface color ranges from the typical light brown to dark brown/black. Numerous pathological lesions are evident in this individual. The pattern of lytic lesions is consistent with a relatively rare hemopoietic disorder, *Multiple Myeloma* or possibly metastatic carcinoma. Numerous lytic lesions develop in the bone marrow spaces, gradually enlarge, and destroy the surrounding bone. Multiple myeloma more frequently occurs in males and older adults (over 50 years).

Age

The age of this individual is based on the assessment of available primary and secondary indicators. Primary indicators include the pubic symphysis and auricular surface

of the innominate. Secondary indicators include general patterns of oral health, cranial suture closure, degenerative joint disease, and a general assessment of bone density. A partial pubic symphysis exhibits a relatively flat symphyseal face and complete rim, which are consistent with Todd's Phase 8. The partial auricular surface has a coarse surface with occasional dense patches. This pattern is consistent with a Lovejoy Phase 5. The pattern of secondary indicators suggests an older individual. All of the indicators indicate an age of 60 years or older.

Ancestry

Ancestry estimation is quite difficult in this individual due to the extreme fragmentation. However, several indicators are present that may be evaluated. The oral health and dental condition of this individual is not typical of Native Americans in this series. The majority of the teeth were lost antemortem, and the remaining teeth are heavily worn and coated in calculus. One side of the inferior nasal border is present and exhibits a relatively sharp sill and nasal spine. These features indicate a non-Native ancestry. However, the femur is moderately platymeric, which suggests Native ancestry. Considering all of these traits, ancestry is estimated as possibly European or non-Native.

Sex

The primary sex indicators are absent in this individual. The secondary sex indicators, such as the cranium, are quite variable in overall morphology. The orbital margin is blunt, but the supraorbital region is quite gracile. The temporal and occipital regions are robust. Postcranial robusticity is moderate with well marked muscle origins and insertions. Based on this pattern the sex of this individual is estimated to be a probable male. Metric analysis may yield a better estimate of sex.

Dentition

The dentition and alveolar structures are poorly represented. The facial area in general is extremely fragmented. The anterior left maxillary teeth have been lost antemortem. The right alveolus is absent, but the right canine and two molars are present. Large carious lesions are present in the first and second right upper molars. The left maxillary molars are encased in calculus with severe alveolar resorption. The mandibular antimeres of the left maxillary molars are missing antemortem. Interproximal caries are present in two lower incisors and the left mandibular canine. Interproximal grooves are present on the mesial surface of the mandibular right second premolar and maxillary right canine.

Functional Morphology

Overall the muscular development is moderate to slight. Several muscle origins and insertions exhibit small to large enthesophytes. The pattern of these bony growths is consistent across all elements.

Pathology

Several pathological conditions or changes are evident in these remains. The various conditions include evidence of cancer with concomitant anemia, degenerative joint disease, and healed fractures.

Numerous small cavitations are evident on the endosteal surfaces and cortical cross-sections of all major long bones. The osteolytic defects exhibit no marginal osteoblastic reaction. Typically, this pattern of osteoclastic reactions is associated with multiple myeloma (MM), or possibly metastatic carcinoma (given the variation in lesion size). Ortner and Putschar (1985:264) describe myeloma as “a highly malignant tumor of the plasma cells, usually arising in a area of hemopoietic bone marrow.” The distribution of the lytic defects is consistent with this description. Scalloped areas and small cavitations are present on the endosteal surface of the humerus, radius, ulna, proximal femur, tibia, and fibula. The vertebral and rib elements are extremely fragmented, and presence of lesions on these elements is unknown. Defects in the right humerus are large, with a maximum diameter of approximately 35 mm. Cavitations evident on the radiographs of the other long bones are smaller with diameters ranging from 2 to 20 mm. Two to three possible defects are visible in the radiograph of the fragmentary cranial material. These lesions are restricted to diploë and have not expanded to the ecto- or endo-cranial bone layers.

Moderate cribra orbitalia is evident in both orbits. The development of cribra is consistent with a diagnosis of multiple myeloma, which affects the bone marrow spaces. [Tumors enlarge and fill bone marrow spaces of the major long bones resulting in anemic levels of red blood cells.]

Bony enthesophytes are present at numerous major muscle attachment locations. Moderate bone deposits are evident at the radial tuberosity, ischial tuberosity, iliac crest, anterior surface of the patella, tibial tuberosity, soleal line, and calcaneus. Other minor muscle attachment sites show small bony exostoses. Two thoracic vertebrae are ankylosed and the sacroiliac joint is bilaterally fused at the apex. Degenerative Joint Disease (DJD) is present in all major joints. Slight to moderate marginal lipping is evident in these joints. Bilateral moderate surface eburnation is present on

the distal ulna, which correlate to facets on the lunate. The ulnae appear elongated relative to the radii with minimal contact between the distal aspects of the two elements. Contact between the lunate and ulna may be related to trauma to wrist joints. The right distal radius is severely modified with extensive marginal lipping

The third and fourth right metatarsals exhibit healed fractures. The fourth metatarsal shaft is slightly expanded and bowed. The cortical bone is greatly reduced as compared to the unfractured left fourth metatarsal. The distal articulation of the third metatarsal is greatly expanded as a result of a fracture near the joint. Moderate marginal lipping and surface porosity is evident on the joint surfaces.

Mild healed periostitis is present on the right tibia shaft. Sclerotic bony deposits are present on the anterior and lateral surface of the shaft. All the lesions are healed.

Extra Elements

- 1) Remains of an infant including a proximal left ulna (became 41RF1-BP20-U01L), rib fragments, several vertebral neural arches.

Burial Feature 21

41RF1-BP21-069

This individual is a robust adult male, aged 35-40 years (code 24) of Native American ancestry. The burial is nearly complete and well preserved. The long bones are all present and nearly complete. The color of the remains ranges from yellow to brown, and root action is evident. Rust colored stains are present on three thoracic centra.

Age

Age for this individual is based on auricular surface morphology, degenerative skeletal changes, and dental wear. The auricular surface morphology is consistent with Phase 4, which correspond to an age of 35-40 years. Slight degenerative changes in the vertebra and major joints are consistent with an adult 30-40 years. Ossified costal cartilage is present with the remains suggesting an older age. Antemortem tooth loss, occlusal attrition, and dental disease are extensive which is consistent with an older adult.

Ancestry

The ancestry of this individual is probably Native American. The facial structure suggests an individual with a wide nasal aperture and wide palate. These traits are not consistent

with individuals of European ancestry. The skeletal size is consistent with the morphological pattern reported for the local Native American Karankawa population. The femora are platymeric, but the tibia and talus lack squatting facets. Dental attrition is heavy with an edge-to-edge wear pattern and shows severe dental disease. Overall, skeletal and dental morphology suggest a individual with Native American ancestry.

Sex

Sex estimation is based on the overall robusticity of the postcranial remains, and the morphology of the pelvis and cranium.

Dentition

The dental series is well represented with the exception of the a few maxillary alveolar fragments and six teeth. Dental wear is moderate to heavy on the anterior teeth. The mandibular molars are all missing antemortem, and the maxillary molars are moderately worn. Six maxillary teeth are abscessed, and large periodontal pockets surround the roots of the right maxillary canine and maxillary left first premolar. Interproximal root caries are present on the mandibular lateral incisors, and additional root lesions are present on an upper premolar, upper molar and a lower premolar. Calculus deposits range from moderate to coalesced on both the maxillary and mandibular anterior dentition. Heavy calculus is present on the maxillary molars with deposits extending over the occlusal surfaces. Enamel chipping is evident on the maxillary left canine and maxillary right first molar.

Functional Morphology

The postcranial skeleton is generally well-developed. The mandibular ramus is robust and well marked. The humeri display well-developed attachments for the rotator cuff muscles and the pectoralis muscles. The lower extremities exhibit well defined muscle attachments, but these sites are normal given the overall size of this individual.

Pathology

Skeletal pathological lesions include a vertebral anomaly, general degenerative conditions, periostitis, and a small button osteoma. Spondylolysis of the fifth lumbar vertebra is present. The posterior neural arch is completely separated through the lamina from the pedicles and transverse processes. The separation has resulted in compression of spinous process the forth and fifth lumbar vertebra. The inferior margin of the forth spinous process has created a articular facet on the superior surface of the fifth. The angulation of the separated neural arch is almost

perpendicular to the spine. The loose articulation between the fifth lumbar and first sacral unit has resulted in moderate marginal osteophytosis and intervertebral disk degeneration. Moderate osteophytes extend from the centrum margins of these two elements. The articular facets exhibit slight marginal lipping. The exact etiology of spondylolysis remains unresolved and is probably quite variable. Merbs (1996) suggests that the defect is traumatically induced; whereas, other researchers have suggested a significant genetic component (Stewart 1956; Lester and Shapiro 1968).

Slight osteoarthritic changes are evident in several of the major joints. Slight bilateral temporomandibular joint disease is evident in the glenoid fossa of the temporal. The joint surface exhibits slight surface porosity. In addition to the osseous changes associated with spondylolysis of the fifth lumbar, slight marginal centrum lipping and slight eburnation facet eburnation is present in the cervical vertebra. Slight marginal centrum lipping is present in the mid thoracic series. Slight marginal lipping is present on the distal humerus, proximal ulna, patella, and proximal tibia.

A small button osteoma is present on the superior portion of the occipital squamous. The osteoma measures 11 mm by 9 mm, and it is 1 mm high.

A periosteal lesion is present on the midshaft of the right tibia. The reaction is localized and healed encompassing a 45 mm section of the medial shaft.

41RF1-BP21-075

From a Sort

Present are the nearly complete remains of a female, 20-29 years (code 21) of possible Native American ancestry. The remains are highly fragmented due to postmortem damage. Missing elements include the left innominate, left patella, left talus and calcaneus, and several ribs from both sides and vertebrae. Other than postmortem damage, the preservation of the remains is fairly good.

Age

Estimation of age is based on morphological changes in the auricular surface and the overall condition of the remains. The partial auricular surface is consistent with a Phase 2, providing an age range of 25-29 years. This age range was lowered by the overall youthful appearance of the remains. The trabecular bone is dense and compact, as is the cortical bone. Slight degenerative joint disease over the entire skeleton. Slight dental wear exhibited by the teeth of this individual also corroborates the age estimate.

Ancestry

Estimation of ancestry was complicated by the lack of a complete skull. The best markers of ancestry are found on the cranial and facial elements, these elements were highly fragmentary and/or missing for this individual. This individual is estimated as a possible Native American based on palate and mandible shape and the presence of shovel-shaped incisors.

Sex

Sex is estimated as female based on morphology of the innominate, cranium, and femur head diameter. The auricular surface is elevated and displays a preauricular sulcus. The cranial remains exhibit small mastoid processes, and the shape and size of the mandible are indicative of females. Similarly, the femur head measures 40 mm in diameter indicating the individual was female.

Dentition

This individual exhibits very little wear and few dental caries. Caries present are located mostly on the occlusal or buccal surfaces of the maxillary right second molar and left first molar, and mandibular right first molar and all left molars. Calculus deposits range from low to moderate.

This individual has a retained deciduous canine in the right maxilla. The retention of this tooth appears to have altered the development of the right anterior teeth. The appearance of the alveolar bone suggests the right maxillary incisors are congenitally missing.

Pathology

This individual exhibits mild arthritic changes mainly in the left temporomandibular joint (TMJ) and the vertebral column. The left TMJ exhibits mild porosity on the surface of the joint, and the mandibular condyles have not been affected.

The cervical, thoracic, and lumbar vertebrae display mild porosity on the centra surfaces, and the thoracic vertebrae have mild lipping on the margins of the centra. The right acetabulum also displays mild lipping of the joint surface as does the distal right femur.

41RF1-BP21-076**From a Sort**

An adult female, aged 30-35 years (code 23) of Native American ancestry is represented. The burial is identified as a primary interment disturbed by 41RF1-BP21-069 and 41RF1-BP21-075. The remains were commingled with those of the 41RF1-BP21-075. The individuals were sorted based

on differences in size and color of the remains. This female is robust and mostly complete. The remains range in color from yellow to brown, and root action is evident on most elements.

Age

Age for this individual is based on auricular surface morphology and general cranial suture closure. The right and left auricular surfaces are consistent with Stages 3-4 indicating a range of 30-40 years. The sagittal and coronal sutures are greater than 50 percent closed ectocranially and obliterated endocranially.

Ancestry

Ancestry is estimated as Native based on the presence of shovel-shaped incisors, platymeric femora, and slight squatting facets.

Sex

Sex estimation is based on innominate, cranial morphology, and femoral head diameter. The greater sciatic notch is wide, a deep preauricular sulcus is present, and the auricular surface is elevated. The supraorbital ridge is slight, orbital margins are sharp, and the small mental eminence is rounded. The femur head measures 41 mm in diameter. All of these traits suggest the sex as female.

Dentition

This individual displays light to moderate wear, with the heaviest wear occurring on the maxillary and mandibular incisors. Calculus deposits range from slight to heavy coalescence of deposits, with the heaviest deposits on the maxillary and mandibular incisors and canines. There is no evidence for any abscessing dentition. Linear enamel hypoplasias occur on the maxillary lateral incisors.

The root of the right central maxillary incisor has a fracture in its apical third. The tooth crown and remaining two thirds of the root had been supported by the surrounding gingiva and periodontal ligament. The fracture is similar to the break evident in 41RF1-BP02-006, but the tooth in 41RF1-BP21-076 appears to have been held firmly in place. The tooth root is not eburnated. No collateral tooth fractures are evident indicating a localized traumatic force directed at the incisor.

Functional Morphology

This individual displays moderate development of the nuchal region and attachments for the masseter muscles on the mandible and zygomatic. The postcranial skeleton reveals overall marked development of muscle attachments. The

clavicle shows marked attachment for trapezius, pectoralis major, and deltoid muscles. The right humerus has moderate development of the attachments for deltoid, triceps brachii, latissimus dorsi, pectoralis major, and brachio radialis muscles. The radii display enlarged interosseous crests, radial tuberosities, and attachments for pronator teres on the muscles. The ulnae have enlarged interosseous crests, attachments for abductor pollicis longus, pronator quadratus, and brachialis muscles.

The ilia show marked development of the gluteal attachments. The femora exhibit marked attachments for gluteus maximus, medius, and minimus, and adductor longus, brevis, and magnus muscles. The tibiae have moderately developed attachments for the soleus muscles, and the interosseous crests are enlarged on the tibiae and fibula.

Pathology

Evidence of traumatic injury to the maxillary right central incisor is discussed in the dental section.

This individual displays slight healed localized ectocranial porosis of the left and right parietals. Slight marginal osteophyte formation is present on the vertebral body margins of the 10th, 11th, and 12th thoracic vertebrae. Slight porosity is present on the margin of the proximal humerus.

Burial Feature 22

41RF1-BP22-001

This individual is an adult female, aged 20-24 years (code 21) of possibly Native American ancestry. The burial is identified as primary with some posthumous shifting of the elements of the left side. Postmortem chop marks are evident on the cranium and long bones indicating that this individual was slightly disturbed historically. The general color of the remains ranges from yellow to brown, and root action is evident.

Age

Age estimation is based on medial clavicle fusion, pubic symphysis, and auricular surface morphology. The medial clavicle is partially fused which suggests an age in the early twenties. The pubic symphysis is a Todd Phase 3 and a Suchey-Brooks Phase 2 indicating an age of 22-24 years. The auricular surface is consistent with a Phase 1 suggesting an age of 20-24 years. All of these indicators are indicative of an age range of 20-24 years.

Ancestry

Ancestry is possibly Native American based on the marked platymeria of the femora and moderate shoveling of the mandibular lateral incisor. Also, the marked development and robusticity of this individual is consistent with other Native Americans in this series.

Sex

Estimation of sex is based on innominate morphology and femoral and humeral head diameters. The ventral arc, subpubic concavity, subpubic angle, ischio-pubic ramus ridge, greater sciatic notch, preauricular sulcus and elevation of the auricular area are all consistent with female morphology. The mental eminence is small and rounded, and the femoral and humeral heads measure 42 mm in diameter. These traits are indicative of a female.

Dentition

Eleven teeth are missing postmortem. The teeth present are in relatively good condition, and calculus deposits range from flecks to heavy. The maxillary left lateral incisor exhibits an abrasion on the occlusal surface that is commonly referred to as a "Tailor's Notch." The mesial lingual cusp of the maxillary right third molar has been broken.

Functional Morphology

The nuchal area of the occipital and the mastoid processes are moderately developed. This individual displays an overall markedly developed postcranial skeleton. The clavicle displays marked development of the attachments for the pectoralis major and deltoid muscles. The humeri show moderate development of the deltoid attachments. Development of interosseous crest on the radii and ulnae is marked.

The gluteal and adductor muscle group attachments on the innominates and femora are marked. The femora display marked platymeria. The lower legs exhibit developed attachments for the soleus muscle and interosseous crests.

Pathology

This individual displays slight active widespread ectocranial porosity on both parietals, and slight active localized ectocranial porosis on the occipital.

41RF1-BP22-003

This individual is an infant, aged newborn to six months (code 01) of indeterminate sex and ancestry. The skeletal remains are mostly complete but in a fragmentary state. The

burial is identified as an extended burial associated with miscellaneous adult long bone fragments. The individual is well-developed and robust for its age (see Functional Morphology). The remains range in color from yellow to brown, and plant root action is evident.

Age

Age for this individual is based on long bone measures and dental development. The humeri lengths are 67 mm (left) and 68 mm (right). The radii measure 54 mm in length, and the left ulna is 64 mm in length. The left femur measures 77 mm in length. All of these bone lengths fall in the newborn to six months age category. The maxillary second molar was cusp converged (code 02) corresponding to an age of newborn (NB) -.15 years.

Functional Morphology

This individual is very robust for its young age, and development of sites of muscle attachment is apparent. The humerus shows development for the attachment of deltoid, the radial tuberosity is developed, and the linea aspera on the femora are developed.

Extra Elements

- 1) Adult 2nd or 3rd metatarsal.
- 2) Adult vertebral rib end (3-10).

41RF1-BP22-004

This individual is an infant, aged newborn to six months (code 01), of indeterminate sex and ancestry. This burial was located above Burial 41RF1-BP22-001. The skeletal remains are mostly complete but are in a very fragmentary state. The remains range in color from yellow to brown, and plant root action is evident.

Age

Age for this individual is based on long bone measurements and dental eruption. The long bone measurements areas follows: femur = 69 mm, left tibia = 59 mm, right tibia = 60 mm, and fibula = 59 mm. These bone lengths correspond to an age of newborn to six months. Dental development is as follows: the mandibular canine is in initial cusp appearance, the mandibular first molars are cusp convergence, and the mandibular second molar is initial cusp appearance. These stages correspond to an age of newborn.

Extra Elements

- 1) Adult vertebral rib end from an upper rib.

41RF1-BP22-005

This individual is an infant, aged newborn to six months (code 01), of indeterminate sex and ancestry. The burial is identified as a scatter of bones uncovered by the grade-all trench. The skeletal remains highly fragmented and mostly incomplete. The bones range in color from yellow to brown, and root action is evident.

Age

Age for this individual is based on dental formation of the mandibular dentition. The mandibular canine is cusp initial (code 01), the first mandibular molar is cusps converged (code 02), and the second mandibular molar is cusp converged (code 02). These stages combined to give an age of NB-.15 years.

Pathology

This individual displays slight woven bone formation on the occipital, parietal, and temporal portions of the cranium, several of the plural rib surfaces, the left humerus, and the femora. Slight expansion of the outer cortex of these areas of the skull is seen in conjunction with the woven bone formation on the femora and the humerus. The periosteal reaction on the ribs and is characterized by woven bone formation which occurs on costal grooves. The effected cranial portions display woven bone formation that exceeds what is expected in normal growth. This can be interpreted as a systemic periosteal reaction.

Extra Elements

- 1) Adult right rib fragments.

41RF1-BP22-028

This burial is very fragmentary and incomplete. Because of the fragmentary condition, sex is estimated as possible male based on a small fragment of the pubic ramus. Age is determined only to be young adult. Only fragments of elements from the left side on the body are present. The bone is light brown to orange in color and exhibits some plant root damage.

A small flat and curved lead fragment is associated with the pelvic fragments. This lead piece measures approximately 20 mm by 14 mm. This burial had a lead ball associated with the pelvic area during excavation.

Dentition

Eight mandibular teeth are associated with the remains. No alveolar structures are present. Calculus deposits range from

flecks to heavy. The anterior teeth exhibit the greatest amount of calculus deposit.

41RF1-BP22-028A

From a Sort

This individual is an infant (newborn to 6 months) that was commingled with 41RF1-BP22-028. Age is estimated based on tibia length. The sex and ancestry are indeterminate. The lower legs, the right distal third of the femur, represent the burial. The bones are a dark brown in color.

41RF1-BP22-077

Present are the nearly complete skeletal remains of a male of probable Native American descent aged 45-49 years (code 26). Overall preservation is good, although most elements exhibit postmortem damage. Missing elements are limited to the left first and twelfth ribs, the seventh cervical, six thoracic, and two lumbar vertebrae.

Age

Age estimation is based on cortical and trabecular bone thinning, tooth wear, and presence of degenerative alterations. Both the cortical and trabecular bone of the long bones exhibit thinning, indicating an older individual. Similarly, the teeth of the maxilla and mandible display heavy wear, suggesting the individual to be an older adult. Degenerative alterations in the form of porosity and osteophyte development at joint surfaces also supports the age estimation of 45-49 years.

Ancestry

Ancestry was estimated to be probable Native American based on morphological features of the cranial and postcranial elements. Although the cranial material is highly fragmented due to postmortem damage, many morphological traits commonly associated with Native American populations can be appreciated. The zygomatics are flat and projecting. Similarly, when the facial elements are refitted the face is relatively flat. The heavy wear to the teeth also suggests the individual to be of Native American descent. Postcranial elements also indicate a Native American ancestry. The femora display pronounced platymeria, with a platymeric index score of 79.4, where any score under 85 is considered platymeric.

Sex

Estimation of sex is based on the overall size and morphology of the skeletal elements. The elements are generally large in

size with robust muscle attachments. The femoral heads measure 48 mm in diameter, placing the individual in the male range. The morphology of the skull, mandible and innominates also indicates the individual is male. The mastoid processes are large and the supra-orbital margins are thick and dull. Overall, the mandible is large and robust and exhibits a relatively square mental eminence. The innominates display a narrow greater sciatic notch. All of these features are characteristic of males.

Dentition

The dentition is nearly complete, with only the left maxillary third molar missing. Most teeth are in occlusion, only the first and second left maxillary teeth are lacking a socket due to postmortem damage. All teeth exhibit heavy wear (Stages 4-7), with the majority of the teeth having at least half of the crown worn down. A flat plane of wear is common for most teeth. Heavy calculus deposits are present on all of the teeth.

The right mandibular first and second molars each have a single small pit caries on the occlusal surface. Three periapical abscesses are evident. The right maxillary first premolar has abscessed, possibly the result of a fracture, with perforation of the alveolar bone just superior to the tooth. Postmortem damage to the area precludes measurement of the perforation. The right first mandibular molar has similarly abscessed with perforation of the alveolar bone inferior to the tooth. The tooth remains in the socket, however, the surrounding alveolar bone is noticeably altered and remodeled by the infection. Specifically, a large opening in the alveolar bone measuring approximately 5 mm in diameter is located just below the alveolar ridge and appears to be associated with the mesial root. The left mandibular second molar has abscessed with complete destruction of the surrounding alveolar bone. Although the socket was destroyed by the infection, it appears the tooth was held in place by the soft tissue and neighboring teeth.

In possible conjunction with the abscess of the left mandibular second molar, the distal aspect of the second molar and the mesial aspect of the third molar exhibit an interproximal groove just below the cemento-enamel junction. Several incidents of antemortem enamel chipping are also present. The buccal surface of the right first mandibular molar has a rather large chip from around the rim of the crown missing. The third right mandibular molar has an antemortem chip on the distal-lingual surface, and the left third mandibular molar has a chip off the mesial surface enamel.

Functional Morphology

This individual exhibits robust muscle attachment morphology of the arm and leg elements consistent with habitual lifting and walking. The humeri display pronounced deltoid tuberosities, indicating prolonged and frequent flexing of the shoulder or lifting of the arm. The lower arm elements exhibit morphology and muscle attachments suggesting robust muscle development. The right ulna displays medial bowing of the proximal shaft along with superior-inferior elongation of the radial notch, which is mirrored in the articular surface of the radial head. This morphology is likely functional rather than pathological, and there is no indication of fracture or other pathology. The morphology of the hip and leg elements indicates extensive and habitual walking. The left innominate displays slight elongation of the acetabulum, while the right acetabulum is not complete enough to assess. The femur exhibits well-developed and pronounced muscle attachments associated with muscles central in the motion of walking. The gluteal tuberosities and greater trochanters of the femora are large and well-developed. These are attachments for the gluteal muscles, which abduct and medial rotate the hip during walking. Similarly the linea aspera of the femora are elevated and well-developed. This is the attachment site of many muscles that work to laterally rotate the hip and extend the knee. Another feature associated with this individual is a squatting facet on the distal left tibia.

Pathology

This individual exhibits several different types of pathological changes including infection, degenerative joint disease, and a congenital abnormality. The signs of a generalized infection are healed patches of periostitis on the femora and left tibia. The femora have healed mild periostitis on the posterior surface along the linea aspera and on the popliteal surface. The left tibia also exhibits healed mild to moderate periostitis on the posterior surface of the mid and distal thirds of the shaft.

Degenerative changes are present at several joint surfaces. The temporomandibular joint (TMJ) of the right temporal bone exhibits mild porosity and erosion, and the right mandibular condyle displays similar mild porosity. The thoracic and lumbar vertebral elements exhibit osteophyte development. The upper thoracic (T3-T9) centra display mild marginal osteophyte development, while the lower thoracic (T10-T12) and lumbar centra have moderate marginal osteophyte development.

This individual also displays evidence of a congenital abnormality. Congenital radioulnar synostosis of the proximal left forearm (see Ortner and Putschar 1985:362) is evident. This bony ankylosis of the radius and ulna has resulted in the complete fusion of the elements at the site of articulation between the two, with obliteration of the radial head and deformity of the olecranon. The elements fused in the pronated position, with the radius crossing the ulna lateral to medial. The permanent pronation of the forearm has resulted in well-developed muscle attachments of the radius and ulna. The attachment for the pronator teres on the radius is especially well marked. The obliteration of the radial head has resulted in the expansion of the olecranon in the medial lateral plane. The distal articulation surface of the humerus has also been altered by the obliteration of the radial head. The capitulum of the humerus appears to have been remodeled out, and the trochlea has expanded to accommodate the olecranon.

41RF1-BP22-082

This individual is an adult male, aged 30-39 years (code 24) of Hispanic ancestry. Evidence of traumatic death is present in the form of multiple cutmarks associated with scalping (see Pathology section). The burial is identified as a primary extended burial. Bone preservation is very good, and the individual is well represented. The remains range in color from yellow to brown, and plant root action is evident. Green copper staining occurs on the left os coxa resulting from contact with copper buttons that were associated with the burial.

Age

Age estimation is based on pubic symphysis and auricular surface morphology and cranial suture closure. The pubic symphysis is consistent with a Todd Phase 7 and a Suchey-Brooks Phase 5. The auricular surface is consistent with a Lovejoy Phase 3. The ectocranial sutures range from less than 50 percent to more than 50 percent closed. The endocranial sutures range from partially closed to obliterated. Based on these observations, the age is estimated as 30-39 years.

Ancestry

Estimation of ancestry is based upon the absence of shovelings on the incisors and platymeria on the femora. A limited set of craniometric data were available and were applied to DISPOP, a custom discriminant function analysis. The results indicate the individual classifies close to European groups as well as close to Native American groups. These criteria suggest possible admixture between the two groups.

Sex

Sex is estimated as male based on innominate morphology and general robusticity of the elements. The sub-pubic angle is narrow, the ischio-pubic ramus ridge is wide, the greater sciatic notch is moderate to narrow, and the auricular surface is flattened. Muscles attachments are moderately developed. These traits all suggest the designation as male. The diameters of the femoral head (45 mm) and humeral head (44 mm) are ambiguous as to sex. Cranial morphology and overall postcranial size are also ambiguous as to sex.

Dentition

The dentition for this individual is mostly complete. Caries are present on two teeth including a slight pit caries on the left mandibular third molar and a buccal/interproximal caries with root involvement and pulp exposure on the mandibular left second molar. A periapical abscess has resulted from the pulp exposure on this second molar.

Significant alveolar resorption has occurred on the buccal sides of the mandibular first molars. Although not scored, periodontal abscessing is suspected with concomitant periodontal pocket formation. The right mandibular first molar likewise displays pocket formation, however this may be the result of drainage from the periapical abscess. Overall the dentition displays moderate alveolar resorption. Calculus formation occurs along a normal gingival margin despite the alveolar loss. It ranges from flecks to coalesced with the heaviest deposits occurring on the mandibular incisors, canines, and premolars. Wear is moderate with the heaviest wear occurring on the incisors and canines. Both maxillary third molars and the right mandibular third molar are congenitally absent.

Functional Morphology

This individual displays an overall moderately developed postcranial skeleton. The attachments for pectoralis and deltoid muscles on the right and left clavicles are marked. The humeri display marked attachments for the pectoralis major, teres major, deltoid and triceps muscles. The pronator teres attachment and interosseous crest are marked on the radius.

The attachments for the gluteal and adductor muscle groups on both femora are marked. The tibia displays marked development of the attachment the soleus muscle and interosseous crest.

Pathology

This individual displays localized, slight, healed ectocranial porosis on the right and left parietals and the occipital. The right humerus displays slight marginal osteophyte formation on both the proximal and distal joint surfaces, and the right ulna displays slight marginal osteophyte formation on the proximal joint surface.

Slight marginal osteophyte formation is present on the distal femora, both patellae, proximal and distal surfaces of the right tibia, and on the calcaneus.

This individual experienced a traumatic death. A total of forty-nine cuts around the crania indicate scalping occurred at or near the time of death. The frontal bone exhibits twelve cuts that range in length from 4 mm to 24 mm. These cutmarks predominantly occur high up on the forehead in a horizontal direction. The left parietal has sixteen cuts proceeding from the temporal line back towards asterion. There are also a set of cuts proceeding across the sagittal suture at the mid-sagittal area, these cuts could of resulted from a secondary cut made at the time of death possibly to release the scalp from the crania. The right parietal has seven cuts proceeding from asterion to the coronal suture. The occipital has fourteen cuts located above the nuchal region proceeding basically from left asterion to right asterion.

41RF1-BP22-084

This individual is an infant age .25-.4 years (code 01) of indeterminate sex and ancestry. The remains comprise a secondary scatter of bone located south of Burial 1. The remains range in color from yellow to brown, and root action is evident. The maxillary central incisor shows no signs of shoveling, and the maxillary lateral incisor shows a slight degree of shoveling. The remains are fairly complete, but highly fragmentary.

Age

Age for this individual was based on dental development. Development of the mandibular canine and second molar are crown ½ formed (Stage 3), and the mandibular first molar crown has completed development (Stage 5). These stages correspond to an age of .25-.4 years. The long bones were too fragmentary to permit measurement.

Pathology

The long bones and right innominate show systemic mild periosteal reaction.

41RF1-BP22-091

This individual is a male, aged 40 to 50 years (code 26), of Native American ancestry. The skeleton is fragmentary, but the long bones are relatively complete. The cranium and innominate are poorly preserved. The bone is orange brown in color with areas of water damage on most elements. In addition, the bone exhibits evidence of root damage.

Age

The age is estimated based on the degenerative joint disease, dental wear, and the pubic symphysis morphology. Slight osteoarthritic lipping is evident in all major joints and the lumbar vertebrae. Dental wear is moderate with heavier wear on the anterior dentition. The pubic symphysis is completely rimmed with slight lipping along the dorsal margin and small areas of erratic ossification on the symphyseal face. These morphological and degenerative characteristics suggest an age range of 40 to 50 years.

Ancestry

Ancestry of this individual is estimated as Native American. This assessment is based on extreme platymeria, small squatting facets, and an overall robust nature of the bones. The femoral shafts are extremely anterior-posterior flattened with an enlarged medial margin of the shaft. The midshaft measurements fall within the platymeric range (platymeric index = 77.7) defined in Bass (1995). These characteristics are indicative of Native American ancestry.

Sex

The sex determination is based on pelvic morphology and overall skeletal robusticity. The ventral arc is absent, the subpubic concavity is slight, and the ischiopubic ramus is broad and rounded. Overall skeletal size is large and robust. These characteristics are consistent with a male individual.

Dentition

The teeth are well represented, but the alveolar structures are fragmentary. The teeth exhibit moderate to slight wear. Wear on the incisors and canines is greater than the molars. A large carious lesion has destroyed the entire crown of the upper right third molar. An interproximal caries is present at the CEJ on the distal side of the maxillary right second molar. A small interproximal groove is also present at this location and overlaps the carious lesion. Calculus ranges from slight to heavy with the lower dentition and the upper molars having the heaviest deposits. The lower incisors have an sloped wear, which resulted from mal-alignment of the teeth and the presence of a peg lateral incisor.

Three teeth have small enamel fractures. Breaks on the upper left central incisor and lower right lateral incisor are on the distal occlusal margins. The fractures on the lower right first molar are present at the occlusal edge on the mesiolingual and distolingual corners of the crown.

Functional Morphology

This individual is moderately robust with marked muscle attachments. The deltoid insertion on the humeri and the various muscle attachments of the proximal humeri are all well-developed. The linea aspera of the femora are also well-developed. Slight enthesophytes are present on the posterior surface of the calcanei at the Achilles tendon insertion.

Pathology

Skeletal pathology is limited to slight ectocranial porosity and degenerative changes. Mild ectocranial porosity is present on the parietals. The pitting is well demarcated by the margins of the temporalis fascia. Mild marginal osteophytosis is present in a lumbar vertebra. Degenerative evident in a lumbar vertebra include mild surface porosity and marginal lipping of the centrum. The effected element appears to be the fifth vertebra. Very slight changes are evident on the promontory off the sacrum.

Slight marginal osteoarthritic lipping is present on the joint surfaces of the distal humeri, proximal left ulna, proximal left femur, distal femora, and both articular surface of the tibiae. Mild subchondral osteophytes are present on the proximal right femur head.

41RF1-BP22-097

This individual is an adult male, aged 25-30 years (code 22), of indeterminate ancestry. This burial is identified as articulated and extended in Feature 22. The legs are complete, but the arms and crania are highly fragmented. Preservation ranges from good to poor, and water damage is evident on the humeri, radii, and ulnae. The remains range in color from yellow to brown, and root action is evident.

Age

Age for this individual is based on pubic symphysis morphology. The pubic symphysis is consistent Todd's Phase 5 and Suchey-Brooks' Phase 3. These phases correspond to an age of 27-30 years. Also, the lack of any degenerative joint disease on the majority of postcranial elements (see Pathology section) supports a young adult estimate of age. All of these criteria support an estimated age range of 25-30 years.

Ancestry

Ancestry is estimated as possible Native American. The incisors exhibit slight shovel-shaped morphology; however, the femora are not platymeric. These features are indicative of possible Native American or admixed ancestry, however, the ancestry estimate is indeterminate.

Sex

Sex estimation is male based on the pubic bone morphology and overall robusticity of the postcranial remains. The pubic bone is narrow, and the elements are relatively large and robust.

Dentition

The dentition for this individual is mostly complete, with the exceptions of the lower right and left central incisors and the lower left lateral incisor. Dental wear is light to moderate with some dentin exposure, mostly on the anterior teeth. Calculus deposits range from moderate to coalesced on both the maxillary and mandibular dentition. Enamel chipping is evident on the maxillary right second premolar and first molar, maxillary left canine, mandibular right first premolar and second molar, and the mandibular left second premolar.

Functional Morphology

This individual has a generally large, but only moderately developed postcranial skeleton. The occipital region displays a robust occipital protuberance. The humeri display moderately developed attachments for the deltoid muscles.

The femora display moderately developed attachments for the gluteal muscle group, adductor longus, and adductor brevis. As a result of the developed adductor muscles, the femora are anterior-posterior elongated, with a linea aspera depth measure of 10 mm on the left and 13 mm for the right. The tibia shows moderately developed attachments for soleus. Both the tibia and fibula show well-developed interosseous crests.

Pathology

This individual has slight porosity on the inferior articular facet of C3-7, with only one vertebrae being affected.

Schmorl's depressions are present on first through fourth lumbar vertebrae. The widths and lengths of each defect are presented in Table IIA-12.

Table IIA-12. Description of Schmorl's depressions from burial 41RF1-BP22-097

Location	Width (mm)	Length (mm)
L1 superior	8.7	7
L2 superior	9.6	6
L3 superior	11.4	7.51
L3 inferior	3.6	2
L4 superior	5	5

Perimortem trauma is present in the form of fractures of the left tibia and fibula. The left tibia exhibits a comminuted fracture with an accompanying butterfly fracture of the anterior crest. Radial fracture lines are present proximal-medial, anterior-proximal, lateral-posterior, and distal-medial in relation to the fracture, and the entire middle third of the bone is affected. Eight separate fragments result from the fracture, of which two display radial fracture lines. Marked bone peeling is associated with the anterior portion of the fracture. The proximal fibula also displays a perimortem fracture with a slight radial fracture line anterior-lateral. Slight medial peeling is present at the distal end of the fracture. This fracture most likely occurred in conjunction with the tibial fracture. The fracture appears to have resulted from blunt trauma directed to the lateral portion of the tibia.

41RF1-BP22-107

This individual is an adult male, aged 20-24 years (code 21), of possibly Native American ancestry. The burial is identified as extended and articulated in Feature 22. This individual died a traumatic death caused by blunt trauma to the frontal bone. The resulting fractures and brain trauma are discussed in the Pathology section.

Green staining is present on the anterior iliac crest, most likely from the buttons that were associated with the burial. All elements are highly fragmentary, and bone preservation is quite poor. The skeletal elements may have been exposed to water as suggested by the brown coloration and splitting of the cortical bone. The remains range in color from brown to dark brown, and root action is evident.

Age

Age is estimated based on pubic symphysis and auricular surface morphology, dental attrition, and cranial suture closure. The pubic symphysis morphology is consistent with a Todd Phase 3 and Suchey-Brooks Phase 2. The auricular surface morphology is consistent with a Lovejoy

Phase 1. The teeth exhibit slight to moderate dental wear. The anterior cranial sutures are partially fused (< 50 percent), the lambdoidal suture is open, and the endocranial sutures are all partially fused. The combination of these traits suggests an age range of 20-24 years.

Sex

Sex for this individual is male based upon the morphology of the nuchal crest, mastoid process, supra-orbital area, mental eminence, and humeral head diameter (49 mm). In addition, the postcranial remains are robust and well-developed.

Dentition

This individual displays slight to moderate dental attrition with the heaviest wear on the maxillary canines and mandibular first molars. Calculus deposits range from moderate to three-dimensional. The mandibular dentition has the heaviest deposits of calculus. Caries are present on the buccal aspect of the maxillary left third molar, with pulp exposure. Also the right second mandibular premolar displays caries interproximally with root involvement and pulp exposure, and the first right mandibular molar displays caries with pulp exposure and root involvement on the occlusal surface with the interproximal area also affected.

Linear enamel hypoplasias occur on the maxillary incisors and canines, and the mandibular canines. Several teeth display enamel chipping including the second maxillary premolar, right maxillary canine, right maxillary central incisor, and the left mandibular first molar.

Functional Morphology

The humerus displays well-developed attachments for the deltoid and brachioradialis muscles. The radius and ulna both display well-developed interosseous crests, developed attachments for pronator teres. The radius exhibits marked development of the attachments for flexor carpi radialis longus and brachioradialis.

This individual displays squatting facets on the anterior distal tibia.

Pathology

This individual died a traumatic death. Evidence of a traumatic death is found on the cranial vault, which displays cut marks indicative of scalping. Cuts are present on the frontal, both parietals, and occipital. The frontal has two cuts along the left inferior temporal line measuring 6.4 mm and 11.8 mm, respectively. The right parietal has eight

cutmarks located anterior near the insertion for temporoparietalis and temporalis, and ranging posterior and medial. A few of these cut marks display a rocking action and repeated strokes with a knife producing multiple grooves per cut. The left parietal has two cuts near the sagittal suture. The occipital has three cuts near the left mid lambdoidal suture, starting inferior and moving superior along the suture.

In addition to the cutmarks, a fracture of the frontal bone occurred perimortem. The nature of the fracture indicates a blunt force trauma with penetration into the braincase. Five radiating fractures are associated with the main force. Three of these proceed inferior toward the inferior temporal line on both the right and left side, and the third descends toward the right orbital border, the fourth fracture line ascends to and terminates at the intersection of the sagittal and coronal sutures, and the fifth fracture line ascends to and terminates midway between the left inferior temporal line and bregma. External beveling occurs around the initial impact area and also along the superior fracture lines. Several teeth display perimortem fractures of the crowns and roots including the maxillary right lateral incisor and the left central and lateral incisors. The fracture of the right lateral incisor exhibits peeling of the buccal surface of the crown extending up the tooth root. The left central incisor fracture also displays some buccal peeling, but it is not as extensive as the lateral. The left lateral incisor displays a similar pattern as the right lateral incisor with extensive buccal peeling of the tooth root.

41RF1-BP22-109

Present is an adult female, aged 30-35 years (code 23) of Native American ancestry. This burial was identified from a sort of elements located at feet of Burial 107. The remains are very fragmentary, and some elements appear to have water damage. The color of the remains ranges from yellow to brown, and root action is evident.

Age

Age for this individual is 30-35 (code 23), based on pubic symphysis and auricular surface morphology. The pubic symphysis is a Todd Phase 6, and a Suchey-Brooks Phase 4. The auricular surface is a Phase 3. These scores combine to give the range of 30-35 years.

Ancestry

Estimation of ancestry as Native American is based on dental, craniofacial, and postcranial features. The dentition displays the presence of moderately shoveled incisors and barrel shaped maxillary lateral incisors. The face lacks a nasal sill.

Slight squatting facets are expressed on the tibiae. All of these features are associated with Native American ancestry.

Sex

Sex estimation is based on the morphology of the innominate and joint size. The subpubic concavity is wide, and the ischio-pubic ramus is slight. The femoral head diameter measures 41 mm, and the humeral head diameter is 41 mm. These characteristics are consistent with females.

Dentition

A small carious lesion is present on the maxillary right third molar. Calculus formation is light to moderate. The mandibular dentition displays heavier deposits than the maxillary dentition. Enamel chipping occurs on the maxillary left second premolar and the mandibular left canine. Dental attrition is generally light to moderate.

Functional Morphology

This individual displays a developed postcranial skeleton with the following elements showing enlarged muscle attachments: deltoid tuberosity and medial epicondyle on the humerus, radial tuberosity and attachment for pronator teres on the radius, attachment for triceps brachii, biceps brachii, and brachialis on the ulna.

Pathology

This individual displays slight porosity on the inferior articular facet of the fifth lumbar vertebra. Spondylolysis has occurred on the fifth lumbar vertebrae where the inferior portion of the lamina has separated from the vertebral body. As a result of this separation, the posterior portion of the centrum has compressed and is visible when comparing the anterior centrum height of 25 mm verses the posterior centrum height of 18 mm.

The right tibia and fibula exhibit fractures that were healing at the time of death. The fracture of the tibia occurs at midshaft or possibly the distal $\frac{1}{3}$ of the shaft. The exact location of the fracture is not discernible due to the fragmentary nature of the bone. An enlarged callus has formed around the fracture area, and evidence of repeated post-episodic fractures of the callus is present. The fracture to the fibula also occurs in the middle $\frac{1}{3}$ – distal $\frac{1}{3}$ area of the bone where callus formation occurs around the area of the fracture. It is possible that multiple fractures occurred during the fracture episode. Other fragments from more proximal portions of the bone display callus formation.

41RF1-BP22-112

This individual is a late adolescent to young adult male, aged 16 to 19 years (code 18) of Native American ancestry. The individual is a primary extended burial, and a majority of elements are represented. Bone preservation is good, but most elements are fragmented. The color ranges from yellow to brown, and root action is evident.

Age

The age estimate is based on dental development and epiphyseal fusion. The third molars are in occlusion and almost completely erupted. The apex of the third molar roots is fully formed. The pattern of epiphyseal fusion appears younger than the dental development. The sternal body sections are partially fused. The proximal humerus, distal ulna, distal radius, and proximal tibia exhibit only epiphyseal fusion lines. The iliac crest and ischial tuberosity epiphyses are partially fused. This pattern of dental development and epiphyseal fusion is consistent with a late adolescent or young adult, probably between 16 to 19 years old.

Ancestry

This individual is probably of Native American decent. The proximal femoral shafts exhibit slight platymeria, and the anterior teeth are slightly shoveled. These traits are both associated with Native American populations. Finally, the craniometric data, which indicate a large face with a short cranial length, are consistent with American Indian populations.

Sex

The sex determination is based on the evaluation of various morphological traits of the pelvis and cranium. Overall, the postcranial skeleton is relatively small. However, the face is quite robust, and the auricular surface morphology is flat. In addition, the teeth are quite large. These traits are all consistent with a male individual.

Dentition

The dentition is nearly complete, missing only the upper right first premolar. The alveolar structures of the posterior maxilla and the entire mandible are fragmentary. No caries lesions are present, but the socket of the maxillary right first premolar (tooth missing postmortem) is expanded. The socket margins are porous and reduced suggesting the presence of a periapical abscess with apical discharge. A small occlusal margin enamel fracture is visible on the maxillary right second premolar. Numerous linear enamel hypoplasias are present on the anterior teeth.

Function Morphology

The left arm is visibly smaller and less robust than the right arm. This asymmetry resulted from the fracture of the left distal humerus, proximal ulna, and proximal radius. The breaks destabilized the joint causing greater lateral movement of the lower arm elements (see Pathology description).

Pathology

Numerous healed fractures are present in the left elbow. The distal joint and metaphysis of the left humerus, the coronoid process of the ulna, and head of the radius are fractured. The fractures are contemporaneous as a result of a compressive force directed proximally through the lower elements of the arm into the distal humeral joint. The trauma has resulted in severe modifications and increased lateral movement of elbow joint.

The distal humerus articular surface is bifurcated and malformed. A compression force, directed up from the radius and ulna, has fractured the lateral aspect of the distal metaphysis and epiphysis. A healed fracture extends along the anterior surface from medial margin of the capitulum to the lateral margin of the metaphysis (4.5 cm from the distal end of the capitulum). The central portion of the distal articulation was severely damaged and may have necrosed. The subchondral bone of the trochlea and capitulum is irregular. Osteoarthritic changes in the joint include mild surface osteophytes and surface porosity. The stability of the joint has been greatly reduced as a result of the bifurcated articulation, which allows lateral movement of the ulna and radius.

The proximal ulna has a healed incomplete fracture of the coronoid process. The trauma has affected the morphology of process, joint surface, and the radio-ulnar articulation. The articular surface of the coronoid process is concave and roughened to accommodate the modified trochlea of the humerus. The radial notch on the ulna is concave and irregular with mild marginal lipping on the posterior border and mild surface porosity.

The radius has a incomplete compression fracture of the radial head. The fracture has healed, but the radial head is enlarged and irregular. The surface of the head is relatively flat and posteriorly elongated. The ulnar articular surface on the margin of the head is damaged postmortem. The compressive trauma may have fractured the proximal epiphysis during fusion.

Bilateral slight cribra orbitalia and porotic hyperostosis is present. The anterior margins of the orbits exhibit mild porosity with slight bony expansion. Slight expanded areas of porous bone are present on both parietals near the lambdoidal suture superior to the temporal line. On the left parietal, slight surface porosity extends along the temporal line to the coronal suture. The maxillae and zygomatics exhibit active surface porosity. The zygomatics exhibit porosity on the orbital and external surface with slight bony expansion near the infraorbital canals and the zygomatico-orbital foramen.

Slight healed periostitis is present on the shafts of the fibulae and on the midshafts of the tibiae. On the fibulae, sclerotic bone deposits are widespread and extend along the interosseous crest; whereas, the tibial lesions are localized near the midshaft.

41RF1-BP22-116

Present is a male, aged 55+ (code 29) of indeterminate ancestry. This burial is represented by very fragmentary skeletal material. The majority of the skull was removed earlier during the intrusion of a pipe trench. The legs seemed to have been disturbed by later burials. The burial located in the foot region of this burial, 41RF1-BP22-107, does not include any extra elements that can be associated with this burial.

Several of the bone fragments exhibit a rust colored staining. Three rib fragments exhibit this staining on the visceral surface and superior and inferior edges. A small tibial crest fragment also exhibits a darker rust colored stain.

Age

The age of this individual is estimated as 55+ (code 60+) based on advanced morphological change of the pubic symphyses and auricular surface and the severe osteoarthritis of the elbow joints and lumbar vertebrae.

Sex

Sex is estimated as male based on the narrow pubic morphology as well as the large size of the distal humerus and proximal ulna.

Functional Morphology

Although the humerus is extremely fragmentary, moderate development of the deltoid attachment is evident. Six carpals are present all exhibiting slight osteoarthritic lipping.

Pathology

The lumbar vertebrae exhibit severe porosity of the endplates and margins of the centra. The margins also exhibit severe osteophytic lipping and expansion.

The distal left humerus, proximal left and right ulna, and distal left radius all exhibit slight to moderate lipping and porosity on the joint surfaces and margins.

The right femur exhibits moderate porosity and eburnation on the proximal and distal joint surfaces. The proximal right tibia has corresponding porosity and eburnation on the condyles. The left distal femur and tibia display slight arthritic changes on the distal ends.

41RF1-BP22-117

This individual is a female, 60+ years (code 29), of Native American or Hispanic ancestry. The remains are fragmentary with most of the elements being represented, and the color ranges from light to medium brown. The head end of the burial was disturbed previously during the excavation of a pipe trench. Despite this intrusion, a portion of the cranium was sorted from a burial (41RF1-BP22-127) located just west of this burial. This sort was based on the obvious age and size differences.

Age

Age is estimated based on the brittle and osteoporotic condition of the bones.

The auricular surface is consistent with a Lovejoy Phase 6, which indicates a range of 45-49 years. However, the joint surfaces and the friability of the bones support the upper age estimate. The cranial sutures that are present are mostly obliterated.

Ancestry

The only feature to indicate ancestry is the anterior fragment of the maxillae that includes the inferior nasal border. The border lacks a sharp sill or spine. The alveolar portion exhibits a shelf like depression inferior to the nasal border. This feature eliminates a European ancestry; however, it does not allow clear distinction between Native American and Hispanic ancestry.

Sex

Sex is estimated as female based on the small and gracile nature of the postcranial elements. The right innominate is

present but highly fragmented. However, a portion of the preauricular sulcus shows a deep broad sulcus. This feature may be linked to childbirth.

Dentition

Only the anterior portion of the maxilla is present. The central incisors were lost antemortem, and the alveolus has completely resorbed. The left and right lateral incisors and right canine sockets exhibit evidence of abscessing, however the teeth are missing postmortem.

Functional Morphology

The left distal humerus exhibits a supracapitular notch for the articulation of the radial head indicating habitual tight flexion of the left elbow. Pathology may have resulted in the absence of this flexion in the right elbow, however, it is not possible to eliminate.

Pathology

This individual was scored for generalized osteoporosis. The bones are light and are rather brittle.

The occipital exhibits slight localized active periostitis. This bony development maybe related to age.

The vertebrae were in poor condition, and only a few were complete enough to examine for pathology. A thoracic vertebra (T1-9) exhibits a compression fracture with an associated Schmorl's depression. The Schmorl's depression is located on the inferior endplate and is oval in shape measuring 11 mm anterior-posteriorly, 14 mm medio-laterally, and 5.4 mm in depth. The thoracic vertebrae were scored for moderate osteophytic lipping and porosity on the centra, and moderate porosity on the facets. Two small fragments of the sacrum show moderate porosis on the promontory.

The left and right distal humeri exhibit slight marginal lipping of the joint surface, while the left distal joint surface has slight porosity on the surface. The left humerus exhibits slight healed areas of periostitis along the shaft. The right distal radius exhibits slight marginal lipping.

The proximal third of the right radius and ulna exhibit well-healed complete fractures. The proximal end of the radius has atrophied considerably, and the ulna shows thickening of the shaft. The radial tuberosity, which serves as the attachment site for the biceps brachii muscle, is greatly reduced to only a ridge of bone. This suggests that

attachment of the biceps brachii muscle was most likely interrupted at the time the fracture was induced. As the fracture healed and remodeled, the tuberosity was reduced to a ridge. Distally, the radius appears relatively normal with slight irregularity of the cortex. This may be due to long healed periostitis. The appearance of the distal $\frac{2}{3}$ of the radius and distal joint indicates that no other muscles were involved in the trauma. The ulna is not affected by the biceps brachii and does not show similar atrophy. The elbow joint does not exhibit the same habitual tight flexion as the left elbow, suggesting that the arm was not as heavily used.

The right iliac crest shows slight development of enthesophytes.

The left femur exhibits localized areas of slight healed periostitis.

41RF1-BP22-117A

From a Sort

The remains of an infant, aged newborn to .5 years (code 01) were sorted from commingled remains in Feature 22. A few long bone fragments, rib fragments, and one vertebra represent the burial. Age is estimated as newborn based on the very small size of the remains. The remains are very fragmentary, the color ranges from yellow to brown, and plant root action is evident.

Pathology

The tibia fragment displays an area of active periostitis.

41RF1-BP22-121

This burial represents an infant, aged newborn to 6 months (code 01), of indeterminate ancestry. The skeletal material is fragmentary. Approximately one-quarter of the skeletal elements are represented. All but one of the vertebral centra are present. The bone is yellow to brown in color and in fair condition. No dental remains are present and pathological lesions are absent.

Age

Age is based on the diaphyseal lengths of the left femur (75 mm) and the right humerus (65 mm). These lengths correlate to an age of new born to 6 months.

41RF1-BP22-127

From a Sort

This individual is a male, aged 30-39 (code 23), of possible Native American ancestry. These remains were commingled with 41RF1-BP22-109 and several extra elements that are coded as ossuary elements (41RF1-BP22-I01R, 41RF1-BP22-S01C, 41RF1-BP22-F01R) as well as an immature scapula fragment. The skeletal elements that represent this individual are mostly appendicular. The bones are medium to dark brown in color, and the cortex has slight plant root damage.

Age

The age of this individual is estimated using the auricular surface morphology as well as the presence of only slight osteoarthritic changes on the joint surfaces. The partial left auricular surface exhibits slight to moderate activity in the retroauricular area as well as at the apex. The morphology is consistent with a Lovejoy Phase 5 suggesting an age range of 40-44. However, the other elements exhibit no osteoarthritic changes with the exception of the right proximal humerus, which has only slight lipping on the margin of the joint. The bones are dense, and the cortex is smooth. Using a combination of these age indicators, age is estimated as 30-39 years.

Ancestry

Ancestry is estimated as possible Native American. This assessment is tentative based on the moderate platymeria seen in the left femur, presence of a slight squatting facet on the right tibia, and the overall robusticity of the elements.

Sex

Estimation of sex is based on the robusticity of the elements. The humeral head measures 50 mm in diameter. This is well within the male range.

Functional Morphology

The right distal ulna exhibits moderate development of the attachment for pronator quadratus.

The left femur exhibits slight to moderate roughening of the attachments for the gluteal muscles. The right distal tibia exhibits a small squatting facet.

Pathology

The right proximal humerus has slight osteoarthritic lipping along the joint margin.

The fourth or fifth lumbar is represented by the right superior facet and transverse process. A modified facet is located inferiorly to the superior facet indicating possible fracture and separation of the lamina or spondylolysis. As this portion of bone was held in place by muscles, a pseudo articulation formed as the fractured portion continued to move in articulation.

The left tibia is represented by the distal one third. This bone shows a possible fracture. The fracture is well-healed. Because this bone is fragmented, a view of the cross section reveals a nearly filled in medullary cavity. The bone was also scored for slight healed and localized periostitis and enthesophyte development.

41RF1-BP22-129

Present is an adolescent male, aged 14-17 years (code 17) of Hispanic ancestry. This individual is recognized as a primary articulated burial and is complete and well preserved. The color of the remains ranges from yellow to brown, and root action is evident.

Age

Age for this individual is based upon dental development and epiphyseal closure. The upper second premolar is apex complete, the upper second molar is apex ½, and the upper third molar is root ½. This range corresponds to an age of 12-16 years.

Epiphyseal closure was assessed on the long bone elements, vertebrae, sacrum, and innominate. The long bone epiphyses located at the shoulder and knee are open, those located at the elbow are closed, and the others are in the process of fusion. The vertebral rings and iliac crests are unfused. These stages of development suggest an age range of 14-17 years.

Ancestry

Ancestry is estimated to be Hispanic. The upper or lower incisors lack shoveling, and a slight nasal sill exists on the nasal border.

Sex

Sex estimation is based mainly upon innominate morphology. The gracile nature of the cranial and postcranial remains most likely results from the individual's young age. The ventral arc, subpubic angle, sciatic notch, and auricular surface were all indicative of male. The humeral and femoral head diameters are 44 mm and 45 mm, respectively. While these dimensions are intermediate with regard to sex, the individual had not reached full growth.

Dentition

The dentition for this individual is mostly complete. Wear is slight, with the heaviest wear being on the first molars. Calculus is light to moderate on the maxillary dentition and mandibular molars, and heavy on the mandibular incisors, canines, and first premolars. There is a series of enamel hypoplasias on the upper and lower incisors and canines, which run parallel across the dentition. Also, slight hypoplasias are present on the first maxillary and mandibular premolars.

Functional Morphology

This individual displays slight development of the deltoid attachment on the humeri, and squatting facets are present on both distal tibia.

Pathology

This individual displays slight lipping of the 10-12 thoracic and 1-5 lumbar vertebrae, which is quite unusual for an individual of this age. This could be caused by unusually heavy strain being placed on the vertebrae.

This individual also displays a moderate periostitis and bone deposition of the left distal posterior surface of the femur. The periosteal reaction is localized to the distal/posterior surface and was active at the time of death. This could have resulted from a tear of the gastrocnemius muscle, which attaches in the area where the periostitis occurs.

Extra Elements

- 1) One adult lumbar vertebrae.
- 2) One adult thoracic vertebrae.
- 3) Two partial adult sacrum.
- 4) Nine adult rib fragments.
- 5) One adult left navicular.

Burial Feature 23

41RF1-BP23-023

From a Sort

This individual is an adult male, age 25-34 years (code 23), of Native American ancestry. The burial consists of disturbed disarticulated elements recovered from a feature west of a historic pipe trench that cuts across the site. The feature is adjacent to Burial Feature 15, but the remains did not belong with any individual from that feature. A minimum of two individuals is represented. The primary individual is extremely fragmented and consists of the upper axial elements and upper limb bones. The left half of the mandibular body is present with several teeth, but only one

cranial fragment is present. The extra elements represent the left arm and one tooth from a gracile female. The bone is in good condition. Surface color ranges from the typical light brown to yellowish brown. Rodent gnawing is evident along the proximal third of the left ulna. Two gnawing areas are located on the shaft, and these are not focused on bony ridges or the interosseous crest. The marks are not consistent with typical surface rodent gnawing but may be associated with subsurface gnawing.

Age

The age estimate is based on a series of secondary age indicators because no pelvic or cranial indicators are available. The sternal rib morphology is moderately U-shaped with rounded irregular margin. These characteristics are consistent with Stage 4 of Iscan's system. Dental attrition of the posterior teeth is moderate. Vertebral osteophytosis and osteoarthritic activity is slight to moderate. This pattern of skeletal morphology is consistent with a mature adult between 25 and 34 years.

Sex

This individual is classified as male. The overall body dimensions are robust, but they were not extremely large. Locations for muscle attachments are well marked.

Ancestry

The ancestry is estimated as Native American. The overall postcranial morphology is robust. The teeth are large and display numerous enamel chips. The robust postcranial remains are consistent with historic descriptions of Karankawa males.

Functional Morphology

The arms display well-developed attachment sites. Bony ridges on the distal humerus shaft correlate with the brachioradialis and the various extensors on the lateral epicondyle. The attachment sites of the supinator, brachialis, pronator teres, and flexor pollicis longus muscles on the proximal ulna shaft are well-developed. In addition, the pronator quadratus attachment on the distal ulna shaft is well marked. The development of these muscles suggests that this individual was habitually flexing and extending their arms in a pronated and/or supinated position, possibly with heavy loads. The metacarpals and palmar surfaces of the phalanges also display well-developed muscle attachments, which is consistent with the muscle development of the humerus and ulna.

Dentition

The left posterior dentition is well represented. The mandibular and maxillary molars and premolars are in occlusion and moderately worn. Carious lesions are absent, and no hypoplastic defects are evident. Calculus ranges from flecks to heavy deposits.

Interproximal grooves are present the upper left premolars and both lower second premolars. The grooves are slight and are not correlated with carious lesions. Several of the teeth display enamel chipping. The maxillary left first molar has a moderate sized defect on the mesial surface, and the mandibular left lateral incisor and canine have small chips on the occlusal surface.

Pathology

Pathological lesions are limited to degenerative joint disease of the vertebral column and on the distal ulna. Moderate marginal lipping and surface porosity are evident on the articular facets of the lumbar vertebrae. Small localized areas of eburnation are present on several facets. Two upper lumbar vertebrae display small linear Schmorl's depressions on the inferior centrum surfaces. These defects are 3 mm in width and extend 8 mm to 14 mm in length. Both depressions are centrally located approximately 9 mm from the posterior border of the centrum. These defects are associated with slight marginal lipping on the lumbar series.

The distal ulna articulation displays slight marginal lipping.

Burial Feature 24

41RF1-BP24-037

From a Sort

This individual is a young adult male aged 18 to 20 years (code 20) of possible Native American ancestry. The disturbed burial is associated with burials 41RF1-BP24-080 and 41RF1-BP24-085, and the remains are mostly complete, but very fragmentary. The individual was sorted based on the larger, younger postcrania, and less worn dentition. The remains range in color from yellow to brown. Water damage is evident on the femora and tibiae, and plant root action is evident most of the elements.

Age

Age estimation is based on unfused epiphyses on several elements. The superior epiphyseal rings on the cervical vertebrae are partially fused, the superior and inferior

epiphyseal rings are partially fused on the thoracic and lumbar vertebrae. The first and second sacral segments are partially fused. The proximal humerus and distal fibula are partially fused.

Ancestry

Ancestry is possibly Native American based on the robust nature of the postcranial remains, which is typical for Native Americans in this series. Also, the upper central incisor displays moderate shoveling, and the mandibular incisors exhibit slight shoveling.

Sex

Sex is estimated as male based on a number of features. The nuchal crest and mastoid process are large, supra-orbital margins are blunt, and the supraorbital ridge is large. The mandible exhibits a prominent and squared mental eminence. The femoral head measures 51 mm in diameter. These features are all masculine.

Dentition

The dentition is mostly complete. The overall wear is moderate, with the heaviest wear on the maxillary incisor. Calculus deposits range from specks to coalesced, with the heaviest deposits on the mandibular anterior dentition. Linear enamel defects are present on the maxillary central incisor, the maxillary and mandibular canines, and maxillary premolars.

The maxillary left lateral incisor is fractured, however, it is most likely associated with the original disinterment of the individual. The maxillary left canine has enamel chipping.

Functional Morphology

This individual displays a very well-developed postcranial skeleton. The clavicle shows a marked attachment for deltoid. The attachments for pectoralis major, deltoid, and triceps are moderately developed on the humerus. The ulna displays marked attachments for pronator quadratus and brachialis, and the radius is moderately developed at the attachments for pronator teres and the radial tuberosity.

41RF1-BP24-068

The burial represents an adult female, aged 35 to 44 years (code 24), of Native American ancestry. This individual was in an extended position with the arms folded across the chest. Burial 41RF1-BP24-080 and 41RF1-BP24-085 are commingled above the lower limbs of 41RF1-BP24-068, and a pipe trench cut through the commingled burials and both

tibiae of 41RF1-BP24-068. The skeleton is well represented but fragmentary.

Age

The age determination is based on the auricular surface morphology, moderate dental wear, and mild degenerative joint disease. The auricular surface exhibits dense bony islands across a moderately coarse surface. Dental wear is moderate but all teeth are represented with limited dental disease. Osteoarthritis is restricted to the lower back and knees. These indicators all support an age estimate of 35-40 years.

Ancestry

The individual exhibits slight shovel-shaped incisors and small squatting facets on the distal tibiae. These traits are consistent with Native American populations.

Sex

The sex determination of this individual is based on pelvic morphology. Auricular surface is raised, and the pubic bone is wide. This morphology is consistent with female individuals.

Dentition

The dentition of this individual is complete. A few small sections of the alveolar structures are missing. Dental attrition is moderate with two enamel fractures on the mandibular left first molar and the maxillary right third molar. One occlusal pit lesion is evident on the mandibular right third molar. A small periodontal pocket surrounds the root of the maxillary left central incisor. The teeth adjacent to the incisor are not affected, and the central incisor exhibits no other pathological condition.

Functional Morphology

Most major muscle attachments are evident, but these areas are not overly developed. Muscle attachments on the upper and lower arm bones as well as the ulnar morphology suggests tight flexion of the elbow joint. Small squatting facets are present on distal tibiae suggesting repetitive flexion of the ankle (or dorsiflexion of the foot).

Pathology

Several pathological conditions are evident including bone fractures and marked degenerative joint disease. These conditions may be related and possibly due to a single traumatic episode. The left ulna is fractured in the distal third of shaft. This break has healed, and a small bony callus

encompasses the fracture area. The distal articular facet of the left third metacarpal is fractured and exhibits evidence of infection. An osteomyelitic reaction extends from the fracture along the shaft. A small fistula (2 mm in diameter) is present along the fracture line, and bony changes related to the osteomyelitic infection are present on the co-lateral metacarpal (second and fourth).

Degenerative joint disease is evident in the vertebral column, pelvis and right femur. Osteoarthritic changes in the vertebrae include slight marginal vertebral osteophytosis on the lower lumbar centra with slight surface porosity. In addition, the facets in two thoracic vertebrae have slight surface erosion with eburnation. The specific vertebral elements could not be identified due to fragmentation. The left sacroiliac joint exhibits mild surface erosion and localized eburnation. Finally, mild marginal osteoarthritic lipping is present on distal right femur.

41RF1-BP24-080

From a Sort

This individual is possibly a male adolescent, aged 13.5-14.5 years (code 15), of indeterminate ancestry. This burial is disturbed and commingled with burials 41RF1-BP24-037 and 41RF1-BP24-085. The sort was performed based on both the smaller size and the lack of epiphyseal closure on many elements (see age section for listing). The remains range in color from yellow to dark brown. Water damage is present on the radii, ulnae, and femur, and plant root action is evident.

Age

Age estimation is based on epiphyseal fusion of the vertebrae, long bones, and open cranial sutures. The epiphyseal rings on the cervical, thoracic, and lumbar vertebrae are all unfused, and at least one thoracic neural arch remains unfused to the body. The distal humerus is fully fused, while the medial epicondyle is unfused. The proximal radius is partially fused, and the distal radius is unfused. The proximal ulna is fused. The proximal and distal femora are unfused. The proximal and distal tibiae are unfused. The distal fibula is partially fused. The combination of these indicators suggests an age range of 13-15 years.

Sex

This individual is coded as possibly male based on the diameter of the femur head (46 mm). While this measurement produces an ambiguous sex estimate, the immaturity of the skeletal development is considered.

Dentition

The dental remains are somewhat incomplete, and all molar teeth are missing postmortem. The dentition displays slight wear. Calculus deposits range from specks to heavy, with the heaviest deposits occurring on the mandibular incisors and premolars. The right maxillary first premolar displays enamel chipping. A slight linear enamel defect is present on the left maxillary canine.

Functional Morphology

The ulna displays a large interosseous crest. Squatting facets are present on both distal tibiae.

Pathology

This individual exhibits slight active ectocranial porosis on the parietals and occipital.

41RF1-BP24-085

From a Sort

This individual is an adult male, aged 25-29 years (code 22), of possibly Hispanic ancestry. The remains of this individual are sorted based on a slightly older age and more gracile elements than 41RF1-BP24-037. Remains of this individual, 41RF1-BP24-037, and a subadult (41RF1-BP24-085) are commingled and lie directly above the primary burial of 41RF1-BP24-068.

The cranium is mostly intact, one of only four intact skulls in this series. The elements have evidence of water damage, color of the bones ranges from yellow to brown, and root action is evident on most remains. The humerus and radius display evidence of postmortem chop marks from the original disinterment.

Age

Age estimation is based on dental wear, fusion of the medial clavicle, epiphyseal ring fusion, and the lack of any degenerative joint problems. Dental wear is slight to moderate (see dental section), the medial clavicle is fused, and the vertebral epiphyseal rings are fully fused. None of the joint surfaces are affected by degenerative joint disease.

Ancestry

The relatively complete cranial vault and partial face allow analysis using craniometrics. A preliminary evaluation using the custom discriminant function program, FORDISC 2.0, indicates that this individual is more closely associated with Hispanics.

Sex

Sex is estimated as male based upon the robusticity of the cranial and postcranial elements. The narrow width of the sciatic notch, large mastoid process, supra-orbital sharpness and ridge size, large squared mental eminence size and shapes are all indicative of a male.

Dentition

The dentition of this individual is fairly incomplete, but the elements present display slight to moderate wear and no evidence of pathology. Calculus deposits range from slight to coalesced, with the heaviest deposits on the anterior dentition. There is slight resorption of the alveolus at the mandibular right molars ranging from 1.3 to 2.3 mm. Evidence of enamel chipping is present on the maxillary right second premolar. The right first maxillary premolar exhibits a slight linear enamel hypoplasia.

Functional Morphology

This individual displays a moderately developed postcranial skeleton. The humeri have moderate development of the deltoid tuberosity, and medial and lateral epicondylar ridges. The radial tuberosity, interosseous crest, and pronator teres attachment are marked on the radius, and the interosseous crest and attachment for brachialis on the ulna are also marked. This individual also displays slight squatting facets bilaterally on the distal tibia.

41RF1-BP24-085A**From a Sort**

This individual is a young adult (code 96), possibly male, of indeterminate ancestry. This individual is identified by a set of dentition not associated with any of the other burials in this feature. The color of the remains ranges from yellow to brown and root action is evident.

Age

This individual is a young adult based on the light degree of dental wear and the completion of dental formation.

Ancestry

Ancestry for this individual is indeterminate, however, no shovelings are seen on the central incisor.

Sex

Sex for this individual is possibly male. This estimate is based on the very robust coronoid process of the mandible.

Dentition

The dentition for this individual is mostly incomplete. The overall wear is light. Calculus deposits are moderate, with no differentiation of the levels of development. The maxillary left second molar displays a large enamel chip, which has resulted in the loss of the entire hypocone.

Burial Feature 25**41RF1-BP25-088**

An incomplete skeleton represents this infant aged 1 to 2 years. The remains exhibit postmortem breakage.

Age

This individual was determined to be 1 to 2 years of age based on dental development and long bone measurements. The development of the deciduous teeth place the age at 1 to 1.25 years. The deciduous canine is root $\frac{1}{2}$ complete, the first molar is root $\frac{3}{4}$ and the second molar is cleft initial.

The femur is 134 mm in length, the tibia is 111 mm in length, and the fibula is 106 mm in length. The length of the long bones suggests a similar age of 1.5 to 2 years.

Dentition

All the deciduous dentition is present, though not in occlusion. The maxillary canines exhibit linear enamel hypoplastic defects. These defects occurred at approximately crown $\frac{1}{2}$ to $\frac{3}{4}$, which corresponds with an age of occurrence of 4 to 6 months.

Extra Elements

- 1) Deciduous maxillary central incisor, with apex complete development, indicating an age of at least 4 years.

41RF1-BP25-089

An incomplete skeleton represents this infant aged newborn to 6 months. Ancestry and sex are indeterminate. Age is estimated based on dental and long bone development. Nearly all the deciduous dentition is present, though not in occlusion. The deciduous canine is crown $\frac{1}{2}$ complete, and the second molar is crown $\frac{1}{2}$. This development suggests an age of 4 months. The radius is 56 mm, the ulna is 66 mm, and tibia is 70 mm in length. These long bone lengths support an age estimate of newborn to 6 months.

Burial Feature 26

41RF1-BP26-092

This male aged 50+ years (code 97) is represented by a very fragmentary, partially complete skeleton. The ancestry is possibly Native American. The remains of this individual are light yellow in color. Fragmentary remains represent the crania, maxilla, dentition, ribs, vertebrae, innominate, left humerus, right radius, ulnae, femora, and left fibula.

Age

The age estimation is based on the presence of arthritic lipping associated with the Schmorl's depression on one lumbar vertebra and moderate tooth wear. The thin cortical bone and porous trabecular bone in the femora indicates suggests an older individual. A fragment of the auricular surface present is at least in Phase 7 development indicating an age of 50+ years.

Ancestry

The estimate of possible Native American ancestry is based on the platymeric femora. This characteristic flattening of the proximal femur shaft is found more commonly in Native Americans.

Sex

Sex estimation is based on the overall robust nature of the elements and the highly developed muscle attachments on the femur, especially the linea aspera. Both of these factors indicate a sex estimation of male.

Dentition

The dentition of this individual is highly fragmentary. The maxillary left second molar is retained in a portion of the left maxilla. The maxillary left third molar and mandibular left third molar are present without associated alveolar structures. All of the teeth present have moderate wear. The lower right third molar exhibits small occlusal, lingual, and interproximal pit caries. Overall, the dentition appears to be in good condition.

Pathology

The only pathology present is Schmorl's depressions on two upper lumbar vertebrae. One vertebra has Schmorl's depression on both the superior and inferior endplates. The superior endplate depression measures 13 mm medio-lateral by 8 mm anterior-posterior and 3 mm deep. The inferior endplate depression measures 10 mm medio-lateral by 9 mm anterior-posterior and is shallow. The second upper vertebra

is only partially present missing the inferior portion. The depression is mostly complete, although a small portion is missing. The depression measures a minimum of 16 mm medio-lateral by 8 mm anterior-posterior. The lumbar vertebra also exhibits evidence of pulling, with erosion of the superior left endplate, scored as arthritic lipping.

41RF1-BP26-095

From a Sort

This female, aged 25-29 years (code 22), is represented by a nearly complete skeleton. The elements are highly fragmented due to postmortem damage, thus very few complete elements are present. Missing elements include most of the cranial material, right humerus, right ulna, and most of the ribs and vertebrae. Other than postmortem damage, the preservation of the skeleton is very good. This individual was initially commingled with several elements that were later matched to burials 41RF1-BP26-101 and 41RF1-BP26-106B.

Age

Age was estimated between 25 and 29 years based on the overall density the bones and lack of degenerative joint disease. The cortical bone is smooth and dense, indicating a younger individual. The trabecular bone is similarly dense and compactly organized. The only instance of osteoarthritic change involves a superior articulation facet of the 12th thoracic vertebra. No other joint surfaces exhibit remarkable degenerative changes suggesting a young adult age.

Ancestry

Ancestry is estimated as possible Native American based on platymeria of the femur.

Sex

Sex estimation is based on the overall size of the elements and elevation of the auricular surface. The elements are generally small and not too robust. The auricular surface of the innominate is elevated, and a preauricular sulcus is appreciable. All of these features indicate the sex of the individual is female.

Pathology

This individual exhibits mild to moderate healed periostitis on the appendicular elements. The right radius displays mild healed periostitis on the posterior distal third of the shaft. The leg elements exhibit slightly worse periostitis. The femur has healed mild to moderate periostitis on the posterior to medial surfaces of the midshaft. Similarly, the tibiae display

mild to moderate healed periostitis on the posterior to lateral surfaces of the midshaft, and the fibulae have healed moderate periostitis on the midshaft.

The only instance of arthritic change occurs on the superior articulation facet of T12, and it is limited to mild porosity and osteophyte development on both the surface and margins of the facet.

41RF1-BP26-100

From a Sort

This individual is a male, aged 25-29 years (code 22), of indeterminate ancestry. The well preserved remains are in good condition and range from yellow to brown in color. The elements present include sternum, left scapula, right clavicle, innominate, patella, humerus, radius, ulna, femurs, tibiae, fibulae, ribs, and vertebrae. Enthesophytes are present on both the achilles portion of the calcaneus. An extra right partial clavicle is associated with this burial.

Age

Age estimation is based on the pubic symphysis. The left pubic symphysis is consistent with a Todd Phase 4-5, which corresponds to age 25-30 years (code 22). The overall appearance of the elements, little arthritic formation on the joint surfaces and the presence of dense cortical bone support the age estimation.

Sex

The estimation of sex as male is based on the rather robust postcranial skeleton with moderate muscle development on all long bones.

Functional Morphology

This individual displays a very well-developed postcranial skeleton. The humerus is unusually short, although the muscle development is rather marked. The humerus was associated with this individual due to the good articulation with the ulna and radius and also the similarity in color and weathering. A photograph of the elements *in situ* also supports the association of this disproportionate match. The triceps origin on the left humerus shows a large degree of muscle development. The left scapula is also correspondingly robust. The pectoralis major, deltoid, and latissimus dorsi attachments are moderately developed on the humerus. The ulna displays marked attachments for pronator quadratus, and the radius is moderately developed at the attachment for the oblique line.

The gluteal and adductor muscle group attachments on the femora are marked. The femora display broad linea aspera measuring 9 mm wide and 3 mm deep. The tibiae exhibit developed attachments for the soleus muscle. The insertion of the soleus muscle on both calcanei has moderate enthesophytic development.

Pathology

Moderate enthesophytic development is present on the Achilles portion of the left and right calcanei with the right more pronounced than the left. In addition, slight osteophytic formation is present on the joint surfaces of the left scapula, left proximal humerus, and the proximal and distal radius.

41RF1-BP26-100A

From a Sort

This female, aged 25-34 years (code 23), of indeterminate ancestry is represented by only a calvarium and fragmentary dentition. The remains were located at the feet on Burial 41RF1-BP26-100, however, the differences in muscle development and overall robusticity suggest that these are two different individuals.

Age

The overall appearance of the bone, which lacks suture closure and porosity, suggests this individual is a young adult aged 25-34 years (code 23). In addition, the associated dentition shows only slight wear.

Sex

Sex estimation is based on cranial morphology. The relatively small nuchal crest, gracile mastoid process, and supra-orbital margin sharpness all indicate sex to be female.

Dentition

Three teeth are associated with this burial: a right and left first maxillary molar and a left mandibular lateral incisor. The lower lateral incisor is double barrel shaped. The teeth are healthy and exhibit only slight attrition.

41RF1-BP26-101

This adult female, aged 40-50 years (code 26), is represented by a partial skeleton. The ancestry is indeterminate. The cranial fragments include parietal, occipital, temporal, maxilla and mandible. Postcranial elements include manubrium, right clavicle, left innominate, left calcaneus, right humerus, right radius, ulnae, femurs, tibiae, and fibula. Also fragmentary ribs and vertebrae are present.

The skeleton is well preserved, but fragmentary. The right femur has a postmortem break on the mid shaft. Small postmortem cut marks are present on the distal one-third of the tibia. The elements range in color from yellow to brown.

Age

The age estimate is based on the moderate to severe osteoarthritis on the cervical, thoracic, and lumbar vertebrae. The dentition shows advanced stages of wear. These factors indicate an age of 40-50 years (code 26).

Sex

Sex estimation is based on the gracile nature of the dentition and bones, especially the tibia and fibula. From the fragmentary cranial remains, it is possible to assess the mastoid process and nuchal crest, both of which are consistent with a sex estimation of female.

Dentition

The dentition of this individual is fragmentary. The posterior mandibular dentition was lost antemortem, and the alveolar bone exhibits resorption. The fragmentary right maxilla is present with the central incisor and the resorbed socket of the lateral incisor. The lower right first premolar, and the left first and both second upper premolars, along with the upper first molar are present without sockets. The mandibular left canine socket is double rooted. Moderate wear is present on all of the dentition.

Functional Morphology

This individual is gracile with little postcranial muscle development. The right humerus has little muscle development. There is a supra capitulum fossa on the proximal right humerus, indicating habitual tight flexion of the elbow. The linea aspera of the femur is also small and shallow, with little development.

Pathology

Moderate to severe arthritis is present on all of the vertebrae. Arthritic lipping can be observed on the body and articular facets of the cervical vertebra, and on the bodies of the thoracic and lumbar vertebra.

The left ulna exhibits pinpoint porosity around the radial notch and along the medial surface of the proximal one-third of the shaft. The proximal end also displays a slight well-healed enthesophyte.

The left proximal femur has a healed fracture. The fragmented state of the element makes reconstruction of the joint impossible. However, it is possible to observe severe remodeling and callus formation around the proximal joint surface and proximal $\frac{1}{3}$ of shaft.

The left tibia has moderate periostitis affecting the entire shaft.

41RF1-BP26-103

An incomplete skeleton represents this infant, aged 1.5 to 2.5 years, of indeterminate sex and ancestry. The fragmentary elements present include the occipital, both maxillae, most deciduous teeth and two permanent teeth, several ribs and vertebrae, both scapulae, both clavicles, left innominate, both radii, complete left femur, and fragmentary right femur.

Age

This child was determined to be between the ages of 1.5 and 2.5 years based on dental development and long bone measurements. The deciduous canine is root initial, the deciduous second molar is cleft initial, and the permanent maxillary first incisor is crown $\frac{1}{2}$ indicating an age range between 1.0 and 2.5 years. Similarly, the left femur measures 136 mm, indicating an age of 1.5 to 2.5 years.

Dentition

All the deciduous maxillary dentition, the deciduous mandibular first incisor, both second molars, and the permanent left maxillary first incisor and right maxillary second molar are present. The teeth are not in occlusion and show little to no wear and no caries.

41RF1-BP26-104

This subadult, aged 9.5-12.5 years (code 12) of unknown sex and ancestry, is represented by a very fragmentary skeleton. The preservation of the elements is good, and the color is yellow to brown. The elements present include a frontal, right femur epiphysis, tibiae, and a left fibula. An old postmortem shovel cut mark is present on the midshaft of both tibiae.

Age

The age estimation of this individual is based on the estimated, reconstructed maximum length of the left tibia (~285 mm), which corresponds to an age of 10.5-11.5 years.

Pathology

Mild cribra orbitalia was scored.

41RF1-BP26-111

Present is the nearly complete skeleton of a female, aged 60+ years (code 29) of probable Native American ancestry. The skeletal elements exhibit good preservation but are highly fragmented due to postmortem damage. This individual displays generalized osteoporosis and a badly fractured right femur.

Age

This individual was estimated to be 60+ years based on the condition of the skeletal elements, most notably the presence of advanced osteoporosis and degenerative joint disease. Nearly all of the elements exhibit osteoporosis where both the cortical and trabecular bone have thinned out considerably making the elements extremely light and fragile. The presence of osteoarthritis on the majority of the elements also suggests the individual is an older adult. All but two of the mandibular teeth were lost antemortem, and the alveolar bone has been resorbed, again suggesting the individual is an older adult.

Ancestry

The ancestry was estimated based on the pronounced muscle attachments of the cranium and the postcranial elements considering sex as female. The nuchal region of the occipital and the mastoid processes are rather robust for a female, as are the muscle attachments of the long bones, suggesting this individual was muscular for a female. Pronounced musculature is common among the Native American females of this series, thus the musculature of this individual is consistent with other Native American females in the series.

Sex

Sex was estimated as female based on the overall size of the elements and morphology of the skull. The long bones are comparatively small suggesting the individual is female. The diameter of the humeral head measures 43 mm and the femoral head measures 45 mm in diameter, also suggesting the individual is female. Similarly, the sharpness of the supra-orbital margin, and mental eminence size and shape indicate the individual is female.

Dentition

No teeth are present for this individual. All but two of the mandibular teeth were lost before death, and the alveolar

bone has been resorbed. The right second incisor and right canine are missing due to postmortem loss, and the sockets show no signs of abscess. The highly fragmentary nature of the maxilla prohibits assessment of dental pathology.

Functional Morphology

This individual exhibits well defined muscle attachments on the appendicular elements. The clavicles have articular facets on the lateral inferior aspect from articulation with the superior margin of the scapulae. Unfortunately, both scapulae are missing the superior margin due to postmortem loss. The right clavicle exhibits a larger and better-defined facet, measuring 16 mm anterior-posterior by 18 mm medial-lateral with an elevation of approximately 1 mm. The humeri display well-developed deltoid tuberosities, especially the right humerus, suggesting habitual abduction or lifting of the arms at the shoulder. The lower arm elements exhibit pronounced muscle attachments corresponding with pronation and supination of the arm. The radii have well defined pronator teres attachments and both the radii and ulnae display marked pronator quadratus attachments, suggesting habitual pronation of the lower arm.

The leg elements also show pronounced muscle attachments. The pathological nature of the right femur and corresponding alterations to the right tibia and fibula preclude analysis of functional morphology for those elements. However, the left leg elements, especially the femur, display pronounced muscle attachments. The linea aspera and proximal muscle attachments (the gluteal tuberosity, pectineal line, and trochanters) of the left femur are well defined and rugged, indicating habitual and extensive use of the gluteal and hip muscles. These muscles primarily act in lateral and medial rotation of the hip joint, especially in the function of walking. As mentioned, and discussed in the next section, the right leg is pathological; the femur has had two complete fractures that have healed or are healing. The majority of the functional morphology is likely a result of the fractures. With the right leg fractured as badly as it was, a crutch would definitely have been necessary. The extended use of a crutch could result in both the articulation facet seen on the right clavicle and account for the alterations to the elements of both the right and left shoulders and arms. Similarly, the developed muscle attachments of the left leg and hip are likely a result of that side compensating for the pathological right side.

Pathology

The skeletal elements exhibit a suite of pathological alterations. The majority of the alterations are a direct result

of age related degeneration, notably osteoporosis and arthritis. This individual displays generalized osteoporosis, as indicated by extreme thinning of the trabecular and cortical bone resulting in light and fragile bones. The extent of the osteoporosis can be appreciated in the near total degeneration of trabecular bone in the diaphyses and epiphyses of the long bones.

Nearly all the skeletal elements exhibit osteo-arthritic alterations on the joint surfaces. The left temporomandibular joint (TMJ) displays mild osteophyte development, porosity and erosion, and the right TMJ has mild porosity. The cervical vertebrae have mild lipping and porosity on the articular facets and centra. The thoracic and lumbar vertebrae display mild osteophytic lipping and porosity on the articular facets. The acetabulum and glenoid fossa fragments exhibit mild lipping and porosity on the margins. The proximal and distal articular surfaces of most of the long bones also exhibit mild lipping and/or mild porosity. The left trapezium and first metacarpal exhibit severe osteophytic remodeling and the joint surfaces display eburnation.

The skeletal elements also display evidence of generalized infection. The parietals and occipital exhibit mild healed ectocranial porosis. Similarly, the zygomatics display porosity at and around the area of the zygomatico-facial foramen and sutures. Lytic lesions have affected the temporals and sphenoid. The endocranial surface of both the right and left temporals and sphenoids, have areas where the cortical bone has been destroyed to expose the cancellous bone. This is especially true of the petrous portion regions of the temporals. The ectocranial surface of the left temporal and sphenoid has also been affected by lytic activity. There is a lesion, measuring 7 mm by 5 mm and approximately 3 mm deep, on the anterior margin of the temporal-mandibular fossa. Lytic lesions similarly have affected the region of the sphenoid just anterior to the temporal. The lesion remodeling begins in the area of foramen ovale and extends lateral and anterior up the greater wing. The bone affected by the lesions is extremely porous, with most of the cortical bone destroyed to expose the trabecular bone. The left mandibular ascending ramus exhibits porosity in the gonial region and the area of the sigmoid notch. This porosity is likely related to the pathology of the left temporal region.

The left femur displays localized mild healed periostitis on the midshaft, while the right femur has moderate active periostitis on the midshaft. Similarly, the left tibia has mild

healed periostitis at the midshaft, and the right tibia exhibits moderate active periostitis on the shaft. The fibulae also have mild healed periostitis on the midshafts.

The right femur exhibits two distinct fractures. The proximal femur has a healed fracture to the neck region. This fracture is likely a result of weakening of the bone due to osteoporosis. The fracture resulted from a collapsing of the femur neck. This collapsing of the neck lead to compression and deformation of the greater and lesser trochanters and displaced the entire proximal end of the femur posteriorly at an angle of approximately 15 degrees off vertical. The bone healed in this compressed and deformed state. The deformation of the lesser trochanter has extended and pulled the lesser trochanter lateral and anterior, creating a fossa (approximately 8 mm deep) between the proximal shaft and lesser trochanter. The fracture did not lead to any appreciable deformation of the femoral head, and the acetabulum is too fragmentary to reveal any evidence of deformation.

The distal third of the femur also has a fracture. The fracture itself cannot be appreciated due to resulting osteomyelitis and postmortem damage to the distal third of the shaft. The shaft in the area of the infection is considerably swollen, and the bone is extremely porous and remodeled. The infection can also be appreciated on the rest of the shaft as periostitis and porosity. A cloaca, 4 mm in diameter, is present on a fragment located on the posterior surface of the shaft, indicating that the infection was active and draining at the time of death. The bone in the area of the fracture and infection was obviously unstable and likely immobilized the leg.

The fractures to the right femur appear to have affected the other leg elements. The right tibia and fibula are generally smaller than the left elements, suggesting that the muscles and bones had atrophied likely from non-use.

41RF1-BP26-113

From a Sort

This female, aged 20-24 years (code 21) of possible Native American ancestry, was identified from a sort in the commingled Burial Feature 26. The burials, 41RF1-BP26-113, 41RF1-BP26-114, 41RF1-BP26-128, and 41RF1-BP26-131, were found on top of extended Burial 41RF1-BP26-119. These remains are sorted and identified as an individual due to the extremely gracile skeletal elements, the color, and state of preservation. The elements are yellow to brown in color with good preservation. The skeleton is highly fragmented resulting from postmortem disturbances. There are postmortem cut marks on the distal right tibia. A nearly

complete, highly fragmented cranium, clavicles, innominate, humeri, radii, ulnae, femurs, tibiae, a left fibula, fragmentary ribs, and vertebrae represent the individual. Green staining is present on one proximal phalanx, with staining on all surfaces.

Age

Age estimation is based on the fragmentary auricular surface that exhibits characteristics such as billowing and fine granularity associated with Phase 1 development. The overall youthful appearance of the skeleton, with no vertebral arthritic development and very slight tooth wear, support the age estimation of a young adult of 20-24 years.

Ancestry

The estimated ancestry as possible Native American is based on the slightly platymeric femora and the slight development of squatting facets present on the tibia. The incisors exhibit slight shoveling. The zygomatics appear to be moderately flared. All of these indicators suggest a possible Native American ancestry. However, the extremely gracile nature of the skeleton and the dentition, along with the mildness of Native American traits, differentiates this individual from the other Native Americans in this series. This may indicate possible Hispanic ancestry as well.

Sex

Estimation of sex as female is based on the extremely gracile skeleton. The diameter of the femoral head measures 39 mm, which falls well within the female range. In addition, the mastoid processes, supra-orbital sharpness, and supra-orbital ridge size all indicate a sex estimation of female.

Dentition

The overall health of the dentition appears to be moderate. The teeth exhibit only slight wear. A small occlusal carious lesion is present on the maxillary right third molar. Evidence of resorption of the alveolar bone is present in calculus formation on the root surfaces below the cementum-enamel junction. Resorption and calculus buildup is especially prominent in the mandibular molars. Numerous enamel hypoplasia defects are present on the anterior dentition.

Functional Morphology

This individual is gracile with little postcranial muscle development. The humeri have little muscle development. A supracapitulum fossa on the proximal right humerus indicates habitual tight flexion of the elbow. The gluteal line is slightly developed. The linea aspera of the femur is also small and shallow with little development. The femora exhibit slight platymeria.

41RF1-BP26-114

From a Sort

This child of unknown sex aged 6.5-7.5 years (code 08) of indeterminate ancestry was identified from a sort in commingled Burial Feature 26. The burials 41RF1-BP26-113, 41RF1-BP26-114, 41RF1-BP26-128, and 41RF1-BP26-131 were found on top of extended Burial 41RF1-BP26-119. This individual was sorted and identified in the feature because it is the only subadult present in the commingled burials. The highly fragmented remains are light brown in color with good preservation. Postmortem cutmarks are present on the femoral shaft. The individual is represented by fragmentary ribs, right clavicle, right humerus, and left femur.

Age

Age estimation is based on the approximate maximum lengths of the humerus and femur. Both of these elements were broken postmortem, and maximum length is based on a partial reconstruction of the elements. The humerus measures approximately 195 mm in length (age 6.5-7.5), and the femur measures approximately 245 mm in length (age 5.5-6.5). As the humerus was more complete, age estimation was based on this measurement.

41RF1-BP26-119

This adult male, aged 25-30 years (code 22) of possible Hispanic ancestry, is identified as a primary articulated burial in Feature 26. The commingled remains of at least four other individuals 41RF1-BP26-113, 41RF1-BP26-114, 41RF1-BP26-128, and 41RF1-BP26-119A (as well as numerous commingled ossuary elements) were interred on top of the primary burial. This individual died as a result of perimortem trauma. Fractures are present on the cranial vault, face, and dentition. The fairly complete remains are in good condition, and the color of the bone ranges from yellow to brown. Plant root damage is evident on the cortical surfaces of the bones.

Age

Age estimation is based on pubic symphysis and auricular morphology. The right pubic symphysis is consistent with a Todd Phase 4 and a Suchey-Brooks Phase 3. The auricular surface is consistent Lovejoy's Phase 2-3. These features correspond to a range of 25-35 years.

Ancestry

Traits used for ancestry estimation are ambiguous. The femora are moderately platymeric, and the tibiae have very slight squatting facets. These traits suggest Native ancestry. However, the maxillary central and lateral incisors lack shoveling, and moderate to heavy calculus development is

present, which may reflect a more of a traditional sedentary soft food diet. These traits suggest non-Native ancestry.

Sex

Sex estimation is based on cranial morphology. The nuchal crest is moderately developed, and the supraorbital region displays a rounded margin and a heavy browridge. The mandible displays a well defined mental eminence.

Dentition

The dentition for this individual displays slight to moderate wear, with the heaviest wear occurring on the mandibular central incisors and the maxillary molars. Calculus formation is moderate to coalesced with the heaviest deposits on mandibular incisors and canines. The calculus deposits on many of the teeth is present below the CEJ due to periodontal resorption. Marked alveolar resorption occurs on the mandibular and maxillary molars. A periodontal abscess with pocket formation is present on the maxillary left first molar. Linear enamel hypoplasias occur on the maxillary and mandibular incisors, canines and premolars.

Antemortem and perimortem damage is evident in the dentition. Antemortem enamel chipping occurs on the maxillary right first and second premolars and central incisor, maxillary left first premolar and first molar, mandibular right first premolar, mandibular left lateral incisor and second premolar. These areas of enamel chipping exhibit staining and deposits indicating the antemortem occurrence.

Perimortem trauma is evident in the avulsion fractures on the maxillary right lateral incisor and canine as well as the mandibular right first premolar. The root of the maxillary incisor is fractured at the CEJ. The canine exhibits fractures on the root and crown 2.3 mm above the CEJ resulting in the loss of the occlusal and lingual surfaces of the crown. The lingual cusp of the mandibular premolar is missing due to fracturing.

Functional Morphology

The postcranial skeleton is only slightly developed suggesting a lack of rigorous activity. The right humerus displays slight development of the lateral epicondylar ridge. The right radius and ulna display marked interosseous crests. The distal tibiae display slight squatting facets.

Pathology

Evidence of a traumatic death is present on the cranial vault, face, and dentition. The fragmentary right parietal displays a radiating fracture extending at least 50 mm between the

mid lambdoidal suture and anteriorly toward the coronal suture. The maximum diameter is unknown due to the fragmentary condition of the bone. The fracture involves both the endo and ectocranial surfaces and shows no evidence of healing. The right temporal displays a fracture located superior and posterior to the external auditory meatus. Radiating fractures extend from the meatus anteriorly toward the zygomatic process and posterior/inferiorly from the meatus superior to the mastoid process.

The face shows evidence of blunt trauma to the right lateral side. The right malar is fractured along the inferior orbital margin. The right maxilla displays three fractures. The first extends superior to inferior along the nasal border and resulted in the separation of the right nasal aperture margin. The second maxillary fracture severs the frontal process from the body of the maxilla and runs anterior-posterior from the nasal border to the root of the lacrimal groove. It is uncertain whether this fracture involves more of the facial region due to the fragmented remains. The third fracture is a LeFort type 2 fracture, although it does not occur bilaterally. It runs in an inferior-posterior arc from 9 mm lateral to the nasal aperture to 20 mm lateral to the nasal aperture. Evidence of fresh bone peeling is present within the maxillary sinus, which supports the perimortem occurrence of this fracture. The maxillary dentition also displays perimortem crown fractures of the right canine and lateral incisor (see Dentition section for description).

From the available evidence, a minimum of two distinct blows to the cranium is recognized. One blow strikes this individual in the supra-mastoid region of the right temporal, thus producing the radiating fractures on the parietal as well as the fractures around the external auditory meatus. The second blow most likely was directed towards the right portion of the face, thus fracturing the crowns of two maxillary right teeth, as well as the nasal aperture, inferior orbital border, anterior maxillary atrial wall, and the frontal process of the maxilla.

The unusual unilateral nature of the cranial fractures indicates caution is necessary when evaluating this trauma. The force required to cause a LeFort fracture is typically severe enough to result in bilateral facial fractures. Because of this discrepancy, the fracture margins were closely examined in order to confirm the perimortem determination of the trauma. The margins exhibit dark staining similar to the staining present on the other elements supporting the old nature of the fractures. Close examination of a photograph of the burial *in situ* shows that the skull was

not disturbed historically. This lessens the possibility of postmortem disturbance causing the damage to the right side of the cranium.

This individual displays slight cribra orbitalia in the right and left eye orbits, the associated lesions appear to be in the process of healing. There is slight active ectocranial porosis localized on the posterior right and left parietal around the lambdoidal suture.

Slight marginal osteophytic formation is present on the centrum of one thoracic (1-9) vertebra, and slight marginal porosity is present on the centra of the first, second, and third lumbar vertebrae.

This individual displays a bilateral congenital dislocation of the hips. Both femoral heads have become flattened and oval shaped with the horizontal diameter of the head (left = 53 mm, right = 58 mm) greatly exceeding that of the vertical diameter (left = 42 mm, right = 46 mm). Both femoral necks are shortened, and the angle of the neck is close to 90 degrees. Malformation of this kind may be the result of repeated dislocation of the femoral head from the acetabulum during early childhood into adolescence. Degenerative changes associated with the dislocation include only slight marginal porosity on both femoral heads and moderate marginal osteophytic formation on the right femoral head. Although fragmentary, the acetabulae also show modification of the lunate surface to accommodate the malformed femoral heads. Due to the fragmentary nature of the bone, the full extent of the modification cannot be assessed. No other aspect of these bones suggests any disability resulting from the developmental modifications.

The achilles surfaces of the right and left calcanei display slight enthesophyte formation.

41RF1-BP26-119A

From a Sort

This burial represents a young adult male (20-30 years [code 96]) of indeterminate ancestry. This individual was sorted from the commingled remain surrounding 41RF1-BP26-119. Four additional burials were identified in this cluster of elements including 41RF1-BP26-113, 41RF1-BP26-114, 41RF1-BP26-128, and 41RF1-BP26-131. The burial consists only of postcranial appendicular elements, primarily lower limb bones. The bones are in good but fragmentary condition. A series of postmortem cuts and hack marks are present on the right femur. The marks are consistent with

the bones from this individual being disturbed and re-interred after 41RF1-BP26-119 was placed in the burial pit.

Age

All epiphyses are complete fused but the fusion line is evident on the proximal tibia and proximal ulna. The joint surfaces are in good condition and no degenerative changes are evident. The pattern of fusion and lack of osteoarthritic changes are consistent with an individual between 20 and 30 years old.

Ancestry

The proximal femur exhibits only slight platymeria, and bilateral squatting facets are present on the tibiae. These traits are consistent with Native American populations; however, estimation of Native American ancestry is tentative.

Sex

The sex of this individual is based on the gross morphological characteristic of the bones. The femur is moderately robust and the femoral head is at least 49 mm in diameter, which falls within the male ranges for most Native American and European populations.

41RF1-BP26-120

From a Sort

This individual is an adult male, over 50 years old at death, of Native American ancestry. The individual consists of disturbed disarticulated elements recovered from a discrete bone cluster above Burial 41RF1-BP26-126. Disarticulated bones from burials 41RF1-BP26-122, 41RF1-BP26-123, and 41RF1-BP26-130 were collected with this individual from the feature. Individuals are defined based on skeletal size, coloration and preservation. Several elements are not specifically identified by individual. These bones are assigned ossuary element codes and provenienced to the burial feature. Several os coxae and fibulae are coded in this fashion.

Burial 41RF1-BP26-120 is in fair condition, but most elements are fragmentary. The individual is represented by cranium, a series of upper limb elements, four vertebral centra, the right innominate, and sacrum fragments. The bone is brown to light brown in color with slight water damage on some elements.

Age

The age determination is based on a variety of secondary indicators. The primary age indicators of the pelvis (i.e. auricular surface and pubic symphysis) are absent. The

vertebral elements exhibit severe osteophytosis with large osteophytes on the lateral margins of thoracic and lumbar centra. Osteoarthritic lipping is evident in the shoulder and elbow joints. Oral health is extremely poor with numerous periapical abscesses and antemortem loss of several teeth. The combination of these degenerative traits suggests an individual of advanced age of 50+ years.

Ancestry

The overall skeletal size is robust, which is consistent with the Karankawa male pattern. The face exhibits a wide nasal aperture with no prognathism and a moderately wide interorbital distance (24 mm). The maxillary palate is parabolic with straight palatine sutures. These traits are typical of Native American populations. However, the zygomatics exhibit slight recurvature, which is typically a European trait.

Sex

The morphology of the cranium is indicative of a male individual. The supraorbital torus and suprameatal crest are marked and elevated. The zygomatic bones are robust. The postcranial elements are quite large indicating a male individual.

Dentition

The alveolar portion of the maxilla is nearly complete, but only the roots of left second premolar are present. Six teeth have been lost postmortem. Eight teeth have been lost antemortem with the alveolar structures resorbed. Two tooth sockets exhibit active periapical abscesses. The mandible and all lower dental remains are missing. Overall, this individual's oral health is extremely poor.

Functional Morphology

The cranial morphology is moderately robust. The muscle attachments on the left clavicle and right ulna are well marked. The deltoid origin on the lateral clavicle is slightly raised and well delimited.

Pathology

Skeletal pathological lesions evident in this individual are limited to degenerative osteoarthritic changes. Severe vertebral osteophytosis is evident in two thoracic centra, a mid and lower element. The vertebral bodies show heavy osteophytic build-up on the lateral margins of the centra. The end plates of each vertebra are intact and unaffected. Moderate marginal osteoarthritic lipping and mild surface porosity is present on the glenoid fossa of the left scapula. Mild marginal osteophytes surround the articular surface of the proximal ulna.

41RF1-BP26-122

From a Sort

This individual is an adult female, aged 20-29 years (code 21), of Native American ancestry. The burial consists of disturbed disarticulated elements recovered from a discrete bone cluster above Burial 41RF1-BP26-126. Disarticulated bones from burials 41RF1-BP26-123, 41RF1-BP26-120, and 41RF1-BP26-130 were collected with this individual from the feature. Individuals are defined based on skeletal size, coloration and preservation. Several elements are not specifically identified by individual. These bones are assigned ossuary element codes and provenienced to the burial feature. Several os coxae and fibulae are coded in this fashion. Burial 41RF1-BP26-122 is in fair condition, but most elements are fragmentary. Femora, tibiae, and a fibula represent the individual. The elements are light brown to yellow in color.

Age

The age of this individual was determined based on the presence of the epiphyseal line on both femora. This feature along with the lack of any arthritic changes in the joint surfaces of the long bones indicates that the individual is a young adult.

Ancestry

The ancestry estimation is based on the moderately platymeric femurs and the presence of squatting facets. These features suggest Native American ancestry.

Sex

Estimation of sex is based on the overall gracile appearance of the long bones. Gracile individuals are especially likely to be female in this series, given the robustness observed in the males.

Functional Morphology

This individual has only slight muscle development. The gluteal region has little muscular development and the linea aspera is relatively narrow and shallow. The femora exhibit moderate platymeria. The tibiae display squatting facets.

41RF1-BP26-123

From a Sort

This individual is an adult female, aged 20-29 years (code 21), of possible Native American ancestry. The individual consists of disturbed disarticulated elements recovered from a discrete bone cluster above Burial 41RF1-BP26-126. Disarticulated bones from burials 41RF1-BP26-122, 41RF1-BP26-120, and 41RF1-BP26-130 were collected with this

individual from the feature. Burial 41RF1-BP26-123 is in fair condition, but most elements are fragmentary. A clavicle, scapula, legs and calcaneus represent the individual. The elements are light brown to yellow in color.

Age

The age of this individual was determined based on the presence of the line of fusion of the epiphysis on both the left and right femur. This feature along with the lack of any arthritic changes in the joint surfaces of the long bones indicates that the individual is a young adult.

Ancestry

The ancestry of this individual is based on the moderately platymeric femurs. This feature is indicative of possible Native American ancestry.

Sex

The determination of sex for this individual is based on the overall gracile appearance of the long bones. The femoral head measures 40 mm in diameter.

Functional Morphology

This individual has moderate muscle development. The right clavicle has slight development at the deltoid origin. The femur has little development in the gluteal region with the narrow, flat linea aspera. The femur is moderately platymeric. The soleus line of the tibia exhibits moderate development.

41RF1-BP26-125

This male, aged 30 to 35 years (code 23) of probable Hispanic ancestry is represented by a nearly complete skeleton. The remains are fragmentary, exhibiting varying degrees of postmortem breakage. While the cranial and axial skeletal remains are highly fragmented due to postmortem damage, the appendicular elements do not exhibit a lesser degree of fragmentation. This individual was initially semi-commingled with burials 41RF1-BP26-126, 41RF1-BP26-130, and 41RF1-BP26-130A. The majority of elements for this individual were clearly associated, however, some of the elements were sorted from the other individuals and matched to this individual based on size, morphology and color of the elements.

Age

Estimation of age is based on the morphology of the auricular surface and pubic symphysis. The auricular surfaces were scored as group 3+, which correlates to an age range of 30-35 years. The pubic symphyses aged similarly, scoring as Todd Phase 6 (age 30-35) and Suchey-Brooks Phase 4 (35 ±

10.5 years). This age estimate is supported by the overall condition and density of the cortical and trabecular bone.

Ancestry

The ancestry estimation of probable Hispanic is based on the morphology of the cranio-facial elements. Although the skull was highly fragmented, reconstruction of the cranial elements allowed for ancestry estimation. This individual exhibits a mixture of Caucasian and Native American craniofacial traits; an indicator of admixture between the two groups has implied a Hispanic ancestry. The skull is small overall, and the face is narrow with little to no prognathism, which are features representative of European ancestry. Similarly, the nasals are “pinched,” a European trait. The palate has an overall U-shape, a Native American trait. A nasal sill is present, though it is slightly blurred, again a Native American trait. This mixture of ancestral traits suggests this individual is of Hispanic descent.

Sex

Sex estimation is based on the morphology of the innominate and skull. The auricular surface of the innominate has little to no elevation, and the pubic body is narrow, both male traits. Similarly, the supra-orbital bluntness and ridge size suggest the individual to be male. The shape and size of the mental eminence also support the sex estimation of male.

Dentition

The dentition is mostly complete. Missing teeth include the left mandibular canine, second premolar and first molar and the right mandibular first incisor. The mandible has postmortem damage, and the left alveolar region is missing. The occlusal surface of the right maxillary third molar exhibits a slight pit caries, and two larger interproximal lesions are present on the left maxillary second molar and right mandibular canine. Abscesses have resulted in the antemortem loss of several teeth including the first and second right maxillary molars and the left mandibular third molar. The left maxillary first molar was also lost due to abscessing, and the degree of resorption is so great that the second molar has been displaced mesially. The alveolar and maxillary bone superior to the M1 region has collapsed with noticeable deformation. The second left mandibular molar has also abscessed with alteration of the alveolar bone, but the tooth has been lost postmortem.

Other teeth exhibit infections yet have not been lost. The right mandibular second incisor has a periapical abscess with fistula resulting from a carious lesion. The right mandibular second premolar and first molar have similarly

abscessed. Calculus deposits range from moderate to heavy on all of the non-abscessing teeth. Dental attrition is slight.

Pathology

Pathological changes include endocranial porosity of the left temporal, degenerative joint changes in the vertebrae and right appendicular elements, and healed fractures of the right zygomatic and left thumb.

The left temporal exhibits endocranial porosity or possibly lytic lesion activity in the area of the mandibular fossa and just anterior to the mandibular fossa. Endocranially, the bone has a dimpled porous appearance in this area where bone has been lost. This bone loss has led to postmortem breakage of the exterior surface of the bone.

The cervical vertebrae have mild porosity on the facet margins. The thoracic vertebrae have mild porosity on the surfaces of both the facets and centra. Mild porosity and osteophyte development is located on the centra of the lumbar vertebrae.

Mild marginal osteophytic lipping is present on the right distal humerus, distal radius, proximal ulna, and right patella. The right distal femur and proximal tibia exhibit moderate osteophyte development.

The right zygomatic exhibits a healed fracture. The fracture is located just inferior to the frontal process in the region of the zygomaticofacial foramen. A portion of bone between the frontal process and the temporal process was displaced posteriorly by the fracture and healed in that position. This has enlarged the zygomaticofacial foramen and resulted in a depressed appearance to the anterior surface of the zygomatic. The bone in the area of the fracture is thinner than the surrounding bone.

The proximal phalanx of the left thumb has a healed fracture. The well-healed complete fracture appears to have broken the shaft of the phalanx diagonally in a distal to proximal direction. The bone did not heal without deformation. The distal end of the phalanx is bowed laterally, and a rather large enthesophyte has formed on the distal-medial margin of the bone.

The right and left first metacarpals have rather large enthesophytes on the lateral border of the distal articular surface, and the distal articular surfaces are flattened. The enthesophytes are likely a result of hypertrophy of the

opponens pollicis muscle of the hand, a muscle that works to oppose the thumb to the other fingers.

41RF1-BP26-126

This individual is a male aged 45-60 years (code 27) represented by a primary extended burial. Based on a variety of morphological characteristics, the individual is classified as Native American. The skeleton is well preserved but fragmentary. Several burials are commingled above this burial including 41RF1-BP26-130, 41RF1-BP26-130A, 41RF1-BP26-120, 41RF1-BP26-122, and 41RF1-BP26-123. The bone is light to medium orange brown in color. Plant roots have etched the surfaces of several elements.

Age

The age of this individual is based on a suite of indicators include the auricular surface, pubic symphysis, degenerative skeletal changes, dental wear, and the presence of ossified costal cartilage. The auricular surface exhibits uniform coarse granularity with slight striae. The pubic symphyses have well delimited margins except the superior ventral margin, which has failed to form. The face is coarse with slight marginal lipping. Degenerative changes are present at all major joint and in the vertebral column. The costal cartilage of numerous ribs has ossified, which is indicative of an older adult. Dental wear is moderate with limited dental disease. The combination of these indicators is consistent with an individual between 45 and 60 years.

Ancestry

The femora are platymeric. The overall skeletal size is very robust, which is consistent with the Karankawa male pattern. The central maxillary incisors are shoveled and the individual has an edge-to-edge wear pattern. These traits are typical of Native American populations. However, the zygomatics exhibit slight recurvature, which is typically a Caucasoid trait.

Sex

The overall skeletal size of this individual is robust. The pubis is triangular with an acute subpubic angle. The auricular surface is flat and lacks a pre-auricular sulcus. The supraorbital margin is blunt, and the superorbital torus arch is large. The suprameatal crests are well-developed. These characteristics are consistent with a male individual.

Dentition

Maxillary and mandibular teeth are well represented but the maxillary alveolar structures are fragmentary and only partially represented. The status of five teeth could not be

determined. Dental wear is moderate across all teeth. Calculus deposits range from small flecks to heavy on the posterior teeth. The maxillary right second molar has a carious lesion that affects the buccal and interproximal surfaces resulting in pulp exposure. The maxillary left second molar has abscessed and was lost antemortem. The crown of the lower left third molar has been completely destroyed by a carious lesion, and the roots have abscessed.

Functional Morphology

The overall morphology of this individual is robust. Muscle attachment locations on the humeri are well marked. The insertions for the deltoideus, pectoralis major, and latissimus dorsi are evident on the proximal shaft. The shaft margins of the phalanges exhibit moderate ridges associated with the attachments of the digital sheaths. The sheaths encircle the flexor digitorum tendons, which act to flex the fingers. The origins of these muscle groups are well marked on the shafts of the radii and ulnae. This pattern is consistent with very heavy use of the arms and hands. The insertions for the gluteus maximus and upper adductor muscles are well-developed.

Pathology

Mild degenerative joint disease (DJD) is present in the vertebral column and in the major appendicular joints. The ankylosis of third and fourth cervical vertebrae is evident, and mild marginal centrum lipping and porosity is present in the other cervical elements. Moderate to slight marginal centrum lipping is present in the thoracic series. Moderate lipping and slight marginal porosity is present in the lower lumbar vertebrae. Five thoracic and three lumbar centra exhibit slight to moderate Schmorl's nodes. The dimensions

of these defects vary in size with the lower thoracic and lumbar vertebrae showing the largest lesions (Table IIA-13).

Mild marginal osteoarthritic lipping is present on the proximal and distal left humerus, distal right humerus, proximal ulnae, and distal radii. Mild surface osteophytes are present on the distal left humerus. The right acetabulum has mild marginal lipping with slight surface porosity. The proximal right femur head has moderate surface osteophytes and marginal lipping. The distal femora and right distal tibia have mild marginal lipping.

The distal left radius has a healed incomplete fracture across the lunate articular surface. The fracture line is ridged and extends diagonally across the surface. The articulation is only slightly altered. The lunate and distal ulna exhibit no osteoarthritic lipping. A superior articular facet of a lower lumbar vertebra is fractured and has failed re-attach to the neural arch. The pseudoarthrosis extends across the middle of facet. The exact vertebra involved could not be determined due to the fragmentary nature of the lumbar series.

Mild enthesophytes are present along the iliac crest of the left innominate. The majority of the right ilium is missing and the iliac crest is not present.

41RF1-BP26-128

From a Sort

This female, aged 20-29 years (code 21) of possible Native American ancestry, was identified from a sort in commingled Burial Feature 26. The burials, 41RF1-BP26-113, 41RF1-BP26-114, 41RF1-BP26-128, and 41RF1-BP26-131, were found on top of extended Burial 41RF1-BP26-119. This individual was

Table IIA-13. Dimensions of Schmorl's nodes recorded in 41RF1-BP26-126

Vertebra	Superior Surface		Inferior Surface	
	Length (mm)	Width (mm)	Length (mm)	Width (mm)
T6			10	4
T7	12	3		
T10			16	11
T11			24	11
T12	12	6	16	8
L1	24	15	16	10
L2 (?)			24	16
L5	13	8		

identified in the feature due to the moderately gracile size, color and preservation of the elements.

The remains are yellow to light yellow in color. The preservation of the remains are moderate with evidence of some postmortem disturbances, such as postmortem cut marks on the right proximal femur shaft. The individual is represented by a left clavicle, right patella, right humerus, radii, ulnae, femora, tibiae, and fibulae.

Age

The age estimate is based on the presence of the epiphyseal line on the proximal left femur, suggesting that the epiphysis fused recently. Overall, the appearance of the remains is consistent with a young adult, with thick cortical bone and no osteoporotic activity.

Ancestry

The ancestry estimation as possible Native American is based on the presence of a moderately platymetric left femur. This feature is more commonly found in Native American populations.

Sex

The sex estimation is based on the moderately gracile skeleton. The femoral head diameter measures 43 mm. Overall, the remains are gracile with rather long dimensions, and in combination, these features are indicative of a female.

Functional Morphology

This individual has slight postcranial muscle development. The gluteal region is slightly developed. The femora are moderately platymetric.

41RF1-BP26-130

From a Sort

Present is an adult male, aged 20-25 years (code 22), of possible Native American ancestry. The individual consists of commingled elements recovered from a bone cluster above Burial 41RF1-BP26-126. Additional individuals identified in this feature include 41RF1-BP26-122, 41RF1-BP26-123, 41RF1-BP26-130, and 41RF1-BP26-130A. The skeletal elements were sorted based on skeletal size, coloration, development, and bone preservation. The cranium was located between 41RF1-BP26-125 and 41RF1-BP26-126, but a majority of the postcranial elements were recovered from the bone cluster above the lower limbs of 41RF1-BP26-126. The skeletal remains from Burial 41RF1-BP26-130 are in good condition. The skull is fragmentary, but the dentition is nearly

complete. Most of the major long bones are present. The bone is brown to light brown in color.

Age

The age determination of this individual is based on a variety of developmental and degenerative age indicators. The primary age indicators of the pelvis (i.e. auricular surface and pubic symphysis) are absent. The dentition is fully developed. Occlusal wear is slight, and dental disease is absent. Fusion lines of the proximal tibial epiphyses are visible. Several thoracic centra exhibit mild marginal osteophytosis. No osteoarthritic lipping is evident on the appendicular skeleton. The centrum rings of the lumbar and thoracic vertebrae are completely fused to the bodies. The combination of age indicators is consistent with an individual between 20 and 25 years old.

Ancestry

The overall skeletal size is robust, which is consistent with the Karankawa male pattern. The left lateral upper incisor is shoveled. The partial nasal aperture appears relatively narrow, and the subnasal region is not prognathic. The maxillary palate is parabolic with straight palatine sutures. The femur is anterior-posterior elongated, and it is not platymetric. These traits are not consistent with any specific ancestral group, but the dental evident and over skeletal size suggest partial Native American ancestry.

Sex

The morphology of the cranium is indicative of a male individual. The supraorbital torus and suprameatal crest are marked and elevated. The zygomatic bones are robust. The postcranial elements are quite large indicating a male individual.

Dentition

The posterior dentition is well represented in this individual. All but one of the incisors has been lost postmortem. Occlusal wear is slight. Calculus deposits range from small flecks to heavy. The alveolar margin is in good condition and exhibits no periodontal problems.

Functional Morphology

The femoral shaft exhibits antero-posterior elongation. The tibial shafts are relatively round.

Pathology

Skeletal pathological lesions evident in this individual are limited to mild degenerative changes. Mild vertebral

osteophytosis is evident on the margins of the mid and lower thoracic centra.

Postmortem green bone fractures are evident in the midshaft of the right radius and ulna. The breaks show classic “butterfly” fractures (Rockhold and Herrmann 1999) that indicate a force was applied to the anterior surface of the ulna and the antero-lateral surface of the radius. The fractures delimit two small triangular shaped wedges in radius and ulna shafts. The base of these triangles is the location where the force was applied to the shaft. This pattern of fracture is frequently documented in antemortem and perimortem injuries, but has been documented in forensic and archaeological contexts (Ubelaker and Adams 1995; Herrmann 1996). The condition of these fractures and the commingled context of the remains suggest that the breaks occurred postmortem.

Extra Elements

- 1) Five adults teeth, possibly from the same individual. They include both lower lateral incisors, lower left canine, lower left second premolar, and lower left first molar (with a large distal interproximal carious lesion at the CEJ).

41RF1-BP26-130A

From a Sort

These remains are of a female, aged 15-35 years (code 96), of possible Native American ancestry. Legs and feet represent the individual. Although highly fragmented, the preservation of the remains is good. The color of the remains ranges from yellow to brown.

Age

The age estimation is based on the generally young appearance of the remains. However, there is slight arthritic lipping on a few of the joint surfaces. This individual was a young adult aged 15-35 years (code 96), although it is likely that the individual is in the upper range of the age estimation.

Ancestry

The ancestry of the individual is probably Native American. The ancestry is based on the presence of substantial squatting facets on the distal ends of the tibia joints. The left first metatarsal has osteoarthritic expansion, which is probably also the result of squatting.

Sex

The overall gracile appearance of the elements indicates that this individual is female. This is an especially good indicator given the degree of sexual dimorphism observed in the series.

Functional Morphology

This individual displays little postcranial muscle development. The tibia has substantial squatting facets present on the distal joint. The first left metatarsal has osteoarthritic changes, probably also the result of squatting.

Pathology

Only slight pathological changes were observed in this individual. Mild marginal lipping is present on the distal right tibia joint. Also, a right distal phalange is moderately expanded and appears pathological.

41RF1-BP26-131

From a Sort

This male, aged 20-29 years (code 21), of possible Native American ancestry, was identified from a sort in commingled Burial Feature 26. The burials, 41RF1-BP26-113, 41RF1-BP26-114, 41RF1-BP26-128, and 41RF1-BP26-131, were found on top of extended Burial 41RF1-BP26-119. This individual was sorted based on the moderate robusticity of the elements, color, and state of preservation. The remains are yellow to brown in color, with good preservation. This individual is represented by a partial frontal, left patella, left radius, left ulna, and left femur.

Age

The age estimate is based on the presence of the epiphysis line on the proximal left femur, suggesting that the epiphysis had recently fused. Overall, the appearance of the remains is consistent with a young adult, with thick cortical bone and no osteoporotic activity. The proximal left ulna joint has slight arthritic lipping.

Ancestry

The ancestry estimation as possible Native American is based on the presence of a moderately platymetric left femur.

Sex

The sex estimation of male for this individual is based on the moderately robust skeleton. The femoral head diameter measures 49 mm, indicating a male. In addition, the partial

frontal exhibits well-developed supra-orbital ridge size and sharpness, consistent with a male sex estimation.

Functional Morphology

This individual exhibits moderate muscle development. The oblique line on the radius is slightly developed. The gluteal region of the femur is moderately developed, although the linea aspera is only slightly developed. The femur is platymeric.

Pathology

Slight arthritic development is present on the proximal left ulna joint.

41RF1-BP26-I05R

This element is a right os coxa with a small portion of the sacrum fused at the sacroiliac joint. Age is estimated as 20-29 years (code 22), and the sex is estimated as female. Postmortem fragmentation of this element prevents complete analysis. The photograph of the excavation of this burial feature shows this element and associated sacrum as disarticulated from any other associated remains. Sorting of the commingled elements from this burial feature failed to identify a similarly affected right femur.

The entire ilium exhibits healed severe osteomyelitis and deformation, all of which is most likely the result of a traumatic injury that occurred many years before death. This injury resulted in fracturing of the ilium and dislocation of the hip joint. Orientation of the ilium is irregularly displaced laterally in a more horizontal plane. Hypertrophic bone is present on the medial and lateral surfaces. The cortical surface on the medial side is smoother and undulating with several cloaca present. The largest cloaca perforates the ilium and measures 9 mm by 6 mm. The lateral surface exhibits moderate porosity and irregularity. A large oval shaped perforation with smoothed edges is located superior to the acetabulum and measures 31 mm by 13 mm. The lateral anterior edge of the perforation has a complete fracture and pseudoarthrosis.

The original acetabulum shows nearly complete atrophy with only the central non-articulating surface remaining. The location of a secondary articulation is not clear. The bone remains dense and shows no evidence of osteoporosis or atrophy.

Burial Feature 27

41RF1-BP27-098

This individual is an infant, aged newborn to six months (code 01), and is possibly a male of Native American ancestry. This is a primary burial located about one meter from Burial 95. The individual is very fragmentary, but mostly complete. The remains range in color from the typical yellow to brown, and plant root action is evident on most elements.

Age

Age estimation is based on dental and long bone development. The mandibular canine and mandibular first molar exhibit initial coalescence of cusps. The mandibular second molar displays initial appearance of cusps. The ulna measures 60 mm in length. These features correspond to an age of newborn.

Ancestry

Estimation of ancestry as possibly Native American is based on the robust nature of the postcranial elements and development of muscle attachments (see Functional Morphology) for the age of the individual.

Functional Morphology

Despite the young age of this individual, several sites of muscle attachment are marked. The attachment for deltoid on the humerus is slightly developed, and the femur displays both gluteal line formation and development of the linea aspera.

Extra Elements

- 1) Adult calcaneus and cuboid

Burial Feature 28

41RF1-BP28-096

This is a infant, aged newborn to six months (code 01), of unknown sex or ancestry. The remains are moderately complete, but highly fragmented. This individual is represented by a nearly complete cranium, tooth buds, ribs, vertebrae, scapula, clavicles, innominate, humeri, radii, ulnae, and femora.

Age

The age of this individual was determined using tooth development. The three deciduous incisors are crown one-half, and the deciduous canine has cusps in the initial stages of development. The long bones are too fragmentary to determine the maximum lengths, however the overall size of the bones appears to correspond with an age of newborn to six months (code 01).

41RF1-BP28-099

Present is an infant, aged 1.5-2.5 years (code 03), of indeterminate sex and ancestry. This burial is identified as extended and located beneath Burial 41RF1-BP28-096. The individual is very fragmentary and incomplete. The color of the remains ranges from yellow to brown, and root action is present.

Age

Age for this individual is based on an estimate of femur (right) length (155 mm), which corresponds to an age of 1.5-2.5 years.

Functional Morphology

This individual displays well-developed gluteal lines on the femur for the age of the individual.

Burial Feature 30

41RF1-BP30-024

From a Sort

This individual is an adult male, aged 40-44 years (code 25), of possibly Hispanic ancestry. The burial is disarticulated and commingled Burial Feature 30. The remains were commingled with the remains of burials 41RF1-BP30-102, 41RF1-BP30-24, 41RF1-BP30-F01R, and 41RF1-BP30-H01L, and sorting was based on bone preservation, large size of the remains, and the degenerative joint disease found on many of the joint surfaces. The color of the remains ranges from yellow to brown, water damage and root action are evident on most elements. Black staining is present on the humerus, ulna, and femora. Most likely the dark staining results from the nails and other iron objects associated with the bone bed.

Age

Age for this individual is based on an auricular surface morphology and degenerative changes. The auricular surface morphology is consistent with Phase 4-5. The

presence of slight degenerative joint disease on many joint surfaces (see Pathology section) supports an estimated range of 40-44 years.

Ancestry

Ancestry estimation is based on the lack of platymeria on the femora and very poor dental health (see Dentition section). Poor dental health is very often present in groups subsisting on soft, corn based diets consistent with mission food. These criteria indicate a possible Hispanic ancestry.

Sex

Sex for this individual is based on innominate morphology. The width of the sciatic notch is narrow, and the auricular surface is not elevated. In addition, many elements show enlarged sites of muscle attachment. These traits are characteristically male.

Dentition

Dentition for this individual consists solely of the mandibular dentition. Although no evidence of abscessing is present, numerous caries are present. The right and left mandibular second molars have carious lesions on the occlusal surfaces (<½ of the crown) and root caries with pulp exposure. The right mandibular third molar has a root caries with pulp exposure. The left mandibular third molar has a slight pit caries on the occlusal surface, an interproximal caries mesially, and a root caries with pulp exposure due to the caries. Calculus deposits range from slight to heavy, with the heaviest deposits occurring on the right mandibular lateral incisor and canine.

Very pronounced linear enamel hypoplasias are present on the mandibular canines. Wear is moderate to heavy, with the heaviest wear occurring on the mandibular molars. Surface abrasions are present on the mesial surface of the right mandibular central incisor, on the distal surface of the right mandibular lateral incisor, and on the mesial surface of the left mandibular lateral incisor.

Functional Morphology

The humerus displays marked development at the attachments for the deltoid, triceps brachii, and brachioradialis muscles. The ulna also shows marked development of the attachment for the brachialis muscle.

Pathology

This individual displays degenerative joint disease on several elements. Slight marginal osteophytes are located

on the left scapula, the left distal humerus, the right distal humerus, the left proximal ulna, the right proximal ulna, and the right distal femur. Slight marginal porosity is also present on the left distal humerus.

41RF1-BP30-102

From a Sort

This individual is an adult female, aged 30-40 years (code 23), of possibly admixed Hispanic and Native American ancestry. The burial is disarticulated and commingled in Feature 30. Sorting from burials 41RF1-BP30-118, 41RF1-BP30-24, 41RF1-BP30-F01R, and 41RF1-BP30-H01L was based on the bone preservation and the robust morphology of many elements. The color of the bone ranges from yellow to brown, there is black staining on the left clavicle resulting from contact with iron nails associated with the commingled burials, and root action is evident. No skeletal pathology is present.

Age

Age estimation is based epiphyseal fusion and auricular surface morphology. The medial clavicular epiphysis is completely fused. The auricular surface morphology is consistent with Phase 3-4. The lack of degenerative joint disease supports an estimate as young adult.

Ancestry

This individual is possibly of admixed Hispanic and Native American ancestry. Estimation of ancestry is based on the robust nature of the elements. Generally, the Native Americans in this series are characterized by overall robusticity. The maxillary central incisors lack shoveling, and the maxillary lateral incisors display slight shoveling. The femora are round and not platymeric.

Sex

Sex estimation is based on morphology of the os coxa. The mandible and postcranial robusticity are ambiguous as to sex, however the pelvis is a more reliable indicator of sex. The os coxa displays a moderate preauricular sulcus, and the auricular surface is elevated.

Dentition

The dentition is mostly complete, however the maxillary molars are missing postmortem. Slight carious pit lesions are present on the buccal surfaces of the right mandibular first molar and the left mandibular first and second molars. The right mandibular third molar has a small carious pit lesion on the occlusal surface, and the left mandibular third molar has slight carious pit lesions on the occlusal and buccal surface. The right mandibular molars display

moderate alveolar resorption, however no evidence of abscessing is seen on the dentition. Calculus development is slight to coalesced, with the heaviest deposits on the mandibular incisors and canines. Linear enamel hypoplasias occur on the maxillary canines and lateral incisors.

Enamel chipping is present on the right maxillary incisors and canine, left maxillary lateral incisor and premolars, and mandibular central incisors. Wear is moderate, with the heaviest wear occurring on the incisors and canines.

Functional Morphology

As mentioned previously, this female exhibits moderate robusticity. The attachment for the masseter muscle on the mandible is marked. The clavicle exhibits moderate development of the deltoid and pectoralis major. The humerus displays marked development of the deltoid, latissimus dorsi, triceps brachii, and teres major muscles. The femur shows moderate development of the gluteal and adductor muscle groups.

41RF1-BP30-118

From a Sort

This individual is an adult female, aged 20-24 years (code 21), of possibly Hispanic ancestry. The burial is commingled and disarticulated Burial Feature 30. The individual was sorted from 41RF1-BP30-102, 41RF1-BP30-24, 41RF1-BP30-F01R, and 41RF1-BP30-H01L based on the younger age of the elements as well as the gracile nature of the remains. The remains are very incomplete. The color of the remains ranges from brown to yellow, and the left radius displays water damage.

Age

Age estimation is epiphyseal closure and bone condition. The iliac crest is unfused, and the humeral and femoral epiphyses are fused. The bones and joints are youthful in appearance. These criteria support an age estimate of 20-24 years.

Ancestry

Ancestry for this individual is possibly Hispanic based on the occurrence of a small Carabelli's cusps on the maxillary molars. The femora are moderately platymeric, and overall the remains are gracile.

Sex

Sex estimation as female is based on the gracile nature of the remains. The femoral head measures 39 mm in diameter.

Dentition

The dentition for this individual is mostly incomplete. The teeth present are mainly from the left maxillary premolars and molars, and the right mandibular incisors, canine, and premolar. Due to the postmortem loss of alveolar structure, abscessing cannot be assessed. Calculus development is light to moderate, with the heaviest deposits occurring on the right mandibular canine and first premolar. The right maxillary first premolar and right mandibular canine exhibit enamel chipping. Linear enamel hypoplasias occur on the right mandibular canine and first premolar and the maxillary premolars.

Functional Morphology

The deltoid tuberosity on the humerus is slightly developed. The femora exhibit moderate antero-posterior elongation.

Burial Feature 31**41RF1-BP31-105**

This individual is an adult female, aged 35-45 years (code 25), of Native American ancestry. The burial is primary and extended in Feature 31. The skeleton is mostly complete, but fragmentary. The color ranges from yellow to brown, water damage is present on many elements, and root action is evident.

Age

Age estimation is based on an auricular surface morphology, degenerative joint conditions, and cranial suture closure. The auricular surface morphology is consistent with a Phase of 4-5. Many joints exhibit osteophyte formation. The ectocranial and endocranial midlambdoidal sutures are more than 50 percent closed. These criteria suggest an age range 35-45 years.

Ancestry

Ancestry assessment is based on postcranial morphology. The individual displays marked platymeria on both femora and large squatting facets on both distal tibiae. The remains show moderate development in many areas of muscle attachment, which is typical of many Native Americans in this series.

Sex

Sex estimation is based on innominate morphology. The ischio-pubic ramus ridge is narrow, and there is a preauricular sulcus present. These features are indicative of female.

Dentition

The dentition for this individual is incomplete, with the maxillary dentition possessing the fewest elements. The left maxillary second molar and right mandibular second molar have small occlusal caries. The left mandibular second molar has an occlusal caries on affecting less than 50 percent of the surface. No evidence of abscessing is present on any of the alveolar bone.

Overall, wear is light to moderate, with the heaviest wear on the mandibular canines and incisors. Calculus development is light to moderate. The heaviest calculus deposits are on the mandibular canines and incisors. Linear enamel hypoplasias are present on all of the mandibular teeth. The most marked defects are on the canines and first premolars.

Functional Morphology

The radial tuberosity is marked on the radius, and the attachment for pronator quadratus is moderately developed on the ulna. The gluteal muscle group on the femora also shows marked development. This individual displays large squatting facets on both distal tibia, and marked platymeria on the femora.

Pathology

This individual displays slight marginal osteophyte formation on the right distal humerus, proximal left and right ulnae, and the distal left and right femora. The left femur also displays myositis ossificans on the distal $\frac{1}{3}$ shaft along the medial and lateral supra-condylar lines. The ossification could possibly be related to a tear or sprain of the attachment of the adductor magnus.

41RF1-BP31-110

This individual is a young adult (code 96) male of indeterminate ancestry. This individual is identified as a secondary scatter of elements located at the feet of Burial 41RF1-BP31-105. The individual is very incomplete and is only represented by a right tibia and fibula. The color of the remains ranges from yellow to brown, and root action is evident.

Age

Age is estimated as young adult based on the lack of any degenerative joint disease on the tibia.

Sex

Sex for this individual is male based on the robust nature of the elements present.

Functional Morphology

This individual displays a well-developed interosseous crest on the tibia and fibula and a well-developed attachment for soleus on the tibia.

Burial Feature 32**41RF1-BP32-029**

This individual is an old adult (code 97), possibly male of indeterminate ancestry. This individual is identified as a primary disturbed burial, which was disturbed by a pipe trench. The crania, arms, and chest area was disturbed by the trench, and only the legs, carpals, tarsals, a few small rib and vertebral elements are present. The remains range from yellow to brown in color, water and root damage is evident on the right and left tibia.

Age

Age for this individual is estimated as old adult based on marginal trabecular bone loss in the right and left tibia, as well as the arthritic lipping and porosity in the carpals.

Ancestry

Ancestry for this individual is indeterminate due to the lack of any distinctive elements. There is mild platymeria on the femurs.

Sex

Sex for this individual is probable male based on the robust nature and overall size of the represented elements.

Functional Morphology

This individual displays developed attachments for the gluteal and adductor muscles on the femora, as well as marked development of the soleus muscles and interosseous crest on the tibia and fibula.

Pathology

This individual has severe arthritic lipping, porosity, and eburnation on the left lunate, navicular, and capitate possibly resulting from a fracture.

There is also a slight, localized, healed periostitis on the right tibia.

Burial Feature 33**41RF1-BP33-115**

Only highly fragmented left leg bones represent this individual. Present are fragments of the femur, patella, tibia, and fibula. Due to the highly fragmentary nature of the remains only general demographic categories were estimated for this individual. This individual was estimated to be a probable young adult male of indeterminate ancestry.

Age

This individual was determined to be a young adult based on the density of the bone and the lack of arthritic alterations on the joint surfaces.

Sex

This individual was determined to be probable male based on the general size and robusticity of the elements.

Burial Feature 34**41RF1-BP34-106****From a Sort**

Present is a male, aged 25 to 34 years (code 22), of indeterminate ancestry. The burial is represented by incomplete and fragmentary skeletal remains including the right maxilla and associated teeth, distal right humerus, right radius, proximal and distal ends of the left radius, proximal right femur, and two rib fragments. This individual was initially commingled with the other burials from Feature 34. The elements were sorted and matched based on age, morphology and color of the elements.

Age

Age was determined to be between 25 and 34 years based on the lack of degenerative joint disease, slight tooth wear, the density of the trabecular bone and the overall appearance of the elements.

Sex

The sex of this individual was determined to be male based on the diameter of the femoral head and the overall size and robusticity of the elements. The femoral head measures 45 mm in diameter indicating the individual to be male.

Dentition

Several maxillary teeth were matched to this individual based on morphology and coloration of the associated maxilla fragment and the morphology of the teeth. Teeth present include the right maxillary second premolar and first and second molar. The second left molar is also present though not in occlusion. All the teeth exhibit flecks to moderate calculus deposits. The teeth display only mild wear. The left second molar exhibits a small enamel pearl on the root.

41RF1-BP34-106A**From a Sort**

This male, aged 50 to 54 years (code 27) of possible Native American ancestry, is represented by an incomplete highly fragmentary skeleton. Elements include cranial, mandible, a fragment of the right acetabulum, proximal right femur, and five fragmentary ribs. This individual was initially commingled with the other burials from Feature 34. The elements were sorted and matched based on age, morphology, and color of the elements.

Age

This individual was determined to be between 50 and 54 years of age based on the presence of moderate degenerative joint disease, Pacchionian pits, and rather heavy dental wear.

Ancestry

Ancestry estimation was complicated by the lack of complete cranio-facial elements. However, ancestry is estimated to be probable Native American based on the morphology of partial maxilla, heavy dental wear, and size of the elements. A slight nasal sill and nasal spine is present. The dental wear exhibited is generally not considered heavy, but is rather heavy for this skeletal series and is consistent with individuals determined to be Native American. The size of the femur is also consistent with the Native American individuals from this series.

Sex

This individual was determined to be male based on the size and morphology of the mandible and the femoral head. The mandible is overall large and robust, and the femoral head measures 48 mm in diameter. The features indicate male as sex.

Dentition

Nearly all the mandibular teeth are present and in occlusion, while only three loose maxillary teeth are present. The right maxillary first incisor and first molar, and the left second

premolar exhibit flecks to moderate calculus deposits and moderate wear. The mandibular dentition is nearly complete, only the right canine and left first and second incisors are missing. Calculus deposits range from flecks to coalesced. Dental wear is from slight to moderate.

Several of the teeth exhibit antemortem chipping. The right first molar has a chip measuring 3 mm by 3 mm on the distal lingual surface. Similarly the left first molar has a chip measuring 3 mm by 4 mm on the distal-buccal surface. The left canine displays an antemortem chip on the anterior margin, measuring 3 mm by 2 mm. No caries or abscesses were present.

Pathology

This individual exhibits mild healed ectocranial porosity on the frontal and parietals. This individual also displays moderate arthritic changes on the femoral head and the rib heads. The surface of the femoral head has both moderate osteophyte development and porosity just superior and posterior to the fovea capita. The margin of the femoral head similarly has moderate osteophytic lipping and porosity. The lipping on the inferior posterior surface of the margin is well pronounced, actually projecting 4 mm off the edge of the head. The rib heads exhibit mild osteophytic development and porosity.

41RF1-BP34-106B**From a Sort**

This young adult male is represented by a pathological left ulna and scapula and right clavicle, and several rib fragments and sternum fragments. The individual was initially commingled with the other burials from Feature 34. The elements were sorted and matched based on pathology, age, morphology, and color of the elements.

Age

Age is estimated to be young adult based on the lack of arthritic changes on the joint surfaces. The age of this individual was complicated by the pathology exhibited by the elements, thus only the broad age range of young adult was estimated.

Sex

This individual was determined to be male based on the large proximal ulna.

Pathology

The left ulna and scapula as well as the right clavicle are pathological. The pathological alterations of the ulna and

scapula are diagnostic of a treponemal infection (syphilis). The ulna exhibits severe periostitis/osteomyelitis. The entire shaft of the bone is swollen by periosteal bony build up. The swelling is best appreciated by the measurements of the midshaft, 23 mm anterior-posterior, and 24 mm medial-lateral. Several rather large lytic defects are present on the outer surface of the bone. These defects extend into the cortex of the cortical bone, appearing as scooped out regions, characterized by thin rough edges. The largest of these lesions is located on the lateral surface, just posterior to the supinator crest. The lesion measures approximately 15 mm proximal-distal (p-d) by 6 mm medial-lateral (m-l) and is 5 mm deep. Another lesion, measuring 5 mm (p-d) by 3 mm (m-l) and 3 mm deep, is located on the posterior surface, just below the olecranon. Several defects are present on the anterior surface of the distal third of the shaft. The margins of these defects are smoother than the proximal defects, suggesting that these defects may be the result of small sequestra. The largest in this area measures 7 mm (p-d) by 3 mm (m-l) and 4 mm deep. Postmortem damage at this location provides a view of the medullary cavity. The cavity is almost completely obliterated by endosteal bone formation. While the shaft of the ulna has been greatly altered, the joint surfaces do not appear to have been affected.

Although the scapula is highly fragmented by postmortem damage, several fragments are clearly pathological. The blade exhibits several small lesions that have completely perforated the bone. The margins of these lesions are smooth and clearly the result of antemortem pathology. The fragmentary nature of the element prohibits dimensional measurements of all but one of the lesions. A lesion located at the junction of the lateral border and the blade measures 9 mm (p-d) by 4 mm (m-l). The lesions are very similar to those displayed in Ortner and Putschar (1985) page 196, Figure 302.

The left clavicle exhibits a complete fracture of the lateral end. Osteomyelitis has resulted due to the fracture and infected the entire bone. The fracture itself appears to be completely healed, although with additional bone growth and deformity of the lateral end. The area of the fracture displays the remodeling and bone development common for a healed or healing fracture. The bone in this region has lost the original shape to become wider and thicker with a rough and rugged appearance. Posteriorly a rather large projection of bone extends away from the element toward the scapula. An articulation facet present at the extreme end of this projection indicates likely articulation with the

scapula. The extent of deformity, due to both the fracture and osteomyelitis, precludes assessment of the exact fracture location. The osteomyelitis has given the bone a swollen appearance. There are at least five cloaca present on the clavicle. The largest is located on the lateral end of the superior surface of the element and measures 11 mm in diameter. Several small cloaca are present in the surrounding area, and two other cloaca are located near the medial end of the clavicle on the superior surface.

41RF1-BP34-108

From a Sort

This child, aged 2.5 to 3.5 years (code 03), is represented by a nearly complete skeleton. Missing elements include the facial bones, several ribs, the right ulna, left femur, left tibia, left fibula, hand and foot bones, and most of the epiphyses. The remains have been highly fragmented by postmortem damage. The burial was initially commingled with the other burials from Feature 34. Sorting was based on age and condition of the material.

Age

Age estimation is based on dental calcification. The teeth present include the deciduous right canine, right first molar and left second molar. The canine and first molar are apex complete, and the second molar is apex $\frac{1}{2}$ indicating an age of 2.5 to 3.5 years

41RF1-BP34-108A

From a Sort

This child, aged 4.5 to 5.5 years (code 06), is represented only by fragmented maxillae and teeth. The remains have been highly fragmented by postmortem damage. The burial was initially commingled with the other burials from Feature 34. Sorting was based on age and condition of the material.

Age

Estimation of age is based on dental calcification. The deciduous teeth present are all apex complete, and the development of the permanent teeth provide the age estimate. The first maxillary incisor is crown complete, the mandibular first and second incisors are root initial, the mandibular second premolar is crown $\frac{3}{4}$ and the mandibular second molar is crown $\frac{1}{2}$.

Ancestry

The nature of the remains precludes estimation of ancestry. However, the right first molar has a Carabelli's cusp, suggesting possible Hispanic ancestry for the individual.

Dentition

Most of the permanent teeth are loose unerupted crowns. Present are the right first maxillary incisor, and first and second premolars, the left maxillary first and second incisors (still in the maxilla), the canine and first molar. Mandibular teeth include the right first and second incisors, canine and second molar; and the left first and second incisors and second molar. The teeth show little to no wear and no caries are present.

Burial Feature 35

41RF1-BP35-134

This individual is a robust male, age 30 to 40 years, of possible Hispanic ancestry. This individual represents a primary burial that was disturbed by modern road construction and a pipeline. Nearly all postcranial elements are present, but several bones are extremely fragmentary. The bone color is yellow to brown, and root damage is evident. The crania, distal segments of the lower limb bones, and the feet are missing. A pipeline trench cut the area near the head. Several metal buttons and a lead bullet fragment are associated with this individual. The lead bullet was found embedded in the cancellous bone of the right proximal tibia. Green staining evident on several bones is associated with the metal buttons.

Age

The age estimate is based on the available pelvic indicators, the degree of osteoarthritic activity, epiphyseal closure, and dental attrition. The pubic symphysis morphology classifies as a Todd Phase 7 or greater and a Suchey-Brooks Phase 5 or greater. The auricular surface morphology is consistent with Phase 3 (Lovejoy et al. 1985). These characteristics are consistent with an individual between 30 and 40 years.

Ancestry

No primary cranial indicators of ancestry are present. The proximal femora display slight platymeria. The presence of metal buttons with this burial suggests that this individual is of Hispanic or European descent.

Sex

Sex for this individual is based upon general robusticity of the postcranial skeleton, a well-developed mandibular mental eminence, and well marked muscle attachments. The maximum diameter of the femoral head measures 49 mm and the vertical diameter of the humeral head measures 50 mm. Both measures are large and suggest a male individual.

Dentition

Dentition is limited to mandibular teeth. Occlusal wear ranges from moderate attrition on posterior teeth to slight attrition on the anterior teeth. The left third molar exhibits a small enamel chip. Calculus deposits are moderate to heavy. Slight linear enamel hypoplasias are evident on the lower canines. A carious root lesion is present on lower left first molar. Alveolar resorption is moderate, especially along the posterior dentition.

Functional Morphology

The ulnae display well-developed pronator quadratus attachments and interosseous crests. This individual exhibits moderate development of the metacarpals and carpals. The ridges for the fibrous flexor sheath are marked along the palmar surface of the proximal phalanges. The deltoid attachment on right lateral clavicle is roughened and raised. The humerus shafts display marked attachments of the deltoid and the lateral head of the triceps muscle. The lateral supracondylar ridge is well marked. This pattern suggests activities associated with heavy flexion and extension of lower arms. The linea aspera and gluteal tuberosity are well-developed on the femora.

Pathology

Thoracic and lumbar vertebrae display mild marginal lipping and porosity on the centra and mild marginal lipping on the superior facets. Left and right humeri display mild marginal lipping along the distal joint surface. Right and left proximal ulna display slight marginal lipping, and the left has marginal porosity along the coronoid process. Distal radii display mild marginal lipping bilaterally on distal joint surfaces, and the left has mild marginal porosity on the distal joint surface.

The right distal femur displays a healed incomplete fracture of the medial condyle. The fracture line transects the entire articular surface and extends from the medial margin of the condyle to the lateral intercondylar margin. The distal third of the condyle is displaced 0.2 mm superiorly. The intercondylar fossa displays a 10 mm defect, which may correlate to the attachment site of the cruciate ligament. A radio-opaque scatter is evident extending from the intercondylar fossa defect through the medial epicondyle. The superior and anterior-posterior radiographs indicate that the radio-opaque scatter in a anterior-medial-superior angle from the intercondylar fossa. A lead bullet was recovered near the proximal right tibia indicating that the individual may have been shot in the distal femur at least six months prior to death. The bullet lodged in the soft tissue near the knee. No radio-opaque objects are visible in the proximal right tibia.

The distal right femoral condyles displays moderate marginal lipping. There is bilateral marginal lipping and mild surface osteophytes on the patellar surface. The right patellar surface displays mild porosity along the articular margin and surrounding the surface osteophytes. There is bilateral marginal lipping on the proximal tibia joint surfaces. Both tibiae exhibit uniform postmortem chop marks along the anterior crest. These chops are the result of the pit being disturbed long after the individual was buried.

Burial Feature 36

41RF1-BP36-132

Present are the incomplete skeletal remains of a probable male, aged 15 to 17 years of indeterminate ancestry. Elements present include the left scapula, clavicle, patella, incomplete left and right tibiae and fibula, most ribs, and nearly all the vertebrae. Postmortem breakage has resulted in highly fragmentary remains.

Age

Age estimation is based on the development of the long bones. The proximal tibia, distal fibula and distal metatarsals are all unfused, indicating an age between 15 and 17 years.

Sex

The sex estimation of probable male is based on the size and robusticity of the elements. Though a young individual, the elements are rather large. The fragmentary nature of the elements prohibits metric analysis.

Extra Elements

- 1) Four cervical vertebrae of an old adult are present – exhibit severe porosity on the centra.
- 2) Proximal half of an infant femur is present – became 41RF1-BP36-F01L.
- 3) The left foot bones of a young adult are also present.

41RF1-BP36-133

This individual is an adult male, aged 21-29 years (code 22) of indeterminate ancestry. This burial is identified as an extended burial directly above Burial 41RF1-BP36-135. A mostly complete postcranial skeleton represents this individual. A pipe trench running just north of the burial feature disturbed the cranial elements. The remains range in color from yellow to brown, and root action is evident.

Age

Age estimation is based on features of the os coxa and incomplete fusion of the thoracic and lumbar vertebral rims. The pubic symphysis morphology is consistent with Todd's Phase 2-3 and Suchey-Brooks' Phase 1-2. The auricular surface morphology is consistent with Lovejoy's Phase 2. All of these features indicate an age range of 21-29 years.

Ancestry

Ancestry estimation is indeterminate based on the lack of any distinctive characteristics and the lack of any cranial elements. There is slight platymeria on the femora.

Sex

Estimation of sex is based on the overall large size of the elements. The femoral head measures 48 mm in diameter.

Dentition

This individual has only one tooth associated. The maxillary left central incisor displays slight wear and moderate calculus development.

Functional Morphology

This individual, while having a large postcranial skeleton, does not display many marked areas of muscle development. The gluteal muscle group attachments on the femora display moderate development. Large squatting facets are present on the distal tibia.

41RF1-BP36-135

This individual is an adult male, aged 25-29 years (code 22) of possibly Native American ancestry. The burial is identified as a primary and extended located directly beneath Burial 41RF1-BP36-133. This individual is complete, except for the cranial elements that were disturbed by an intruding pipe trench. The remains range in color from yellow to brown, and root action is evident.

Age

Age estimation is based on innominate morphology and closure of the medial clavicle. The pubic symphysis morphology is consistent with Todd's Phase 4-5, and the auricular surface morphology is consistent with Lovejoy's Phase 2. The medial clavicle has recently fused and retains some marginal porosity present from the last stages of fusion.

Ancestry

Estimation of ancestry as possibly Native American is based on the robust nature of the postcranial elements in comparison with other Native Americans identified in this series. However, due to the absence of cranial elements, the estimate is tentative.

Sex

Sex estimation as male is based on the robusticity of the postcranial elements. The femoral head diameter measures 50 mm. These characteristics are strongly indicative of males.

Functional Morphology

This individual displays an overall well-developed postcranial skeleton. The attachment for deltoid and pectoralis on the right and left clavicle are marked. The humerus displays marked development of the attachment for deltoid, pectoralis major, and triceps brachii muscles. The attachments for the gluteal and adductor muscle groups on the right and left femur are moderately developed. The tibia exhibits marked development for soleus. This individual also displays slight squatting facets on both distal tibia.

Pathology

This individual has a rather pronounced and deep Schmorl's depression on the superior portion of the first lumbar vertebra. The dimensions are a-p = 8.3 mm, m-l = 8 mm, and depth = 2.8 mm. The margins of this depression are irregular possibly suggesting a relatively recent event. Other lumbar vertebrae exhibit the slight markings of similar irregularities, however have not reached the depression stage. The left distal femur articular surface has a slight marginal osteophyte.

Burial Feature 37**41RF1-BP37-137**

This individual is a subadult aged 9.5 to 11.5 years (code 11) of unknown sex or ancestry. The upper torso and cranium were disturbed during earlier road construction, and only a few upper body elements are present. The skeletal material is fragmentary, and only the right fibula could be reconstructed. The bone is orange-brown in color with areas of water damage on most elements. The sex and ancestry of this individual could not be determined. A second individual, 41RF1-BP37-138, is associated with this burial. The second burial consists of three major long bones and two teeth, which were placed above and to the north of 41RF1-BP37-137.

Age

The age of this individual is based on the length of the right fibula diaphysis (approximately 270 mm). The estimated length correlates to an age of 9.5 to 11.5 years.

Pathology

The anterior distal shaft of the femora at the epiphyseal junction have two to three bony ridges which appear to be growth arrest lines. The area between the ridges is loose woven bone and the ridges are comprised of denser woven bone or lamellar bone. These growth interruptions may relate to antemortem stress episodes.

41RF1-BP37-138

This individual is a child aged 2.5-3.5 years (code 04) of indeterminate sex and ancestry. These remains are associated with 41RF1-BP37-137. The individual is represented by a humerus, radius, femur, and two deciduous teeth. The remains show good preservation and are yellow to brown in color.

Age

The age of this individual was determined using the measurement from the complete right femur. The femur length of 218 mm corresponds to an age of 3.5-4.5 years. The dental development of the deciduous maxillary canine is apex ½, which corresponds to an age of 2.5-3.5 years. The dental development is generally a better indicator of age, therefore, the age of this individual was determined to be 2.5-3.5 years.

Burial Feature 38**41RF1-BP38-136**

This individual is a child, aged 4.5-5.5 years (code 06), of possibly Hispanic ancestry. Due to the young age, sex is indeterminate. This primary extended burial is located closest to what is referred to as the altar. The remains are highly fragmentary, color ranges from yellow to brown, and root action is evident.

Age

Age estimation is based on dental development and the open epiphyses on the long bones. The mandibular canine is crown complete, the mandibular first premolar is crown ¾, and the mandibular second premolar is crown ½. These features correspond to an age range of 4-5.

Ancestry

Ancestry is estimated as possibly Hispanic based on dental morphology. The deciduous maxillary incisors show moderate shoveling, and a Carabelli's cusp is present on both the deciduous and permanent maxillary first molar. The shovel-shaped morphology is characteristic of Native American ancestry, and Carabelli's cusps are characteristic of European ancestry. Because of the presence of both features, ancestry is estimated as admixed or Hispanic.

Dentition

The dentition of this individual is mostly complete. Although the bony structures of the maxillae and mandible are missing postmortem, the deciduous dentition would have been firmly in place, and the permanent dentition present is unerupted or partially erupted. Calculus is absent, and wear is slight on the deciduous dentition. Pit hypoplasias are present on the deciduous mandibular canines.

Functional Morphology

The radial tuberosity displays slight development.

Burial Feature 39**41RF1-BP39-139**

This individual is identified from photographs as a primary, articulated burial. The remains are highly fragmented and very poorly preserved. Consequently, most of the bones are unidentifiable. Examination of the photograph of the *in situ* burial indicates that the cranial and thorax areas are represented. This individual is tentatively estimated to be a probable older adult female of unknown ancestry. The remains are yellow to brown in color, and root action is evident.

References Cited

- Bass, W. M.
1995 *Human Osteology: A Laboratory and Field Manual*. 4th edition. Missouri Archaeological Society, Columbia, Missouri.
- Brooks, S. T., and J. M. Suchey
1990 Skeletal Age Determination Based on the Os Pubis: A Comparison of the Acsadi-Nemeskeri. *Human Evolution* 5:227-238.
- Cervantes, C. D., F. Lefshitz, and J. Levenbrow
1988 Radiologic Anthropometry of the Hand in Patients with Familial Short Stature. *Pediatric Radiology* 18(3):210-214.
- Galloway, A. (editor)
1999 *Broken Bones: Anthropological Analysis of Blunt Force Trauma*. Charles C. Thomas, Springfield, Illinois.
- Herrmann, N. P.
1996 Appendix A: A report on the human burials from McCroskey Island, 40SV43, In *RR Polhemus: Phase III Archaeological Survey and Monitoring During Construction of the McCroskey Island Wastewater Treatment Plant Expansion, Sevier County, Tennessee*. Prepared for Jordan, Jones and Goulding, and Sevierville Water System.
- Hillson, S., C. Grigson, and S. Bond
1998 Dental Defects Congenital Syphilis. *American Journal of Physical Anthropology* 107:25-40.
- Jacobi, K. P., D. Collins Cook, R. S. Corruccini, and J. S. Handler
1992 Congenital Syphilis in the Past: Slaves at Newton Plantation, Barbados, West Indies. *American Journal of Physical Anthropology* 89:145-158.
- Lester, C. W., and H. L. Shapiro
1968 Lumbar Vertebrae of Pre-historic American Eskimos: A Study of Skeletons in the American Museum of Natural History, Chiefly from Point Hope, Alaska. *American Journal of Physical Anthropology* 28:43.
- Lovejoy, C. O., R. S. Meindl, T. R. Pryzbeck, and R. P. Mensforth
1985 Chronological Metamorphosis of the Auricular Surface of the Ilium: A New Method for the Determination of Adult Skeletal Age at Death. *American Journal of Physical Anthropology* 68:47-56.
- McKern, T. W., and T. D. Stewart
1957 *Skeletal Changes in Young American Males, Technical Report EP-45*. Headquarters, Quartermaster Research and Development Command. Natick, MA.
- Merbs, C. F.
1996 Spondylolysis of the Sacrum in Alaskan and Canadian Inuit Skeletons. *American Journal of Physical Anthropology* 101(3):357-367.
- Ortner, D. J., and J. G. Putschar
1985 *Identification of Pathological Conditions in Human Skeletal Remains*. Smithsonian Contributions to Anthropology, No. 28. Smithsonian Institution Press, Washington, D.C.

Regan, W., and B. Morrey

1989 Fractures of the Coronoid Process of the Ulna. *Journal of Bone and Joint Surgery* 71:1348-1354.

Regan, M. H., D. T. Case, and J. C. Brundige

1999 Articular Surface Defects in the Third Metatarsal and Third Cuneiform: Nonosseous Tarsal Coalition. *American Journal of Physical Anthropology* 109:53-65.

Rockhold, L., and N. Herrmann

1999 A case study of a hit and run fatality. In *Broken Bones: Anthropological Analysis of Blunt Force Trauma*, edited by A. Galloway, pp. 287-290. Charles C. Thomas, Springfield, IL.

Scharplatz, D., and M. Allgower

1976 Fracture Dislocation of the Elbow. *Injury* 7:143-159.

Seinsheimer, F.

1978 Subtrochanteric Fractures of the Femur. *Journal of Bone and Joint Surgery* 60:300-306.

Stewart, T. D.

1956 Examination of the Possibility that Certain Skeletal Characters Predispose to Defects in the Lumbar Neural Arches. *Clinical Orthopaedics and Related Research* 8:44.

Takayuki, M., T. Shuhei, and R. Nakamura

1986 Brachymetacarpia and Brachyphalangia. *The Journal of Hand Surgery* 11:829-836.

Todd, T. W.

1921 Age Changes in the Pubic Bone III: The Pubis of the White Female. *American Journal of Physical Anthropology* 4:1-70.

Ubelaker, D. H.

1978 *Human Skeletal Remains: Excavation, Analysis, Interpretation*. Aldine Manuals on Archeology, Chicago, IL.

1989 *Human Skeletal Remains: Excavation, Analysis, Interpretation*. 2nd edition. Taraxacum, Washington, D.C.

Ubelaker, D. H., and B. J. Adams

1995 Differentiation of Perimortem and Postmortem Trauma Using Taphonomic Indicators. *Journal of Forensic Sciences* 40:509-512.

Wright, L. E.

1997 Intertooth Patterns of Hypoplasia Expression: Implications for Childhood Health in the Classic Maya Collapse. *American Journal of Physical Anthropology* 102(2):223-247.

Volume II
Osteological Analyses

Mission Refugio

Appendix IIB
Inventory and Coding Forms

SKELETAL INVENTORY			
COMPID:			
SITE:		DATE:	
FEATURE:		RECORDER:	
BURIAL NO.:			

RACE:

SEX:

AGE:

<u>CRANIAL BONES</u>	LEFT	RIGHT	SINGLE
FRONTAL			_____
PARIETAL	_____	_____	
OCCIPITAL			_____
TEMPORAL	_____	_____	
ZYGOMATIC	_____	_____	
MAXILLA	_____	_____	
PALATINE	_____	_____	
MANDIBLE			_____
HYOID			_____
<u>POSTCRANIAL BONES</u>	LEFT	RIGHT	SINGLE
STERNUM			
MANUBRIUM			_____
BODY			_____
XIPHOID			_____
SCAPULA	_____	_____	
CLAVICLE	_____	_____	
INNOMINATE	_____	_____	
SACRUM			_____
COCCYX			_____
PATELLA	_____	_____	
FOOT BONES			
TALUS	_____	_____	
CALCANEUS	_____	_____	

<u>LONG BONES</u>		LEFT	RIGHT		
HUMERUS		_____	_____		
RADIUS		_____	_____		
ULNA		_____	_____		
FEMUR		_____	_____		
TIBIA		_____	_____		
FIBULA		_____	_____		
<u>JOINT SURFACES</u>					
TEMPOROMANDIBULAR		_____	_____		
HUMERUS - PROXIMAL		_____	_____		
HUMERUS - DISTAL		_____	_____		
RADIUS - PROXIMAL		_____	_____		
RADIUS - DISTAL		_____	_____		
ULNA - PROXIMAL		_____	_____		
ULNA - DISTAL		_____	_____		
INNOMINATE - ACETABULUM		_____	_____		
INNOMINATE - SACROILIAC		_____	_____		
FEMUR - PROXIMAL		_____	_____		
FEMUR - DISTAL		_____	_____		
TIBIA - PROXIMAL		_____	_____		
TIBIA - DISTAL		_____	_____		
<u>RIBS</u>		LEFT	RIGHT	NO. COMPLETE	
				LEFT	RIGHT
1ST		_____	_____		
2ND		_____	_____		
3RD-10TH		_____	_____	_____	_____
11TH		_____	_____		
12TH		_____	_____		
<u>VERTEBRAE</u>		<u>SINGLE</u>			
C1		_____			
C2		_____			
C3-C6		_____		_____	
C7		_____			
T1-T9		_____		_____	
T10		_____			
T11		_____			
T12		_____			
L1-L5		_____			
L1		_____			
L2		_____			
L3		_____			
L4		_____			
L5		_____			

Taphonomy Observations and Coding**CATKEY** _____**FEATURE** _____**INDIVIDUAL** _____ (Burial Number)**STATE** _____**SITE** _____**AFFILIATION** _____ **AGE** _____ **SEX** _____ **REC'R** _____**DATE** _____**General color of bone** _____ (Assign one of the numeric codes listed)

1. Natural Ivory color
2. Yellow to brown
3. Black
4. Grey
5. White

Bone weathering stage (Behrensmeyer, stages 0-5): _____**Staining**

(code: enter 1 if present, otherwise leave blank)

- ___ Green (copper)
- ___ Green (algae)
- ___ Red (ochre, cinnabar, vermillion)
- ___ Black
- ___ Other

D) Surface and Shape Changes

(code: enter 1 if present, otherwise leave blank)

- ___ Sun Bleaching
- ___ Chemical Bleaching
- ___ Surface exposure not involving sunlight
- ___ Plant root damage
- ___ Rodent tooth marks
- ___ Carnivore tooth marks

- ☐ Warping due to ground pressure
- ☐ Burning (describe on Burned Bone data form)

E) Cultural Modification

(code: enter 1 if present, otherwise leave blank)

- ☐ Cut marks
- ☐ Intentional Fracturing
- ☐ Post-mortem drilling, cutting, or other modification

F) Adherent Materials

(code: enter 1 if present, otherwise leave blank)

- ☐ Dessicated tissue
- ☐ Textile or textile impressions
- ☐ Hair or fur
- ☐ Unknown material

G) Museum Preparation and Modification

(code: enter 1 if present, otherwise leave blank)

- ☐ Post-mortem cut marks produced during maceration
- ☐ Drilling, attachment of nails or other hardware
- ☐ Preservatives or glue applied to bone or teeth
- ☐ Plaster or other reconstruction materials applied to specimen
- ☐ Samples removed by cutting or drilling

AGE AND SEX DETERMINATION

Catalog no. _____ Recorder _____ Date _____

SKELETAL AGING

1) Dental development

Age _____

Deciduous

canine _____

m1 _____

m2 _____

Permanent

Maxillary I1 _____

Maxillary I2 _____

Mandibular I1 _____

Mandibular I2 _____

Mandibular C _____

Mandibular Pm1 _____

Mandibular Pm2 _____

Mandibular M1 _____

Mandibular M2 _____

Mandibular M3 _____

2) Epiphyseal union

Age _____

Metopic suture _____

Mental symphysis _____

Lateral to basilar _____

Lateral to squamous _____

Basilar suture _____

C halves of arch _____

C arch to centrum _____

C vert superior rim _____

C vert inferior rim _____

T halves of arch _____

T arch to centrum _____

T vert superior rim _____

T vert inferior rim _____

L halves of arch _____

L arch to centrum _____

L vert superior rim _____

L vert inferior rim _____

Scapula coracoid _____

Scap. glenoid cavity _____

Scap. acromium _____

Scap. inferior angle _____

Scap. medial border _____

Clav. sternal end _____

Proximal humerus _____

Distal humerus _____

Humerus epicondyle _____

Proximal radius _____

Distal radius _____

Proximal ulna _____

Distal ulna _____

Ilium to pubis _____

Ischium to pubis _____

Ischium to ilium _____

Ischial tuberosity _____

Iliac crest _____

Proximal femur _____

Greater trochanter _____

Lesser trochanter _____

Distal femur _____

Proximal tibia _____

Distal tibia _____

Proximal fibula _____

Distal fibula _____

S1-S2 _____

S2-S3 _____

S3-S4 _____

S4-S5 _____

3) Subadult Bone Measurements

Age _____

C vert max length _____

T vert max length _____

L vert max length _____

Scapula max length _____

Clavicle max length _____

Humerus max length _____

Radius max length _____

Ulna max length _____

Os pubis max length _____

Femur max length _____

Tibia max length _____

Fibula max length _____

4) Pubic Symphysis and Auricular Surface

Age _____

	Left	Right	Score
Todd pubic scoring	phase _____	phase _____	_____
Suchey-Brooks pubic scoring	phase _____	phase _____	_____
Auricular surface scoring	group _____	group _____	_____

5) Cranial suture closure

(Ectocranial)

(Endocranial)

	L	R		L	R		L	R
Midlambdoid	_____	_____	Inf. sphenotemporal	_____	_____	Sagittal	_____	_____
Lambda	_____	_____	Sup. sphenotemporal	_____	_____	Coronal	_____	_____
Obelion	_____	_____	Incisive suture	_____	_____	Lambdoid	_____	_____
Ant. Sagittal	_____	_____	Ant. med. palatine	_____	_____			
Bregma	_____	_____	Post. med. palatine	_____	_____			
Midcoronal	_____	_____	Transverse palatine	_____	_____			
Pterion	_____	_____	Grt. palat. foramina	_____	_____	Age	_____	_____
Sphenofrontal	_____	_____						

Range _____ Prob. Age _____

Min/Max _____ Code _____

SKELETAL SEXING

Sex designation _____
Code _____

Ventral arc	_____	Nuchal crest	_____
Subpubic concavity	_____	Mastoid process	_____
Subpubic angle	_____	Supra-orbital sharpness	_____
Ischio-pubic ramus ridge	_____	Supra-orbital ridge size	_____
Greater sciatic notch width	_____	Mental eminence size	_____
Preauricular sulcus	_____	Mental shape	_____
Auricular surface elevation	_____	Femur head diam (F<42.5,47.5>M)	_____
Curvature of the sacrum	_____	Humerus head diam (F<43,47>M)	_____

Notes:

SITE
FEATURE
BURIAL NO.
RECORDER

COMPID
DATE
PROJECT

RIGHT	MAXILLA	LEFT
-------	---------	------

	PRE	OCC	BUC	LIN	INT	RT	PE	ABS	ABR	CAL	RES
DI1											
DI2											
DC											
DM1											
DM2											
I1											
I2											
C											
PM1											
PM2											
M1											
M2											
M3											

	PRE	OCC	BUC	LIN	INT	RT	PE	ABS	ABR	CAL	RES
DI1											
DI2											
DC											
DM1											
DM2											
I1											
I2											
C											
PM1											
PM2											
M1											
M2											
M3											

RIGHT	MANDIBLE	LEFT
-------	----------	------

	PRE	OCC	BUC	LIN	INT	RT	PE	ABS	ABR	CAL	RES
DI1											
DI2											
DC											
DM1											
DM2											
I1											
I2											
C											
PM1											
PM2											
M1											
M2											
M3											

	PRE	OCC	BUC	LIN	INT	RT	PE	ABS	ABR	CAL	RES
DI1											
DI2											
DC											
DM1											
DM2											
I1											
I2											
C											
PM1											
PM2											
M1											
M2											
M3											

DENTAL WEAR

Catalog no. _____ Recorder _____ Date _____

Right Left

A

B

B

A

A = Stage of wear
(numeric codes 1 to 8 based on scoring
stages by Smith 1984 [AJPA 63: 46])

B = Plane of wear
(recorded only for stages
of dental wear 4 to 8)

1. flat
2. concave
3. buccal slope
4. lingual slope
5. mesial slope
6. distal slope
7. concave-buccal
8. concave-lingual
9. concave-mesial
10. concave-distal
11. buccal-lingual
12. buccal-mesial
13. buccal-distal
14. lingual-mesial
15. lingual-distal
16. distal-mesial

STAGES OF WEAR

	MOLARS L	PREMOLARS U	MOLARS L	INCISORS & CANINES U
1				
2				
3				
4				
5				
6				
7				
8				

99 = unobservable.

CODING INSTRUCTIONS FOR INVENTORY

CRANIAL BONES

- 1 - complete
- 2 - partial
- blank - missing

LONG BONES

- 1 - complete
- 2 - proximal 1/3 missing only
- 3 - middle 1/3 missing only
- 4 - distal 1/3 missing only
- 5 - proximal 1/3 present only
- 6 - middle 1/3 present only
- 7 - distal 1/3 present only
- blank - missing

JOINT SURFACES

- 1 - complete to 50% present
- 2 - missing >50% of joint surface
- blank - missing all of the joint surface

SPECIAL CASES

Ribs 3rd-10th Under “left,” “right,” or “single” category
enter the number of bones present

Vertebrae

C3-C6 T1-T9 L1-L5

Where applicable, under “No. Complete,”
enter the number of bones complete

Blank - missing

Otherwise

- 1 - complete
- 2 - partial
- blank - missing

DENTAL INVENTORY & PATHOLOGY

STATUS

- 1 - present (tooth only)
- 2 - present (tooth in socket)
- 3 - antemortem loss (socket only)
- 4 - antemortem loss (bone resorption)
- 5 - postmortem loss (socket only)
- 6 - partially erupted
- 7 - unerupted
- 8 - congenital absence

ABSCESS

- 1 - no pathology evident
- 2 - periodontal abscess with destruction on alveolar ridge
- 3 - periapical abscess with perforation of cortex or destruction of bone
- 4 - tooth abscessed out
- 5 - antemortem loss / bone resorbed

CARIES

CROWN

- 1 - pit or slight fissural start of lesion
- 2 - lesion ranging from more than degree 1 to < 2 of surface
- 3 - destruction of 2 or more of surface, yet not complete destruction
- 4 - complete destruction of tooth surface

ROOT

- 5 - Caries involving root (neck caries) Use with any of the above

PULP EXPOSURE

- 1 - due to marked attrition
- 2 - due to caries lesion

CALCULUS

- 1 - none
- 2 - flecks
- 3 - moderate
- 4 - coalesced
- 5 - heavy
- 6 - 3 dimensional

SURFACE ABRASION

- 1 - labial
- 2 - mesial
- 3 - distal
- 4 - mesial & distal
- 5 - occlusal

SEX & AGE CODE**Code Sex**

1. Male
2. Female
3. Indeterminate
4. Possibly Male
5. Possibly Female

Code Age

01. Born - 6 months
02. 6 months - 1.5 years
03. 1.5 - 2.5
04. 2.5 - 3.5
05. 3.5 - 4.5
06. 4.5 - 5.5
07. 5.5 - 6.5
08. 6.5 - 7.5
09. 7.5 - 8.5
10. 8.5 - 9.5
11. 9.5 - 10.5
12. 10.5 - 11.5
13. 11.5 - 12.5
14. 12.5 - 13.5
15. 13.5 - 14.5
16. 14.5 - 15.5
17. 15.5 - 16.5
18. 16.5 - 17.5
19. 17.5 - 18.5
20. 18.5 - 19.9
21. 20 - 24
22. 25 - 29
23. 30 - 34
24. 35 - 39
25. 40 - 44
26. 45 - 49
27. 50 - 54
28. 55 - 59
29. 60+
96. Young adult (15-35)
97. Old adult (35+)
98. Unknown subadult
99. Unknown adult

Skeletal Pathology Coding Sheet

D. W. Owsley

BONE CELL RESPONSE

- 1) Bone Loss
- 2) Bone Formation
- 3) Bone Loss and Formation

CLASSIFICATION

- 1) Bone Loss
 - 1) Resorptive lesion (lytic)
 - 2) Bowing (rickets, disuse)
 - 3) Porosis (pinpoint to coalesced)
 - 4) Osteopenia/osteoporosis
- 2) Bone Formation
 - 1) Increased density/sclerosis (x-ray)
 - 2) Periostitis
 - 3) Osteomyelitis (medullary involvement or sinus formation)
 - 4) Neoplasm (tumor)
 - 5) Ossified cartilage
 - 6) Ossified connective tissue (ectopic bone, enthesopathy, myositis ossificans)
- 3) Bone Loss and Formation
 - 1) Bone loss and formation

SEVERITY

- 1) Mild
- 2) Moderate
- 3) Severe

REMODELING (STATE)

- 1) Active
- 2) Healed

INVOLVEMENT

- 1) Localized
- 2) Widespread

LOCATION (Long bones only)

- 1) Proximal 1/3 shaft
- 2) Middle 1/3 shaft
- 3) Distal 1/3 shaft
- 4) Distal joint
- 5) Proximal joint
- 6) Proximal tuberosity
- 7) Distal tuberosity
- 8) More than one of the above

LOCATION (other bones)

- | | |
|-----------|----------------|
| Frontal | 1) Endocranium |
| Parietal | 2) Ectocranium |
| Occipital | 3) Both |

- | | |
|-----------|--------------------|
| Manubrium | 1) Ventral surface |
| | 2) Dorsal surface |
| | 3) Both |

- | | |
|----------|------------|
| Vertebra | 1) Centrum |
| | 2) Arch |
| | 3) Both |

- | | |
|------------|-----------------------------------|
| Innominate | 1) External surface of ilium |
| | 2) Internal surface of ilium |
| | 3) Both 1 and 2 |
| | 4) Acetabulum |
| | 5) Pubic bone (dorsal pits, etc.) |
| | 6) Symphysis |
| | 7) Ischium |

- | | |
|--------|--------------------|
| Sacrum | 1) Ventral surface |
| | 2) Dorsal surface |
| | 3) Articular facet |
| | 4) Promontory |
| | 5) Both 1 and 2 |

SKULL FRACTURE

- Shape/
Characteristics
- 1) Blunt round
 - 2) Blunt ovoidal
 - 3) Edged (bladed)
 - 4) Crushing
 - 5) Projectile (entry or exit)
- Radiating Fractures
- 1) Present
 - 2) Absent
- Severity
- 1) Ectocranium (only)
 - 2) Endocranium
- Maximum diameter (mm)
Minimum diameter perpendicular to above measurement
Number (count separate blows per bone)

POSTCRANIAL FRACTURE

- 1) Perimortem (incurred at or near death)
 - 2) Periostitis/callus formation
 - 3) Osteomyelitis
 - 4) Pseudoarthrosis (incomplete/malunion)
- Severity
- 1) Incomplete
 - 2) Complete
- Remodeling (state)
- 1) No healing
 - 2) Healing
 - 3) Healed
- Location
- 1) Proximal 1/3 shaft
 - 2) Middle 1/3 shaft
 - 3) Distal 1/3 shaft
 - 4) Distal joint
 - 5) Proximal joint
 - 6) Proximal tuberosity
 - 7) Distal tuberosity
 - 8) More than one of the above

VERTEBRAL BODY FRACTURE

- 1) Compression (any body fracture - nonpathological such as from a fall)
- 2) Single endplate depression (disc) WITHOUT wedging - usually degenerative
- 3) Single endplate depression (disc) WITH wedging - usually degenerative
- 4) Wedged (congenital/idiopathic only)
- 5) Biconcave bodies (with or without wedging - reflects osteoporosis and osteomalacia)
- 6) More than one of the above

SCHMORL'S DEPRESSIONS

Number of thoracic bodies affected
 Number of lumbar bodies affected

SPINAL ANOMALIES

- 1) Spina bifida (includes cleft spine)
- 2) Spondylolysis
- 3) Both

SACRAL ANOMALIES

- 1) Spina bifida (includes cleft spine)

DEGENERATIVE JOINT DISEASE (Arthritis)

Osteophyte formation
 Porosis (pitting)
 Eburnation (polishing)

Severity 1) Mild
 2) Moderate
 3) Severe
 4) Bony ankylosis (osteophytes only)

Location 1) Surface (subchondral bone)
 (joint/facet) 2) Margin (periphery without encroachment of subchondral bone)
 3) Both

Location 1) Endplate (superior/inferior)
 (vertebral 2) Margin (periphery only)
 body) 3) Both

DIAGNOSTIC CODES

Syphilis	
Tuberculosis	
Traumatic death	1 = present
Projectile (present or was present)	
Dislocation (luxation or subluxation)	
Osteoporosis (generalized bone loss or radiographic loss also)	
Porotic hyperostosis	1 = Mild
Cribra Orbitalia	2 = Moderate
	3 = Severe

Volume II
Osteological Analyses

Mission Refugio

Appendix IIC
Individuals with Enthesophytosis

Table IIC-1. Individuals from Refugio with Enthesophytosis

Burial	Sex	Age	Bone	Side
41RF1-BP02-015	Female	35+	Patella	Left & Right
41RF1-BP04-008	Male	15-34	Tibia	Left
41RF1-BP04-016	Male	35+	Patella	Left
41RF1-BP04-018	Male	35+	Innominate	Right
41RF1-BP04-019	Male	35+	Tibia	Right
41RF1-BP05-P01R	Poss. Male	35+	Patella	Right
41RF1-BP07-038	Female	35+	Rib	Left & Right
41RF1-BP08-026	Male	15-34	Fibula	Right
			Patella	Left
41RF1-BP10-043	Male	15-34	Tibia	Right
41RF1-BP12-050	Male	35+	Calcaneus	Left & Right
			Fibula	Left
			Patella	Left & Right
			Tibia	Left
41RF1-BP16-083	Male	35+	Calcaneus	Right
			Patella	Left
41RF1-BP20-002	Poss. Male	35+	Calcaneus	Left
			Femur	Left & Right
			Innominate	Right
			Patella	Left & Right
			Radius	Left
41RF1-BP22-091	Male	35+	Tibia	Left & Right
			Calcaneus	Left & Right
41RF1-BP22-117	Female	35+	Innominate	Right
41RF1-BP22-127	Male	35+	Tibia	Left
41RF1-BP26-100	Poss. Male	15-34	Calcaneus	Left & Right
41RF1-BP26-101	Female	35+	Ulna	Left
41RF1-BP26-119	Male	15-34	Calcaneus	Left & Right
41RF1-BP26-126	Male	35+	Innominate	Left
41RF1-BP31-105	Female	35+	Femur	Left

Volume II
Osteological Analyses

Mission Refugio

Appendix IID
Individuals with Antemortem Fractures

Table IID-1. Individuals from Refugio and San Juan Capistrano with antemortem fractures

Burial	Sex	Age	Bone	Side	State	Location
41RF1-BP02-006	Female	35+	Clavicle	Left & Right	Healed	
			Maxilla	Left	Healing	
			Parietal	Right	Healed	
			Ulna	Left	Healed	Proximal Joint
41RF1-BP04-012	Male	35+	Ulna	Left	Healed	Distal 1/3 of Shaft
41RF1-BP05-017	Female	15-35	Frontal	Center	Healed	
41RF1-BP05-040A	Male	15-35	Radius	Right	Healed	Distal 1/3 of Shaft
41RF1-BP05-U01L	Male	15-35	Ulna	Left	Healed	Distal 1/3 of Shaft
41RF1-BP11-044	Male	35+	Nasal	Left & Right	Healed	
41RF1-BP12-050	Male	35+	R3-10	Left	Healed	
41RF1-BP15-048	Male	15-35	Clavicle	Left	Healed	
41RF1-BP16-083	Male	35+	Clavicle	Left	Healed	
41RF1-BP17-078	Male	15-35	R3-10	Left	Healing	
41RF1-BP17-090	Male	35+	Radius	Right	Healed	Proximal Joint
			Ulna	Right	Healed	Proximal Joint
41RF1-BP22-109	Female	15-35	Fibula	Right	Healing	Middle 1/3 of Shaft
			Tibia	Right	Healing	Middle 1/3 of Shaft
41RF1-BP22-112	Male	15-35	Humerus	Left	Healed	Distal 1/3 of Shaft and Distal Joint
			Radius	Left	Healed	Proximal Joint
			Ulna	Left	Healed	Proximal Joint
41RF1-BP22-117	Female	35+	Radius	Right	Healed	Proximal 1/3 of Shaft
			Ulna	Right	Healed	Proximal 1/3 of Shaft
41RF1-BP24-068	Female	35+	Ulna	Left	Healed	Distal 1/3 of Shaft
41RF1-BP26-101	Female	35+	Femur	Left	Healed	Proximal 1/3 of Shaft
41RF1-BP26-111	Female	35+	Femur	Right	Healing	Proximal 1/3 and Distal 1/3 of Shaft
41RF1-BP26-125	Male	15-35	Zygomatic	Right	Healed	
41RF1-BP26-126	Male	35+	Radius	Left	Healed	Proximal Joint
41RF1-BP26-H02L	Male	Adult	Humerus	Left	Healed	Middle 1/3 of Shaft
41RF1-BP26-I05R	Female	15-35	Innominate	Right	Healed	Distal 1/3 of Shaft
41RF1-BP34-106B	Male	15-35	Clavicle	Right	Healing	
41RF1-BP35-134	Male	15-35	Femur	Right	Healed	Distal Joint
41BX5-17-101	Male	35+	Frontal	Center	Healed	
			Temporal	Left	Healed	
41BX5-17-10B02	Female	35+	Parietal	Left	Healed	
41BX5-17-1703	Male	15-35	Nasal	Left	Healed	
41BX5-17-401	Male	15-35	Radius	Right	Healed	Distal 1/3 of Shaft
41BX5-17-402	Female	35+	Humerus	Left	Healed	Distal 1/3 of Shaft
			R3-10	Left	Healed	
			Clavicle	Right	Healed	
41BX5-17-803	Female	15-35	Frontal	Center	Healed	
			Parietal	Left	Healed	
41BX5-17-H10R	Female	15-35	Humerus	Right	Healed	Distal 1/3 of Shaft
41BX5-26-100	Male	35+	R3-10	Left	Healed	
41BX5-26-11C	Female	15-35	Nasal	Right	Healed	
41BX5-26-11GA	Male	35+	Humerus	Left	Healed	Middle 1/3 of Shaft
			Ulna	Left	Healed	More than 1/3 of the Bone

Table IID-1. continued...

Burial	Sex	Age	Bone	Side	State	Location
41BX5-26-11H	Male	35+	Frontal	Center	Healed	
			Parietal	Left	Healed	
			R3-10	Right	Healed	
41BX5-26-1301	Male	35+	Fibula	Left	Healed	Proximal 1/3 of Shaft
			R3-10	Left	Healed	
41BX5-26-16F	Male	15-35	Maxilla	Left	Healed	
			Nasal	Left	Healed	
41BX5-26-404	Male	15-35	Clavicle	Left	Healing	
			Frontal	Center	Healed	
41BX5-26-405	Female	35+	Frontal	Center	Healed	Distal 1/3 of Shaft
			Radius	Left	Healed	
41BX5-26-4CLAVI	Male	35+	Clavicle	Right	Healed	
41BX5-26-801	Male	35+	Temporal	Left	Healed	
41BX5-26-900	Male	15-35	Humerus	Left	Healed	Distal Joint
			Ulna	Left	Healed	Proximal Joint

**Volume II
Osteological Analyses**

Mission Refugio

**Appendix IIE
Isotopic Analysis of Human Skeletal Remains
from Mission Refugio**

Osteological Analyses

Appendix IIE

Isotopic Analysis of Human Skeletal Remains from Mission Refugio

Lynette Norr

This appendix presents the results and analysis of the stable carbon and nitrogen isotope analysis of archaeological human skeletal remains from the Refugio site, Refugio County, Texas. Stable isotope analysis is now a well established analytical technique (DeNiro 1987; Norr 1995, 2000; Schoeninger et al. 1983; van der Merwe 1982) for the reconstruction of patterns of prehistoric subsistence. This method relies on natural variation in the abundance of stable isotopes in different categories of food resources (Figure IIE-1) and has the potential to identify the degree to which a population's subsistence strategy relied upon agricultural maize and/or marine vs. terrestrial protein resources. Marine vertebrates and maize usually are isotopically distinct from most other plant and terrestrial animal resources. Because

the isotopic composition of food resources is incorporated into body tissues, the presence and relative proportions of certain food types in the diet can be identified through the analysis of bone collagen and bone apatite carbonate.

The assessment of relative proportions of dietary resources consumed by humans is dependent upon accurate and detailed knowledge of the isotopic composition of local food resources, but only a few have been analyzed for the Gulf region, and for the Colonial Period (Hutchinson and Norr 1999, Norr 2000). Recent advances in the interpretation of isotope ratio data from bone have come from laboratory experiments using animals fed isotopically-controlled diets and the subsequent analysis of body tissues (Ambrose and

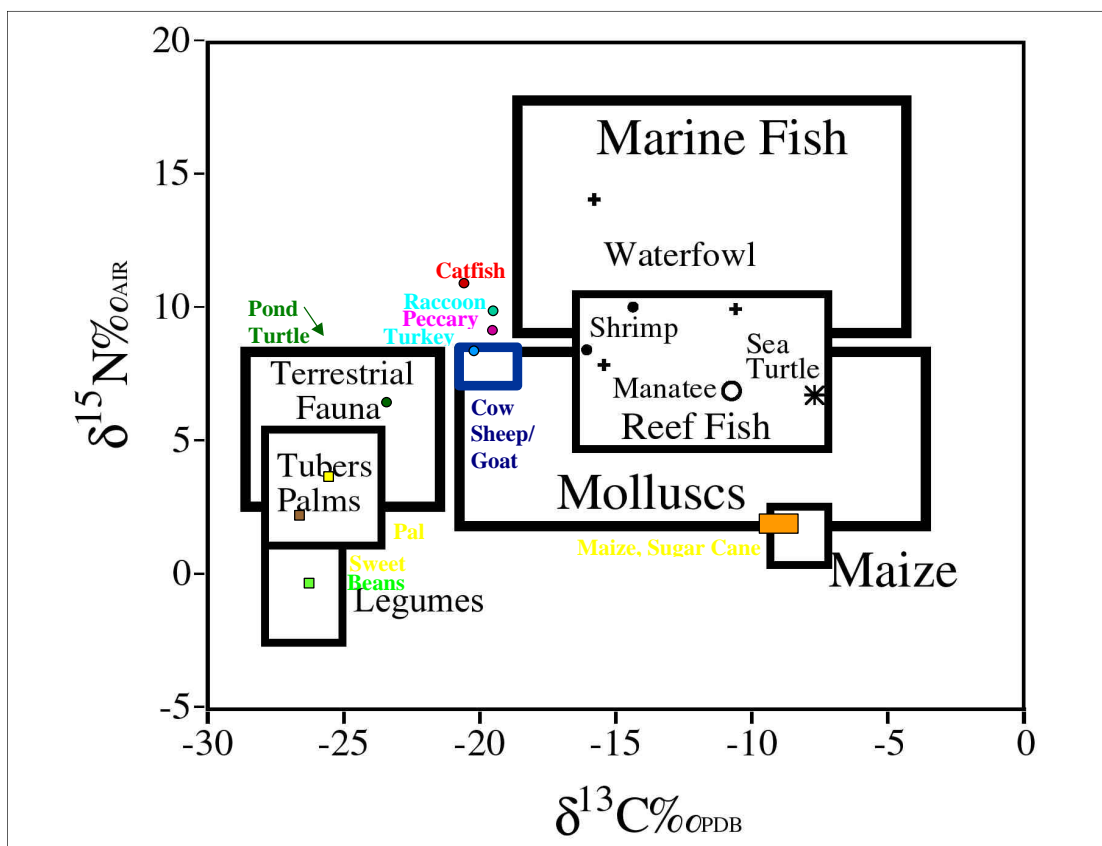


Figure IIE-1. A schematic representation of the natural variation in the isotopic composition of different categories of potential food resources found in the tropical and subtropical Americas. (Hutchinson and Norr n.d.; Norr 2000, n.d.; local resources from previously published sources are indicated in color.)

Norr 1993). Accurate interpretation of human bone isotope data will identify changes in human dietary patterns over time as well as intra-site variations in individual diet that can be correlated with age, sex, stature, social status, burial treatment, and patterns of disease.

The analysis of stable carbon ($^{13}\text{C}/^{12}\text{C}$) and nitrogen ($^{15}\text{N}/^{14}\text{N}$) isotopic ratios in organic and carbonate fractions of archaeological human bone was used to identify differences in diet and resource use in a multi-ethnic burial area from the Refugio site. Bone samples were submitted for analysis by Robert Hard of the Center for Archaeological Research, The University of Texas at San Antonio. The results reported here are delta (δ) values in parts per mil (‰), relative to known standards, which are PDB (Peedee belemnite) for carbon and AIR for nitrogen.

In the case of coastal/ estuarine/ riverine populations of the Southeastern United States, diets were likely derived from a number of isotopically varied resources, which can make paleodietary interpretations challenging. Historical and Colonial contexts also increase the number of available food resources, including domesticated animals. Three direct isotopic indicators of diet and one indirect isotopic evaluation strengthen the interpretation of bone stable carbon and stable nitrogen isotope values. Nitrogen isotopes in bone collagen are used to identify protein source: terrestrial, marine, or some combination of the two. Carbon isotopes in bone collagen were interpreted following the model that carbon in collagen is derived mostly from dietary protein, and carbon isotopes in bone apatite carbonate are derived proportionately from all carbon sources in the whole diet. The relationship between the carbon isotope values of the bone collagen and the bone apatite carbonate indicates either a monoisotopic diet or the relative isotopic compositions of the protein and carbohydrate portions of the diet (Ambrose and Norr 1993; Norr 1995).

In order to examine the dietary patterns from prehistoric and historic contexts at Refugio, 56 individuals were sampled and processed for collagen and for bone apatite during December 2000 and January 2001. Approximately 5 g of clean, dry cortical bone is the ideal bone sample. In this case, we had mostly ribs, with some cranial, metatarsal, scapulae, and pelvis, or other elements with little cortical bone, and only a few long bone fragments. Each bone sample was scraped to remove discolored surfaces and trabecular bone, and then sonicated in distilled water, rinsed, and air dried before crushing by hand in a porcelain mortar and pestle. Crushed bone was sieved to < .25 mm and .25–.50 mm size

fractions. The larger fraction was used for collagen extraction and the finer fraction was used to prepare the bone apatite.

Bone crushed and sieved to .25–.5 mm was demineralized in .2 molar HCl in a glass, fritted disk funnel fitted with a Teflon stopcock. The demineralized residue was soaked in .125 molar NaOH to remove soil humic acid contamination before solubilizing in 10^{-3} molar HCl at 95° C. Percent carbon and nitrogen by weight (%C/wt and %N/wt) in collagen was determined with a Carlo Erba elemental CHN analyzer. The carbon to nitrogen ratio (C/N) was calculated by dividing the %C/wt by the %N/wt. The resulting value was multiplied by 1.16667 to obtain an atomic C/N ratio as reported by DeNiro (1985) and Ambrose (1990). One to three mg of filtered and freeze-dried collagen was converted to CO_2 and N_2 in a Carlo Erba, and isotope ratios were determined on a VG IsoGas Prism II Series mass spectrometer.

Bone crushed and sieved to < .25 mm was prepared in 14 cc centrifuge tubes with a 50 percent Clorox solution to break down organic contents, followed by 1 molar acetic acid to remove environmental and nonstructural biological carbonates. Percent carbon and nitrogen by weight (%C/wt and %N/wt) in apatite was determined with the same Carlo Erba elemental CHN analyzer. The %N/wt indicates whether all organic matter has been removed during treatment with Clorox. Apatite was converted to CO_2 in an automated multi-prep inlet system (not a common acid bath procedure), and isotope ratios were determined on the same VG Prism Series II mass spectrometer.

Modern food resources and other local plants and animals prepared at the University of Florida for other projects were rinsed in distilled water and freeze dried before being ground in a Wiley Mill and sieved to < .25 mm (Norr 2000, Norr and Hutchinson 1998, Norr et al. n.d.).

An assessment of archaeological bone quality is necessary before dietary interpretations can be made from the isotopic values of the bone fractions. Percent yield of collagen and apatite from bone, %C and %N by weight, and C/N ratios were all used to evaluate sample quality (Ambrose 1990; DeNiro 1985; Norr 1995), and are presented in Tables IIE-1 and IIE-2 along with the isotope results from collagen and apatite.

Collagen yields from bone are best when greater than 5%, but yields as low as 1% have given adequate %C/wt and %N/wt and acceptable C/N ratios (Norr 1990, 1995), despite a three percent cutoff recommended by Ambrose (1990).

Table IIE-1. Percent yield collagen from dry bone, and percent nitrogen and carbon, C/N ratios (C/N*1.166667) and isotope delta values in bone collagen from the Refugio samples

Burial	Sex	Ethnicity	Lab #	%Yld	%N/wt	%C/wt	C/N	d ¹⁵ N	d ¹³ Cco
1	F	N Amer	TX19	3.3	8.7	24.0	3.2	11.4	-16.5
2	M?	N Amer	TX45	5.2	9.5	26.5	3.2	11.7	-8.8
6	F	Hispanic	TX21	4.3	11.9	33.0	3.2	11.9	-12.9
8	M	N Amer	TX32	4.5	12.0	32.7	3.2	12.5	-12.7
9	M	N Amer	TX38	3.3	10.1	27.6	3.2	12.0	-12.7
12	M	?	TX49	5.5	12.6	35.1	3.2	11.5	-10.0S
13	F	N Amer	TX50	3.2	10.0	27.5	3.2	10.8	-8.9
15	F	N Amer	TX16	3.2	8.9	24.4	3.2	11.1	-9.7
16	M	Hispanic	TX30	7.3	12.1	33.4	3.2	12.4	-11.8
17	F	N Amer	TX39	6.1	9.8	26.9	3.2	12.2	-13.6
18	M	N Amer	TX15	4.6	10.3	28.4	3.2	10.8	-9.5
19	M	Hispanic	TX17	2.6	8.7	24.0	3.2	12.4	-13.1
20	F	N Amer	TX13	2.8	7.9	21.5	3.2	11.0	-9.1
21	M	Hispanic	TX54	6.2	9.8	27.1	3.2	11.7	-9.8
23	M	N Amer	TX34	6.8	11.3	31.2	3.2	12.8	-12.2
26	M	?	TX7	2.2	5.6	15.7	3.3	12.1	-8.9
30	F	N Amer	TX35	6.3	12.0	33.1	3.2	10.9	-17.4
31	F	?	TX6	4.1	9.1	25.5	3.3	11.8	-9.7
34	IN	?	TX55	4.0	9.5	26.1	3.2	11.4	-8.7
36	F	N Amer	TX11	1.7	3.0	8.4	3.2	nd	-9.2
38	F	European	TX18	6.1	13.5	37.5	3.2	11.0	-8.1
39	M	?	TX36	18.0	11.8	32.6	3.2	12.4	-15.4
42	F	European	TX31	18.8	15.6	43.1	3.2	13.3	-9.9
43	M	?	TX12	3.8	10.8	29.7	3.2	11.0	-8.9
45	F	N Amer	TX23	3.9	11.2	31.0	3.2	13.0	-11.3
48	M	N Amer	TX47	7.3	11.5	31.8	3.2	13.3	-10.5
48A	M	?	TX42	16.1	13.0	35.9	3.2	11.9	-11.6
50	M	N Amer	TX24	12.5	14.1	39.0	3.2	11.9	-9.5
51	??	N Amer	TX37	12.5	11.0	30.2	3.2	9.6	-7.3
52	F	N Amer	TX4	16.1	13.4	36.9	3.2	11.0	-9.4
53	F	European	TX3	2.4	5.1	14.0	3.2	10.4	-8.5
54	M	N Amer	TX26	5.3	11.4	31.6	3.2	11.6	-9.5
56	M	N Amer	TX56	2.7	9.1	25.2	3.2	13.4	-12.9
60	M	?	TX52	5.0	10.1	28.3	3.3	11.5	-8.4
62	M	N Amer	TX33	7.7	12.4	34.3	3.2	12.3	-11.5
63	M	N Amer	TX9	2.9	7.5	20.3	3.2	12.7	-12.9
68	F	N Amer	TX28	12.8	14.0	38.9	3.2	11.6	-11.8

Table IIE-1. continued...

Burial	Sex	Ethnicity	Lab #	%Yld	%N/wt	%C/wt	C/N	d ¹⁵ N	d ¹³ Cco
69	M	N Amer	TX20	17.3	14.5	40.0	3.2	12.5	-10.4
73	Indet	N Amer	TX51	6.7	11.8	32.4	3.2	11.6	-10.2
75	F	N Amer	TX14	3.3	9.5	26.1	3.2	12.3	-15.6
78	M	N Amer	TX41	11.5	12.6	35.0	3.2	12.2	-12.9
82	M	Hispanic	TX29	6.0	10.9	29.8	3.2	10.6	-8.0
83	M	N Amer	TX53	2.4	1.7	4.5	3.1	11.6	-12.0
83A	F	N Amer	TX27	8.4	13.1	36.2	3.2	11.9	-10.3
86	F	N Amer	TX25	4.6	10.3	28.3	3.2	10.8	-9.5
87	M	Hispanic	TX8	5.4	11.2	31.0	3.2	13.2	-13.3
90	M	N Amer	TX48	5.1	11.3	31.4	3.2	15.0	-13.1
91	M	N Amer	TX40	12.7	12.0	33.1	3.2	12.6	-9.5
93	M	N Amer	TX43	5.9	10.3	28.6	3.2	12.3	-10.0
109	F	N Amer	TX22	4.1	12.4	34.3	3.2	12.2	-9.0
117	F	N Amer	TX10	5.8	12.5	34.9	3.3	11.1	-9.4
126	M	N Amer	TX2		4.8	13.1	3.2	11.5	-8.8
129	M	Hispanic	TX44	4.5	9.6	26.4	3.2	12.9	-10.0
133	nd	nd	TX5	5.3	10.9	30.0	3.2	12.7	-11.9
134	M	Hispanic	TX1		0.9	2.3	3.0	nd	-13.7
135	NA	N Amer	TX46	4.6	8.2	22.8	3.2	12.9	-11.9
Overall Mean				6.53	10.30	28.44	3.20	11.93	-10.93
+/- 1sd				4.42	2.97	8.25	0.04	0.91	2.24
Hispanic Mean								12.16	-11.58
+/- 1sd								0.86	2.07
European Mean								11.70	-8.83
+/- 1sd								1.39	0.95
N Amer Mean								11.96	-11.12
+/- 1sd								0.98	2.26
Female Mean								11.57	-10.99
+/- 1sd								0.76	2.77
Male Mean								12.21	-11.04
+/- 1sd								0.87	1.91

Table IIE-2. Percent yield apatite from dry bone and percent nitrogen (organic residue) and carbon in apatite, isotope ratios in bone carbonate and the carbon isotope carbonate-collagen difference from Refugio, Texas.

Burial	Lab #	% Apat	%N/wt	%C/wt	d ¹³ C _{ca}	? ¹³ C _{ca-co}
1	TX19	31.10	0.00	1.40	-7.60	8.90
2	TX45	37.10	0.00	1.80	-5.10	4.30
6	TX21	25.30	0.00	1.50	*	
8	TX32	36.60	0.00	2.10	-6.20	6.40
9	TX38	41.70	0.00	1.20	-3.80	6.70
12	TX49	36.40	0.00	0.80	-5.60	1.60
13	TX50		0.00	1.90	*	
15	TX16	38.80	0.10	1.30	-5.60	4.10
16	TX30	32.90	0.00	1.50	-6.80	5.00
17	TX39	41.50	0.00	1.20	-6.00	8.20
18	TX15	43.40	0.00	1.00	*	
19	TX17	35.90	0.10	1.70	-7.10	6.00
20	TX13	41.80	0.10	1.00	-4.40	4.70
21	TX54	38.70	0.10	1.00	-4.20	5.60
23	TX34	34.80	0.10	1.20	-7.00	4.90
26	TX7	40.20	0.00	1.30	-3.60	5.30
30	TX35	33.20	0.00	1.30	-7.30	6.70
31	TX6	35.80	0.10	1.20	-3.60	6.10
34	TX55	43.50	0.00	0.90	-3.40	5.30
36	TX11	45.60	0.10	0.90	-3.90	5.30
38	TX18	31.00	0.00	1.70	-3.90	4.20
39	TX36	32.60	0.10	1.70	-10.70	4.20
42	TX31	30.40	0.10	1.00	-5.90	4.00
43	TX12	44.70	0.00	0.60	-4.00	4.90
45	TX23	32.00	0.10	1.50	-5.20	6.20
48	TX47	39.00	0.00	1.00	-5.60	5.00
48A	TX42	30.40	0.10	1.00	-7.50	4.40
50	TX24	30.70	0.00	0.90	-4.80	4.70
51	TX37	29.70	0.00	1.20	-11.20	3.50
52	TX4	22.60	0.00	1.00	-4.50	4.90
53	TX3	42.10	0.00	1.30	-3.50	5.00
54	TX26	29.20	0.10	2.10	-4.00	5.50
56	TX56	35.10	0.10	1.50	-5.70	7.30
60	TX52	30.80	0.00	1.90	-3.10	5.30
62	TX33	28.90	0.00	1.20	-6.40	4.50
63	TX9	33.60	0.00	1.30	-5.90	7.00
68	TX28		0.00	1.40	-8.00	3.80

Table IIE-2. continued...

Burial	Lab #	% Apat	%N/wt	%C/wt	d ¹³ Cca	? ¹³ Cca-co
69	TX20	27.30	0.00	1.50	*	
73	TX51	32.30	0.10	2.10	-3.70	6.50
75	TX14	37.50	0.00	1.00	-7.50	8.10
78	TX41	32.90	0.00	1.00	-5.40	5.40
82	TX29	34.90	0.00	1.30	-2.30	5.70
83	TX53	50.90	0.00	0.60	-7.00	5.00
83A	TX27	32.00	0.10	1.20	-5.40	4.90
86	TX25	32.80	0.10	1.30	-4.20	5.30
87	TX8	36.00	0.00	0.90	-7.30	6.00
90	TX48	36.70	0.00	1.20	-5.60	7.40
91	TX40	36.20	0.10	1.10	-5.40	4.10
93	TX43	39.40	0.00	1.20	-7.20	4.70
109	TX22	33.90	0.00	1.50	-3.40	5.50
117	TX10	39.30	0.00	1.20	-3.30	6.00
126	TX2	44.00	0.00	1.20	-4.20	4.60
129	TX44	33.10	0.00	1.30	-5.30	4.80
133	TX5	35.20	0.10	1.20	-4.80	7.10
134	TX1	45.90	0.00	0.90	-7.70	5.90
135	TX46	39.20	0.10	1.00	-4.50	6.30
Overall Mean		35.86	0.03	1.27	-5.47	5.49
+/- 1sd		5.60	0.05	0.35	1.86	1.33
Hispanic Mean					-5.69	5.86
+/- 1sd					1.87	0.94
European Mean					-4.43	4.40
+/- 1sd					1.29	0.53
N Amer Mean					-5.49	5.69
+/- 1sd					1.62	1.35
Female Mean					-5.32	5.78
+/- 1sd					1.94	1.54
Male Mean					-5.76	5.27
+/- 1sd					1.87	1.16

The collagen from the Refugio individuals was adequately preserved in all but two cases, Burial 36 (TX11) and Burial 134 (TX1). The Refugio samples averaged $6.53\% \pm 4.42$ yield collagen from bone, with ten samples having yields over 10%; two samples remain to be calculated. The C/N ratio of

collagen (C/N_s1.166667) has been estimated from its amino acid composition to be 3.21 (Ambrose 1990, 1993; Kennedy 1988). C/N ratios of collagen with isotope ratios that reflect diet typically range from 2.9 to 3.6 (DeNiro 1985). Some of this variation reported by DeNiro is analytical, some may be

due to disintegration of collagen over time or slight contamination from soil humic acids or other carbon-rich contaminants (Kennedy 1988).

Bone apatite usually has 0.6-1.3% carbon in the form of carbonate (Ambrose 1993). Carbon in excess of that range may indicate contamination of the samples. Nitrogen in the apatite samples would indicate one of two things: either all of the protein had not been removed during the chemistry preparations, or that there was a low level of background nitrogen (atmospheric nitrogen) during the CHN analysis in the Carlo Erba. A few Refugio samples have very slightly elevated percent carbon. In none of the Refugio apatite samples do any of these issues appear to be a problem. Carbon isotope ratios are typically not determined for apatite samples in which the collagen is degraded or contaminated beyond an acceptable C/N level. This is because apatite carbonate carbon is more likely to have experienced diagenesis when the collagen is degraded, and also because of limited interpretive utility without the collagen values (Norr 1995). Only the two samples mentioned above have reduced collagen levels, but both have acceptable C/N ratios. Therefore, apatite values were obtained from all samples submitted. Due to a mass-spec run error, four apatite samples remain to be analyzed.

Internal laboratory and international standards for the stable isotopes of carbon and nitrogen were run along with the archaeological human bone samples and the modern food samples. These standards are run for the assessment of intra-lab precision and to ensure inter-lab comparability. The results of our standard runs are presented in Table IIE-3.

Bone stable isotopes reflect the natural variation in carbon and nitrogen isotope composition of the foods eaten. Because of this variation in food resources, and because of how carbon isotopes of different food components (e.g., proteins vs. carbohydrates) are incorporated into bone tissues (Ambrose and Norr 1993; Norr 1995), bone stable isotopes can provide several different kinds of dietary information for each individual. $\delta^{15}\text{N}$ in bone collagen

generally distinguishes between terrestrial and marine protein, although both environments can be highly variable at a global scale. $\delta^{13}\text{C}$ in collagen predominately reflects dietary protein sources, and can distinguish between terrestrial and marine dietary protein, or between proteins in C_3 or C_4 photosynthetic pathway food chains, in many situations. $\delta^{13}\text{C}$ in apatite carbonate reflects the isotopic composition of the whole diet, both carbohydrates and proteins, in the proportions they are consumed (Ambrose and Norr 1993; Norr 1995).

The distribution of carbon isotopes in dietary protein and carbohydrates is particularly important for paleodietary reconstructions of omnivores when the protein and carbohydrate portions of the diet had dramatically different stable carbon isotope compositions (Ambrose and Norr 1993; Klepinger and Mintel 1986; Norr 1995). The difference between $\delta^{13}\text{C}$ apatite carbonate and collagen ($\Delta^{13}\text{C}_{\text{ca-co}}$) in an individual indicates the isotopic relationship of dietary protein compared to other dietary components in that person's diet. The regularities, or patterns, observed in these isotope data in controlled diet studies (Ambrose and Norr 1993) can be applied to paleodietary reconstruction in the coastal areas of the Americas (Norr 1995). If the difference between the $\delta^{13}\text{C}$ of the apatite carbonate and the collagen is small, the dietary protein is isotopically enriched in ^{13}C compared to the energy portion of the diet (e.g., marine protein and C_3 energy). If this difference is large, the dietary protein is depleted in ^{13}C compared to the energy portion of the diet (e.g., terrestrial browser or freshwater fish protein and C_4 maize/sugar cane/CAM energy). If the difference is intermediate between those two extremes, then the overall isotopic values for the proteins and carbohydrates in the diet are similar, and the diet could be all C_3 -like (relatively depleted in ^{13}C), all C_4 -like (relatively enriched in ^{13}C), or a mixture of C_3 and C_4 carbohydrates with a mixture of terrestrial and marine protein.

The results of the isotopic analyses of the Refugio samples have been converted to the isotopic composition of the diet in Table IIE-4. That same table also indicates the estimated

Table IIE-3. Number analyzed, means, and standard deviations (per mil) of internal and international standards run with the archaeological and modern samples reported here

Thiourea $\delta^{13}\text{C}$ org	NBS-22 $\delta^{13}\text{C}$ org	Thiourea $\delta^{15}\text{N}$	Peptone $\delta^{15}\text{N}$	NBS-19 $\delta^{13}\text{C}$ inorg	CM-UF $\delta^{13}\text{C}$ inorg	BYM $\delta^{13}\text{C}$ inorg
N = 35	N = 80	N = 32	N = 70	N = 22	N = 8	N = 22
-23.88	-29.75	-0.73	6.99	1.93	2.15	-2.27
± 0.11	± 0.11	± 0.17	± 0.13	± 0.07	± 0.08	= 0.08

age and sex data provided with the isotope samples. Historic domestic animal bone samples from this project were not available to include in these analyses. In lieu of food sample isotope ratios from Refugio, published data from that and nearby regions are used as likely values of local domestic animals and other animals and plants.

When reviewing the data in the tables and the graph, remember that collagen nitrogen data always reflect dietary protein, and the collagen carbon data tend to reflect the carbon isotope composition of the dietary protein, but is a mixture of carbon sources that also includes some dietary carbohydrate and fats sources. The bone apatite carbonate data indicate carbon isotope ratios derived from whole diet, and were used to calculate the $\delta^{13}\text{C}$ of the diet. Those data, combined with close examination of the $\Delta^{13}\text{C}_{\text{ca-co}}$ for each individual, indicate patterns of food resources consumption.

The isotopic composition of human diet was estimated by subtracting 2.5 ‰ from the bone collagen stable nitrogen value, and by subtracting 9.5 ‰ from the bone apatite carbonate stable carbon value, since the carbonate represents whole diet far more accurately than does collagen (Ambrose and Norr 1993, Norr 1995). Archaeological animal bone samples were converted to edible portions by adding 1.7 ‰ to the collagen stable nitrogen value, and by subtracting 3.7 ‰ from the collagen stable carbon value (Keegan and DeNiro 1988; Norr 1990, 1995, 2000). Modern samples should be adjusted by +1.5 for post-industrial enrichment of ^{12}C .

Conclusions

We can address two questions here. First, what these people were eating, and second, whether there is subpopulation variation among ethnic/cultural groups, males and females, or by age. Bone isotope results and the dietary interpretations are consistent with the isotopic composition of the available food resources and mixed diets. Given the few local dietary food resources analyzed, I have not plotted the human dietary reconstructions with reference to the edible portions of the food resources. This would be a fruitful future exercise. Overall, we can say by comparing the results in Table IIE-4 with food resources in Figure IIE-1, that the average dietary values of $9.43 \pm .91$ ‰ and 14.97 ± 1.86 ‰ for nitrogen and carbon respectively correspond very closely to the values of local raccoon, peccary, turkey, cow, and sheep/goat in nitrogen, but not for carbon isotopes. The carbon isotopes indicate a food source more enriched in ^{13}C than those animals, which would suggest maize, sugar

cane, and CAM plants in the diet. However, the intermediate $\Delta^{13}\text{C}_{\text{ca-co}}$ values shown in Figure IIE-2 suggest that the protein and carbohydrate sources had similar average $\delta^{13}\text{C}$ values. It is easy to account for C_3 plants, such as beans, tree fruits and nuts, palms, and roots and tubers in the diet, but to date no protein sources have been analyzed that resulted in carbon isotope ratios enriched in ^{13}C . The human isotope data indicate that we are missing at least one dietary protein resource that has not been included in this study. I suggest that additional aquatic protein sources be analyzed for their isotopic composition to help identify a specific class of protein-rich food resources enriched in ^{13}C and consumed at Refugio. The analysis of the grazers from Refugio over the summer will also provide additional information that may help solve this question.

Figures IIE-2, IIE-3, and IIE-4 and Tables IIE-1 and IIE-2 indicate that the average European diet is enriched slightly in ^{13}C relative to all other average diets, while $\delta^{15}\text{N}$ values are relatively similar in all subgroups. A larger sample of European individuals might change this distribution, however. Generally, there is very little difference among the ethnic/cultural subgroups. The same is true for males and females, and for ages. The few young children are not higher than average in $\delta^{15}\text{N}$, which would be expected due to a trophic level increase while nursing.

The author wishes to gratefully acknowledge the assistance of Tanya Peres, Erin Kennedy, Rebecca Kiracofe, Christopher King, and Audry Hull for their help in the preparation of bone samples, and Dr. Jason Curtis of the Department of Geological Sciences for isotopic determinations on an extremely tight time schedule.

Table IIE-4. Conversion of the bone collagen $\delta^{15}\text{N}$ and carbonate $\delta^{13}\text{C}$ values to the isotopic values of the diet, with age and sex of the individuals as provided with the bone samples.

Burial	Lab #	$\delta^{15}\text{N}$ diet	$\delta^{13}\text{C}$ diet	Age	Sex
1	TX19	8.90	-17.10	20-24	F
2	TX45	9.20	-14.00	60+	M?
6	TX21	9.40	-14.50	35-39	F
8	TX32	10.00	-15.80	22-26	M
9	TX38	9.50	-15.50	25-29	M
12	TX49	9.00	-17.90	50+	M
13	TX50	8.30		17-20	F
15	TX16	8.60	-15.10	60+	F
16	TX30	9.90	-16.30	50-60	M
17	TX39	9.70	-14.90	20-24	F
18	TX15	8.30	-12.00	40-49	M
19	TX17	9.90	-16.60	35-44	M
20	TX13	8.50	-13.90	25-34	F
21	TX54	9.20	-13.70	45-54	M
23	TX34	10.30	-16.80	25-34	M
26	TX7	9.60	-13.10	25-35	M
30	TX35	8.40	-20.20	14-16	F
31	TX6	9.30	-13.10	40-49	F
34	TX55	8.90	-12.90	9.0-12.0	Indet.
36	TX11	nd	-13.40	30-39	F
38	TX18	8.50	-13.40	50+	F
39	TX36	9.90	-20.70	20-24	M
42	TX31	10.80	-15.40	40-49	F
43	TX12	8.50	-13.50	25-35	M
45	TX23	10.50	-14.70	18-24	F
48	TX47	10.80	-15.10	30-34	M
48A	TX42	9.40	-16.70	9.5-10.5	M
50	TX24	9.40	-14.30	40-44	M
51	TX37	7.10	-13.30	2.5-3.5	Indet.
52	TX4	8.40	-14.00	19-22	F
53	TX3	8.30	-13.00	16-18	F
54	TX26	9.10	-13.50	25-35	M
56	TX56	10.90	-15.20	30-34	M
60	TX52	9.00	-12.60	25-34	M
62	TX33	9.80	-16.50	30-45	M
63	TX9	10.20	-15.40	23-30	M
68	TX28	9.10	-17.50	35-44	F
69	TX20	10.00	-15.60	35-40	M

Table IIE-4. continued...

Burial	Lab #	d ¹⁵ N diet	d ¹³ C diet	Age	Sex
73	TX51	9.10	-13.20	2.5-3.5	Indet.
75	TX14	9.70	-17.00	20-29	F
78	TX41	9.70	-17.00	30-34	M
82	TX29	8.10	-11.80	34-39	M
83	TX53	9.10	-16.50	30-39	M
83A	TX27	9.40	-14.90	18-22	F
86	TX25	8.30	-13.70	30-39	F
87	TX8	10.70	-16.80	27-35	M
90	TX48	12.50	-15.10	35-45	M
91	TX40	10.10	-14.90	40-50	M
93	TX43	9.80	-14.80	30-40	M
109	TX22	9.70	-12.90	30-34	F
117	TX10	8.60	-12.80	60+	F
126	TX2	9.00	-13.70	45-60	M
129	TX44	10.40	-14.60	14-17	M
133	TX5	10.20	-14.30	nd	nd
134	TX1	nd	-17.20	30-40	M
135	TX46	10.40	-15.10	nd	Indet.
Overall Mean		9.43	-14.97		
+/- 1sd		0.91	1.86		
Female Mean		9.21	-15.09		
+/- 1sd		0.61	2.05		
Male Mean		9.57	-14.80		
+/- 1sd		1.04	1.53		

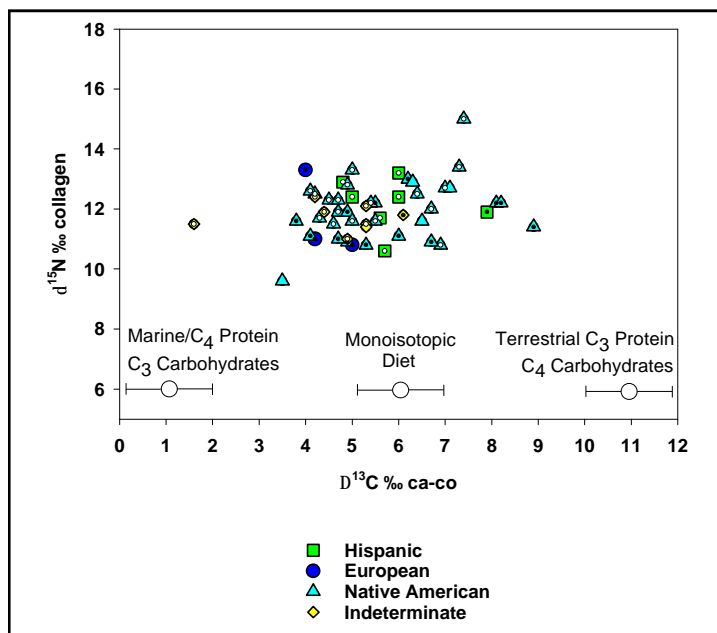


Figure IIE-2. Plot of the difference between bone collagen and bone apatite carbonate isotope data compared to that of known diets, showing assigned ethnicity. Males indicated by superimposed open circles (white), Females indicated by solid circles (black).

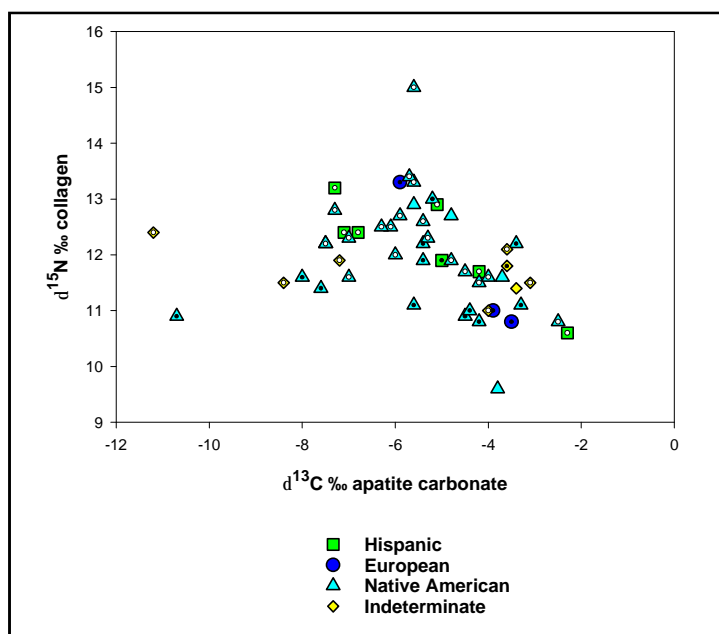


Figure IIE-3. Plot of bone apatite carbonate isotope data showing assigned ethnicity. Males indicated by superimposed open circles (white), females indicated by solid circles (black).

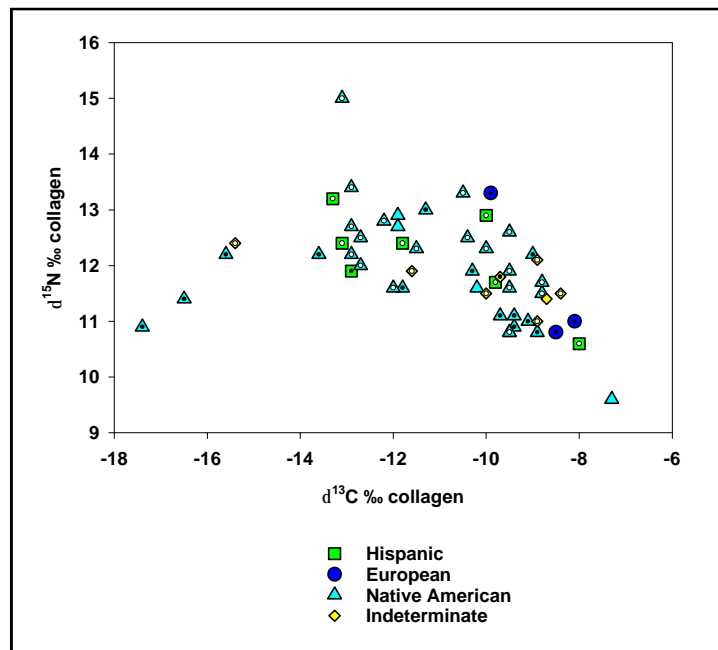


Figure IIE-4. Plot of bone collagen isotope data showing assigned ethnicity. Males indicated by open circles, females indicated by solid circles.

References Cited

Ambrose, S. H.

- 1990 Preparation and Characterization of Bone and Tooth Collagen for Isotopic Analysis. *Journal of Archaeological Science* 17:431-451.
- 1993 Isotopic Analysis: Methodological and Interpretive Considerations. In *Investigations of Ancient Human Tissues: Chemical Analysis in Anthropology*, edited by M. K. Sandford, pp. 59-130. Gordon and Breach, Scientific Publishers, New York.

Ambrose, S. H., and L. Norr

- 1993 Experimental Evidence for the Relationship of the Carbon Isotope Ratios of Whole Diet and Dietary Protein to Those of Bone Collagen and Carbonate. In *Prehistoric Human Bone: Archaeology at the Molecular Level*, edited by J. Lambert and G. Grupe, pp. 1-37. Springer-Verlag, Berlin.

DeNiro, M. J.

- 1985 Postmortem Preservation and Alteration of In Vivo Bone Collagen Isotope Ratios in Relation to Paleodietary Reconstruction. *Nature* 317:806-809.
- 1987 Stable Isotopy and Archaeology. *American Scientist* 75:182-191.

Hutchinson, D. L., and L. Norr

- 1994 Late Prehistoric and Early Historic Diet in Gulf Coast Florida. In *In the Wake of Contact: Biological Responses to Conquest*, edited by C. S. Larsen and G. Milner, pp. 9-20. Wiley-Liss, New York.
- 1999 Maize, Midden, and Mollusc. Interpreting Subadult Diet and Pathology in Late Woodland Coastal North Carolina. Paper Presented at the 1999 Annual Meeting of the American Association of Physical Anthropologists, Columbus, Ohio.
- n.d. Nutrition and Health on the Eve of European Contact in Late Prehistoric Central Gulf Coast Florida. Ms under review.

Hutchinson, D. L., C. S. Larsen, M. J. Schoeninger, and L. Norr

- 1998 Regional Variation in the Pattern of Maize Adoption and Use in Florida and Georgia. *American Antiquity* 63:397-416.

Keegan, W., and M. J. DeNiro

- 1988 Stable Carbon- and Nitrogen-Isotope Ratios of Bone Collagen Used to Study Coral-Reef and Terrestrial Components of Prehistoric Bahamian Diet. *American Antiquity* 53:320-336.

Kennedy, B. V. E.

- 1988 Variation in $\delta^{13}\text{C}$ Values of Post-Medieval Europeans. Ph.D. dissertation. Department of Archaeology, University of Calgary.

Klepinger, L. L., and R. Mintel

- 1986 Metabolic Considerations in Reconstructing Past Diet from Stable Carbon Isotope Ratios of Bone Collagen. In *Proceedings of the 24th Archaeometry Symposium*, edited by J. S. Olin and M. J. Blackman, pp. 43-48. Smithsonian Institution Press, Washington DC.

Norr, L.

- 1990 *Nutritional Consequences of Prehistoric Subsistence Strategies in Lower Central America*. Doctoral dissertation submitted to the Department of Anthropology, University of Illinois at Urbana-Champaign.
- 1995 Interpreting Dietary Maize from Bone Stable Isotopes in the New World Tropics: The State of the Art. In *Archaeology in the American Tropics: Current Analytical Methods and Applications*, edited by P. W. Stahl, pp. 198-223, volume in honor of Donald W. Lathrap. Cambridge University Press, Cambridge.
- 2000 Coastal Estuarine Biocultural Adaptation: Stable Isotope Analysis and Nutritional Inference. Technical Report Submitted to Grants and Contracts, East Carolina University.
- n.d. Bone Isotopic Analysis and Prehistoric Diet at the Tutu Site, St. Thomas, US Virgin Islands, in *Human Adaptations at the Tutu Archaeological Village Site: A Multidisciplinary Case Study*, edited by E. Righter. Interpreting Remains of the Past series, M. K. Sandford, series editor, Gordon and Breach Science Publishers SA. under review 1998.

Norr, L., and D. L. Hutchinson

- 1998 *Reconstructing Prehistoric Subsistence in South Florida*. Paper presented at the annual meeting of the Florida Anthropological Society, Gainesville, FL

Norr, L., D. L. Hutchinson, W. H. Marquardt, K. J. Walker, and L. A. Newsom

- n.d. Calusa Subsistence in South Florida. Ms. under review.

Schoeninger, M. J., M. J. DeNiro, and H. Tauber

- 1983 Stable Nitrogen Isotope Ratios of Bone Collagen Reflect Marine and Terrestrial Components of Prehistoric Human Diet. *Science* 220:1381-1383.

van der Merwe, N. J.

- 1982 Carbon Isotopes, Photosynthesis, and Archaeology. *American Scientist* 70:596-606.

The following information is provided in accordance with the General Rules of Practice and Procedure, Chapter 41.11 (Investigative Reports), Texas Antiquities Committee:

1. Type of investigation: Mitigation, data recovery, exhumation, analysis, and interpretation
2. Project name: Refugio Burials II
3. County: Refugio
4. Principal investigators: Raymond P. Mauldin and Cynthia L. Tennis
5. Name and location of sponsoring agency: Texas Department of Transportation, 125 East 11th Street, Austin, TX 78701-2483
6. Texas Antiquities Permit No.: 2025
7. Published by the Center for Archaeological Research, The University of Texas at San Antonio, 6900 N. Loop 1604 W., San Antonio, Texas 78249-0658, 2002

A list of publications offered by the Center for Archaeological Research is available. Call (210) 458-4378; write to the Center for Archaeological Research, The University of Texas at San Antonio, 6900 N. Loop 1604 W., San Antonio, Texas 78249-0658; e-mail to car@lonestar.utsa.edu; or visit CAR's web site at <http://car.utsa.edu>.